

ANATOMY REVISION 1

----- Active space -----

General Embryology

00:00:27

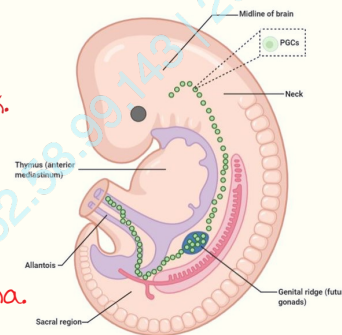
Pre embryonic period : 0-2 weeks.

Embryonic period : 2-8 weeks.

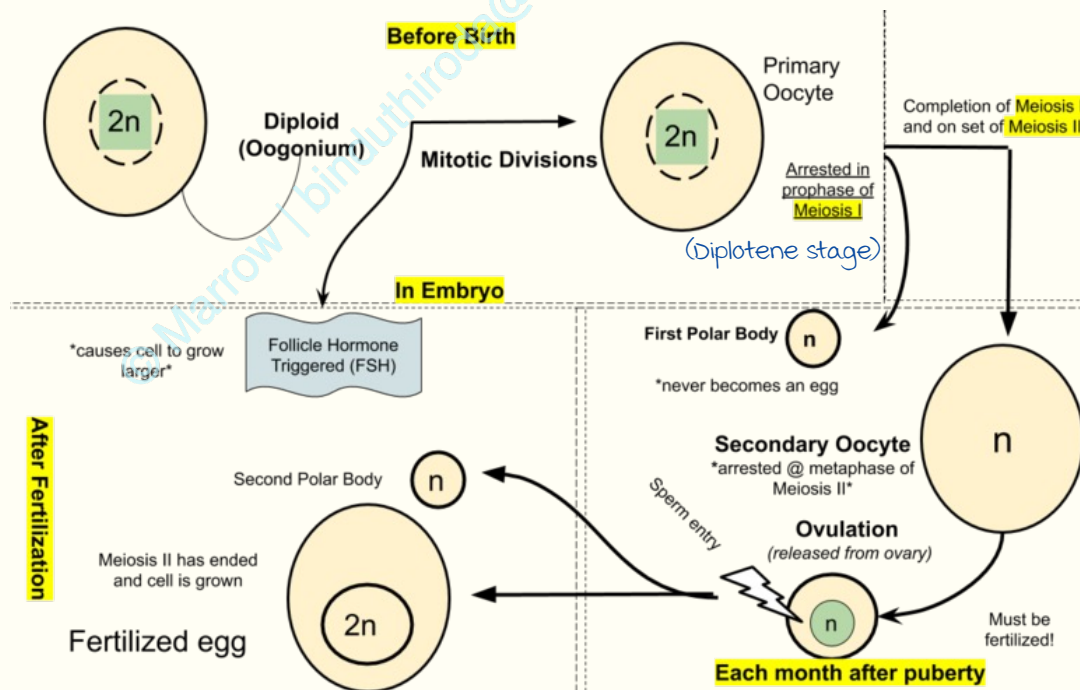
Fetal period : 9 weeks - Till birth.

Primordial Germ Cell :

- Pluripotent cell.
- Produced by epiblast : 2nd week.
- Migrate to endodermal wall of yolk sac : 4th week.
- Reach gonads : 5th week.
- Abnormal migration of PGC results in **teratoma**.
 - Neck : **Craniopharyngeal teratoma**.
 - Sacrum and coccyx : **Sacro coccygeal teratoma**.



Oogenesis :



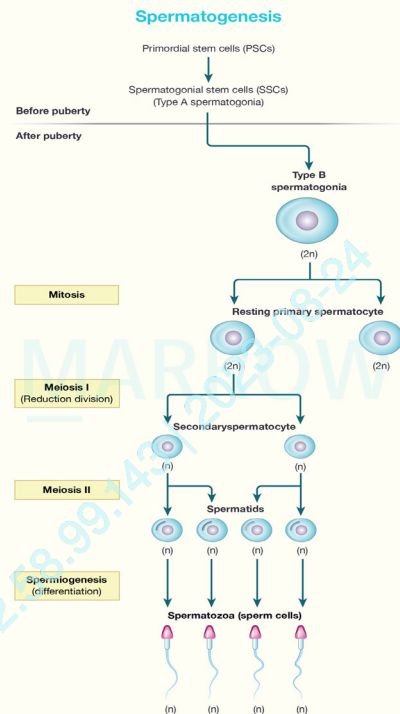
Graafian follicle after ovulation : **Corpus luteum**.

Degenerated corpus luteum : **Corpus albicans**.

----- Active space -----

Spermatogenesis :

- Spermatogenesis completed in 74 days > 64 days > 60 days.
- meiosis occurs in seminiferous tubule.
- maturation of sperms occurs in : epididymis.
- Capacitation of sperms : 6 ~ 8 hours, in female genital tract.



Fertilisation :

LH surge : 36 hours before ovulation.

LH peak : 12 hours before ovulation > at ovulation.

Sperms viable for 48 hours.

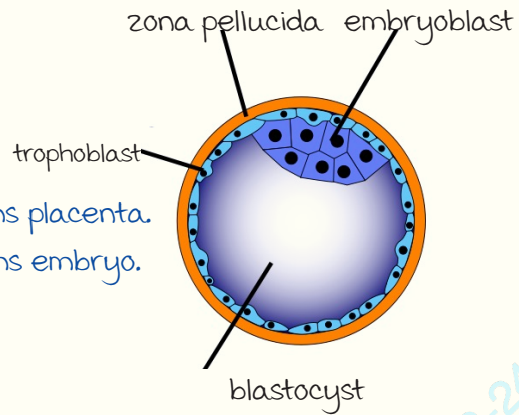
most fertile period : 2 days before ovulation to one day after ovulation.

First week of development

00:13:00

- Zygote : 12-24 hours of ovulation.
- 2 cell : 24 hours after fertilisation.
- 8-16 cell : 3rd day.
- morula : 16 cell stage > 8 cell stage.
- Advance morula (32 cell stage) : 4th day.
- Enters uterine cavity : 4th - 5th day.
- Blastocyst : 4-5 days.
- Zona pellucida :
 - a. Prevents implantation.
 - b. Prevents polyspermy.
 - c. Disappears : 5th day.

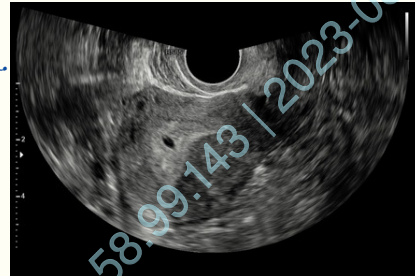
- Implantation begins at 6-7th day.
- Completes by 10-11th day.
- Bleeding at the time of implantation : Hartman's sign.
- Outer cell mass : Trophoblast → Forms placenta.
- Inner cell mass : Embryoblast → Forms embryo.



----- Active space -----

Intra decidual sign :

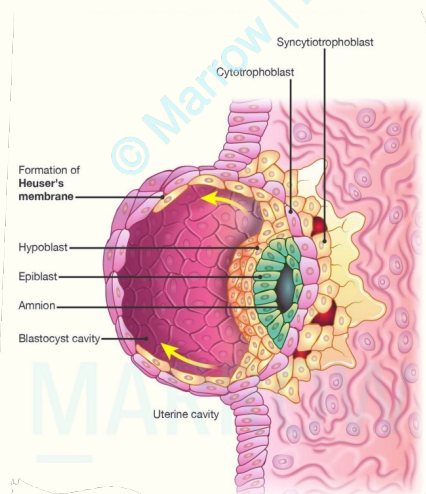
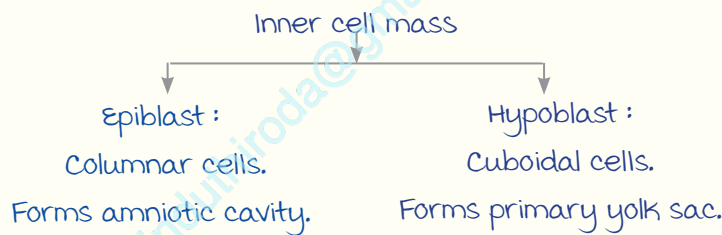
Blastocyst implanted in the deep layer of decidua.
 First fetal part to appreciate in USG :
 Gestational Sac.



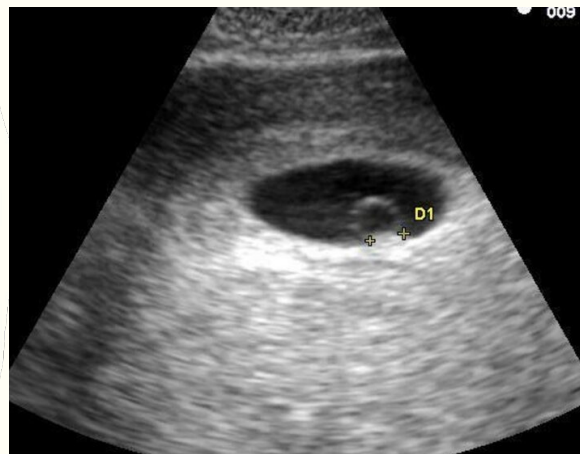USG: Intradecidual sign

Second week of development

00:18:51



Heuser's membrane :
 Exocoelomic membrane derived from hypoblast; flat cells.



Double bleb sign :
 Two bubbles formed by amniotic cavity and primary yolk sac

----- Active space -----

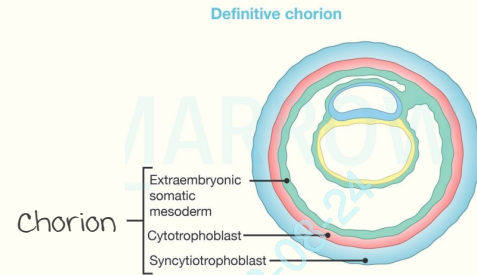
Outer cell mass :

Cytotrophoblast : well defined cell wall.

Syncytiotrophoblast : No defined cell wall (Hormone factory of placenta).

Chorion :

- Chorion : Extraembryonic somatic mesoderm + Cytotrophoblast + Syncytiotrophoblast.
- Extra embryonic mesoderm derived from primary yolk sac > hypoblast > epiblast.



Third week of development

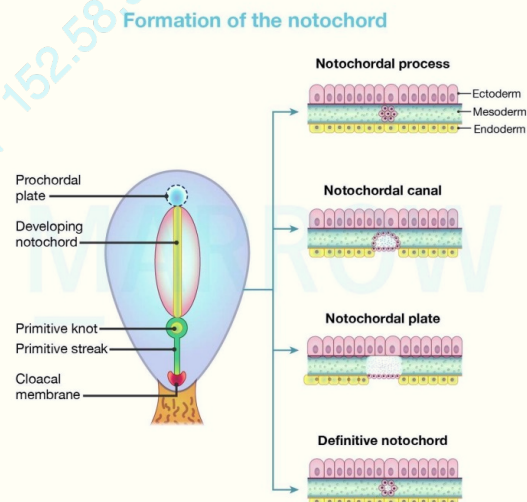
00:26:32

Important events in third week :

- Gastrulation.
- Neurulation.

Prochordal plate :

- Columnar hypoblast cells.
- Forms oropharyngeal membrane.
- Ruptures and forms oral cavity.
- Forms head end.

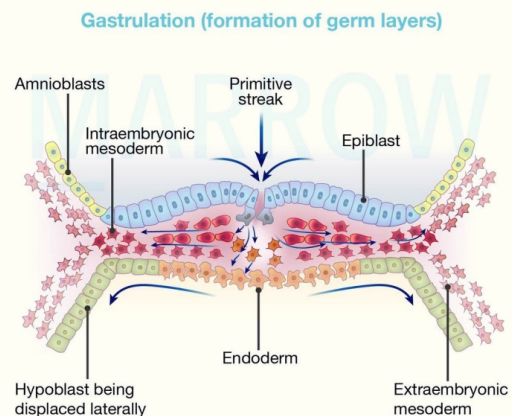


Primitive streak :

- Epiblast proliferate & forms primitive streak on 14-15th day.
- Forms tail end.
- Formation of primitive streak indicates beginning of gastrulation.

Gastrulation :

- Endoderm (1st formed) → mesoderm → Ectoderm (last formed).
- All 3 layers are derived from epiblast.

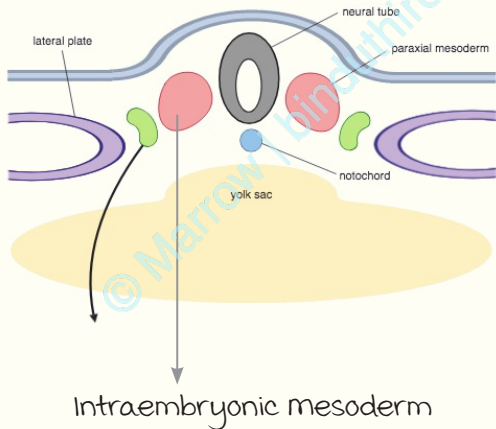
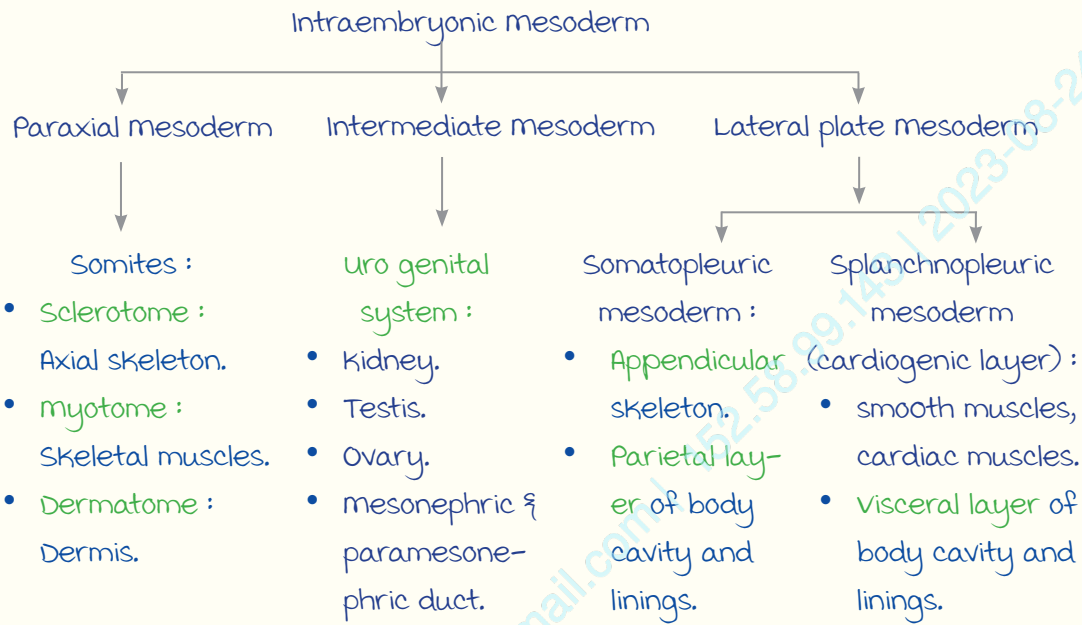


Notochord :

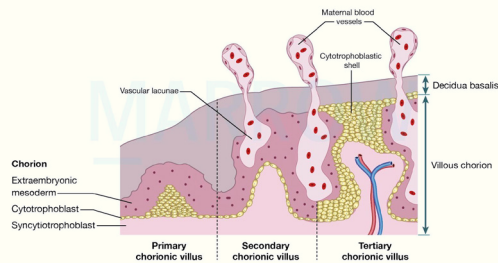
- midline mesoderm from primitive streak.
- Remnants : Nucleus pulposus > Apical ligament of dens.
- If it persists : forms chordoma.

----- Active space -----

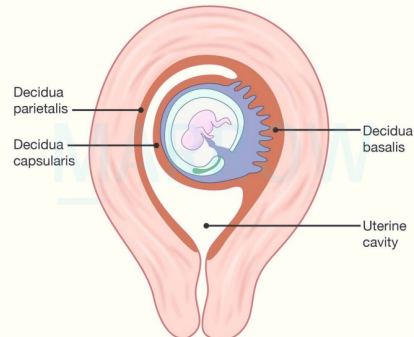
mesoderm :



Types of chorionic villi



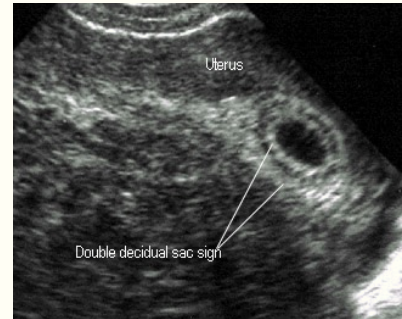
Parts of decidua



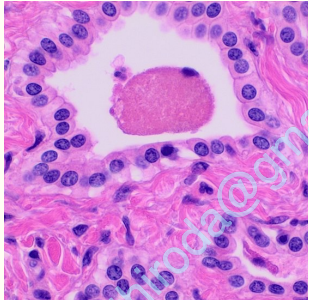
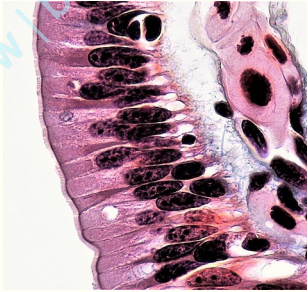
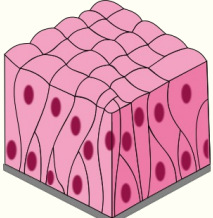
----- Active space -----

Double decidual sac sign :

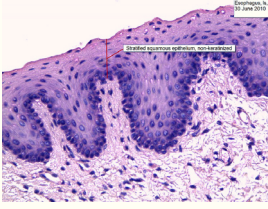

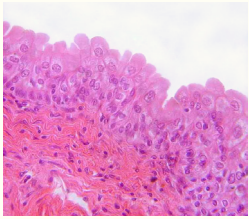
- Inner ring : Decidua capsularis.
- Outer ring : Decidua parietalis.

**Histology**

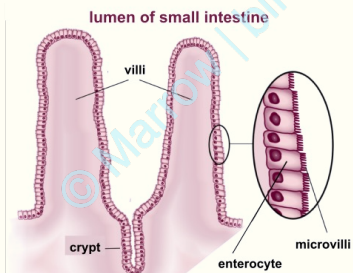
00:38:19

Epithelium	Characteristics	Examples
Simple epithelium		
Simple squamous	Breadth > length. Flat nucleus.	Blood vessels. Body cavities. Bowmans capsule. Alveoli.
Simple cuboidal 	Length = breadth. Round nucleus.	Thyroid follicles. Germinal epithelium of ovary. Tubules of kidney.
Simple columnar 	Length > breadth. Elongated nucleus.	Stomach. Large intestine. uterus.
Pseudostratified columnar 	Nuclei arranged at different levels.	Trachea. bronchus.

----- Active space -----

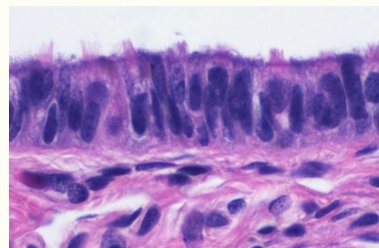
Epithelium	Characteristics	Examples
Stratified epithelium		
Stratified squamous 	many layers. Apical layer is squamous.	Skin - Keratinised. Tongue. Tonsil. Esophagus. Cornea. <div style="display: inline-block; vertical-align: middle; margin-left: 10px;"> } Non Keratinised </div>
Stratified cuboidal 		Ducts of exocrine glands and sweat glands.
Stratified columnar		membranous urethra . Penile urethra.
Transitional epithelium (urothelium) 	Apical layer cells are umbrella shaped.	ureter. Bladder. Prostatic urethra.

modifications :



microvilli :

- Increases surface area.
 Simple columnar epithelium with microvilli :
- Small intestine.
 - Gall bladder.



Cilia : Structure for motility

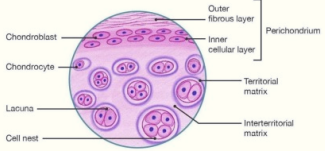
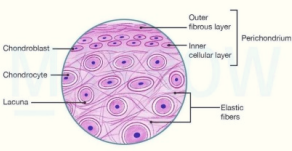
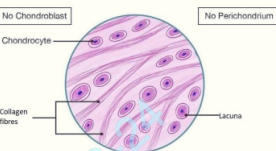
Simple ciliated columnar epithelium :

- Eustachian tube.
- middle ear.
- Fallopian tube.
- ventricles of brain.
- Trachea & bronchus : pseudostratified ciliated columnar epithelium.

----- Active space -----

Cartilage

00:46:56

Characteristic	Hyaline cartilage	Elastic cartilage	Fibrocartilage
			
Chondrocytes	In groups	In groups	In rows
matrix	<ul style="list-style-type: none"> Glossy. Type II collagen fibres present. 	<ul style="list-style-type: none"> Elastin fibres & Type II collagen fibres present. Elastin : Short, single, non wavy fibres . Does not calcify. 	<ul style="list-style-type: none"> Type I collagen fibres present : long wavy bundles.
Perichondrium	Present	Present	Absent
Examples	<ul style="list-style-type: none"> Articular cartilage. Costal cartilage. Embryonic cartilage. Epiphyseal cartilage. Respiratory cartilage. 	<ul style="list-style-type: none"> Epiglottis. Ear lobe. Eustachian tube. 	<ul style="list-style-type: none"> Meniscus. Articular disc. Glennoidal labrum. Intervertebral disc.

ANATOMY REVISION 2

----- Active space -----

Neuron

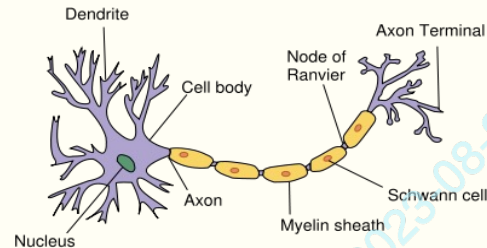
00:00:32

Collection of cell bodies in :

- CNS : Nucleus
- PNS : Ganglion

Collection of axons in :

- CNS : Tract - white matter
- PNS : Nerve



Cell	Function	Origin
Astrocyte	Blood brain barrier	Neuro ectoderm
microglia	Phagocytosis	mesodermal
Oligodendrocyte	myelin sheath - CNS	Neuro ectoderm
Schwann cell	myelin sheath - PNS	Neural crest cell
Ependymal cells	Lines ventricles	Neuro ectoderm

Development Of Neural Tube/Neurulation

00:03:27

Occurs in the 3rd week.

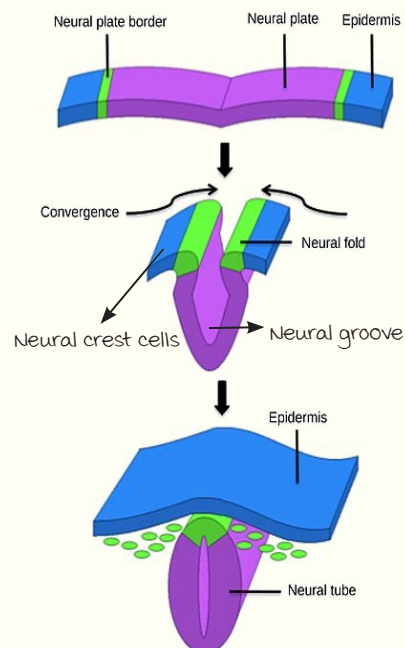
Notochord : Gives signal to ectoderm

Ectoderm forms neural plate (Neuroectoderm)

Neural plate invaginates → Neural groove
(Due to signal from notochord)

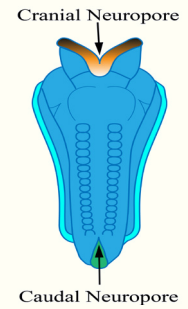
Neural crest cells are formed at the junction of
neural plate and surface ectoderm

Neural groove invaginates → Neural Tube



----- Active space -----

- Cranial neuropore closes by 25th day.
- Cranial neuropore fails to close : **Anencephaly**.
- Caudal neuropore closes by 27/28th day.
- Caudal neuropore fails to close : **Spina bifida anomalies**.
- Neural tube defects occur due to deficiency of **folic acid**.



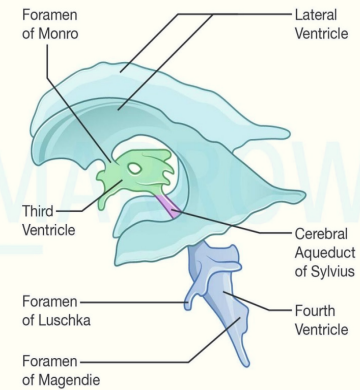
CSF And Ventricles

00:06:24

Choroid plexus :

- Actively secretes CSF.
- Choroid plexus of lateral & IIIrd ventricle : From **anterior and posterior choroidal artery**.
- IVth ventricle : From **PICA > AICA**.

Ventricle	Location
Lateral ventricles	Telencephalon
Third ventricle	Diencephalon
Cerebral aqueduct of Sylvius	mid-brain
Fourth ventricle	Pons, medulla & Cerebellum



Flow of CSF : Lateral ventricle → Foramen of monro → Third ventricle → Cerebral aqueduct of Sylvius → Fourth ventricle → Foramen of magendie (median) & Foramen of Luschka (Lateral) → Subarachnoid space → Arachnoid villi → Dural venous sinus (Superior sagittal sinus).

Applied Anatomy :

m/c cause of congenital hydrocephalus : **Congenital aqueductal stenosis**.

Dandy Walker Syndrome :

- Atresia of foramen of magendie & foramen of Luschka.
- Occurs d/t **posterior cranial fossa cyst** leading to dilated fourth ventricle.

Dura mater :

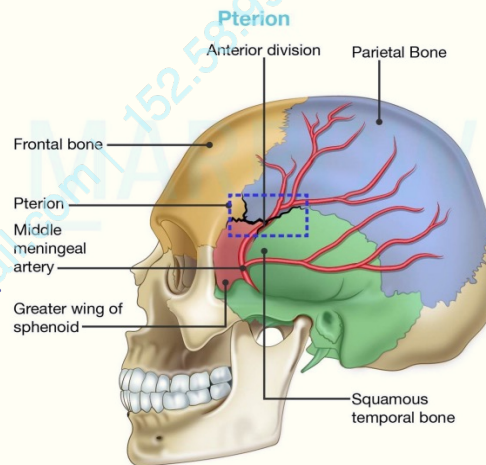
2 layers → Endosteal layer & meningeal layer.
Between the two layers is Dural venous sinus.

----- Active space -----

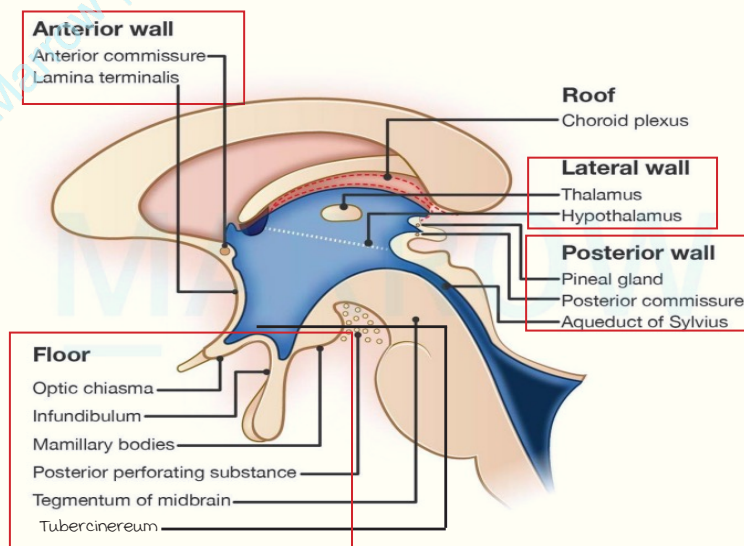
Space	Content	Applied anatomy
Subarachnoid space	CSF	CSF through arachnoid granulations drain into dural venous sinus
Subdural space	Bridging veins	Injury leading to subdural hematoma NCCT : 'C'/crescent shaped
Epidural space	middle meningeal artery	Injury leading to epidural hematoma. NCCT : Lens/biconvex shaped

Pterion :

meeting point of 4 bones → Frontal, parietal, temporal & sphenoid.
Anterior/frontal division of middle meningeal artery present beneath pterion.



Relations of third ventricle :



----- Active space -----

Lamina terminalis :

- Formed at the site of **cranial neuropore**.
- **No blood brain barrier** (Circumventricular organ).

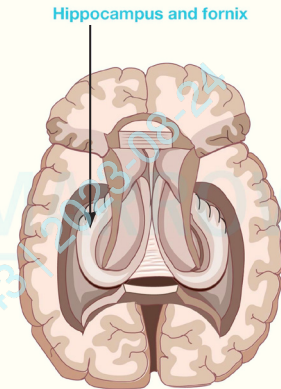
Pineal gland is also circumventricular organ.

Interpeduncular fossa contents :

- **Oculomotor nerve**.
- **Infundibulum**.
- **mamillary bodies**.
- **Posterior perforating substance**.
- **Tubercinerium**.

Hippocampus :

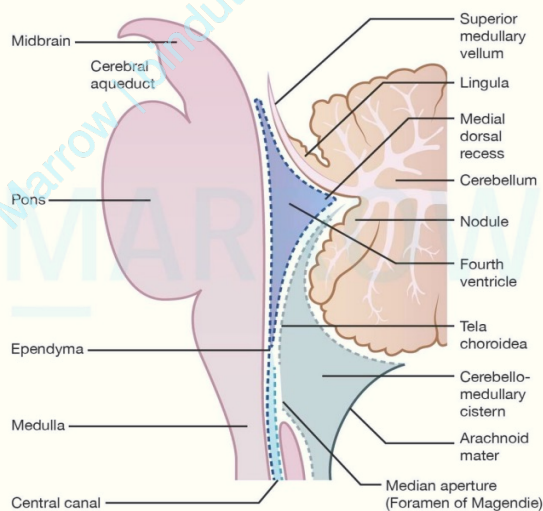
- Framing **recent memory**
- Connected to mamillary body through **fornix**.



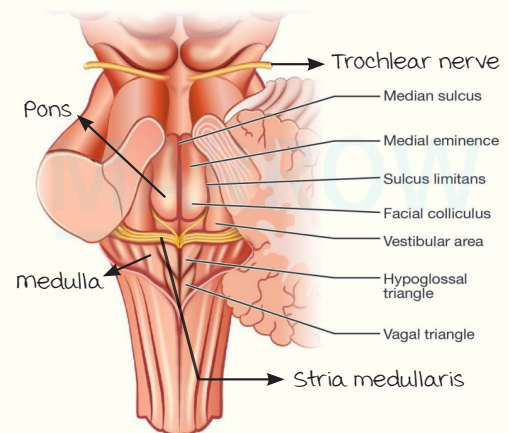
Fornix :

- Hippocampus $\xrightarrow{\text{Fornix}}$ mammillary body $\xrightarrow{\text{mammillothalamic tract}}$ Anterior nucleus of thalamus.
- **Contains** : Association > commissural > projection fibres.

Fourth ventricle :



Floor of fourth ventricle



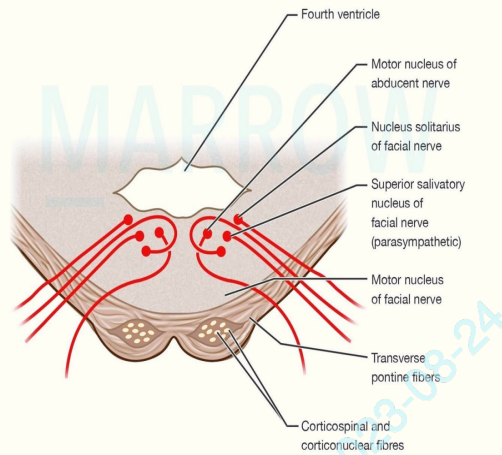
- **Floor** : Lower Pons & upper medulla.
- **Stria medullaris** : Transverse white matter fibres b/w pons & medulla.

Facial colliculus :

00:26:31

----- Active space -----

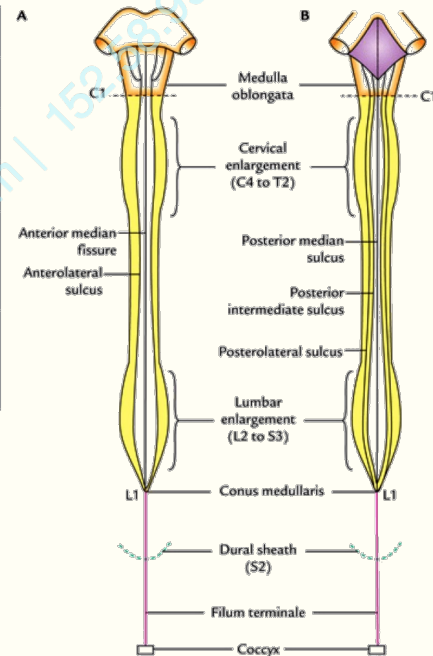
- Swelling due to axons of facial nerve winding around abducent nucleus in floor of fourth ventricle.
- Damage to Facial colliculus : CN7 > CN6.



Spinal Cord

00:28:00

Structure	Ends at
Spinal cord in adults	Lower border of L ₁
Spinal cord in newborn	Upper border of L ₃
Pia mater	Coccyx
Arachnoid membrane & subarachnoid space	Lower border of s _a
Dura mater	Converge at s _a and ends at coccyx



Level of lumbar puncture : L₃₋₄ or L₄₋₅

Descending tracts/motor tracts :

Tract	Functions
Pyramidal Tracts :	
Corticospinal tract	Fine, distal, skilled & voluntary movement.
Corticospinal tract	
Extra Pyramidal Tracts :	
Rubrospinal tract	Plan, program, regulate, modulate the movement.
Tectospinal tract	
Vestibulospinal tract	

----- Active space -----

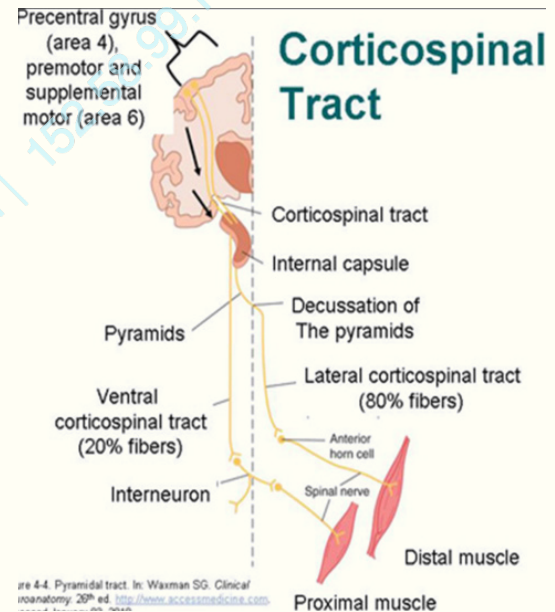
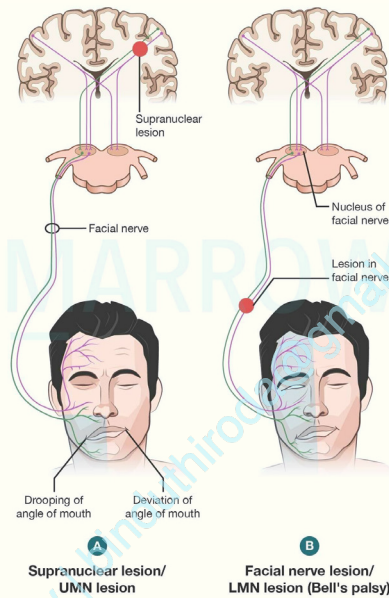
Types of motor neuron :

- upper motor neuron (UMN).
- Lower motor neuron (LMN).

UMN controls LMN (mostly by inhibition).

Features	UMN lesion	LMN lesion
Paralysis	Spastic	Flaccid
Tone	Hypertonia	Hypotonia
Deep tendon reflex	Exaggerated	Areflexia
Babinski sign	Positive	Negative

All cranial nerve nuclei controlled by both cortex (except lower facial nucleus :
Controlled only by opposite cortex).



Corticospinal tract (CST) : motor tract

Origin from Betz cells :

- 30% from primary motor area.
- 30% from premotor area.
- 40% from primary sensory area.

Lesion in corticospinal tract

- In brain stem → C/L weakness
- In spinal cord → I/L weakness

Ascending tracts / Sensory tracts :

----- Active space -----

Start at the spinal cord from dorsal root ganglion & reach thalamus (VPL nucleus) → To sensory cortex (Area 3, 1, 2).

Dorsal column tract (DCT) :

1. Nucleus gracilis :

- Carries fibres from lower limb
- Located medially.

2. Nucleus cuneatus

- Carries fibres from upper limb
- Located laterally.

Carries :

- Fine touch, proprioception
- Vibration, stereognosis
- Position sense
- 2 point discrimination

Fibres from these nuclei cross to opposite side (in medulla) & ascend as medial lemniscus.

Spinothalamic tract :

- Spinothalamic tract : Decussate in spinal cord & ascend as spinal lemniscus.
- Lesion to spinothalamic tract in spinal cord or in brain stem → C/L loss of pain, temperature, crude touch & pressure.

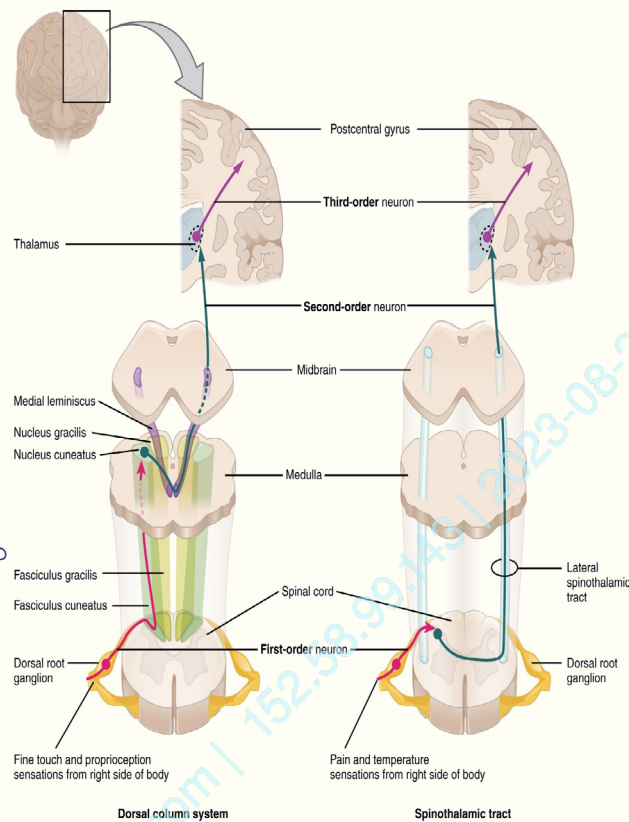
Applied Anatomy :

Tabes Dorsalis :

- Syphilitic degeneration of dorsal column tract.
- Romberg's sign : Positive.

Brown-Sequard Syndrome :

- Hemisection of spinal cord.
- At the site of lesion : Loss of all sensation .
- CST : I/L weakness.
- DCT : I/L loss of vibration, stereognosis etc.
- Spinothalamic tract : C/L loss of pain & temperature.



----- Active space -----

Brain stem

00:45:40

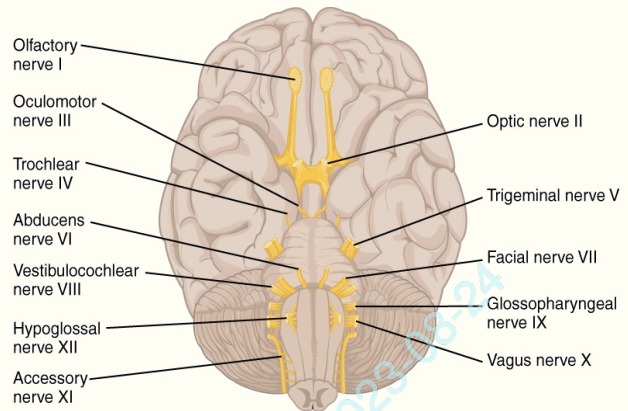
medulla :

Pyramid : median elevation.

Olive : Inferior olivary nucleus present lateral to pyramid.

Hypoglossal nerve : Between pyramid and olive.

9, 10, 11th nerve : Lateral to olive.



Pons :

Trigeminal nerve : Large sensory root & small motor root.

Abducent nerve : At pontopyramidal junction.

Facial nerve : Ponto olivary junction.

Lateral to 7th nerve : 8th nerve.

Midbrain

00:47:33

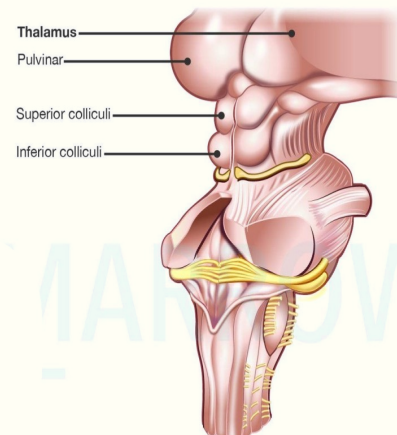
Corpora quadrigemina :

4 swellings in posterior midbrain :

- 2 Superior colliculus connected to lateral geniculate body involved in optic pathway (SLOW).
- 2 Inferior colliculus connected to medial geniculate body involved in auditory pathway (IMA)

At the level of :

- Superior colliculus → IIIrd nerve.
- Inferior colliculus → IVth nerve.



midbrain : Posterior view

Facts about cranial nerves :

Trochlear nerve :

- Slender cranial nerve (smallest).
- Longest intracranial course.
- Dorsal exit.
- Cranial nerve with internal decussation.

Longest intra dural course, common nerve to get affected in raised intra cranial pressure : Abducens Nerve.

Longest interosseous course : **Facial Nerve**.

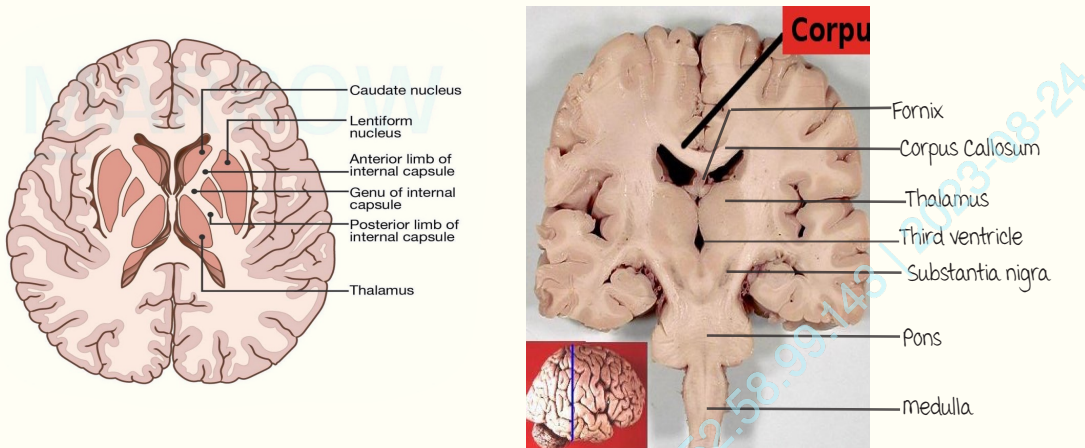
Longest extra cranial course : **Vagus Nerve**.

Largest nerve : Trigeminal nerve.

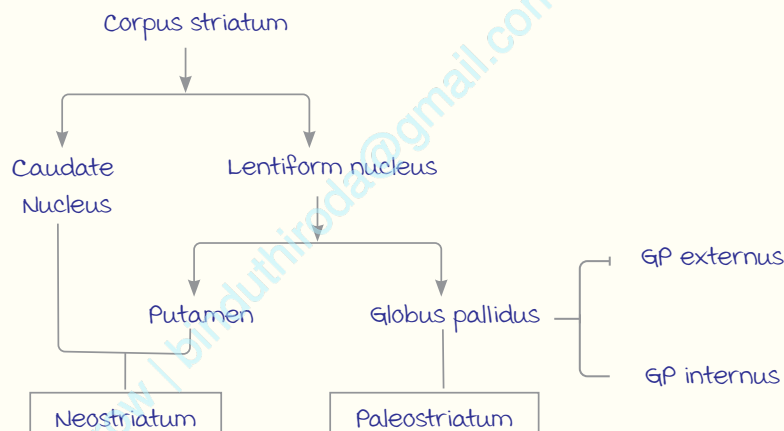
Shortest nerve : Olfactory Nerve.

Basal ganglia

00:50:30



Corpus striatum (Nuclei inside the cerebrum) : Lateral to thalamus & 3rd ventricle.



Substantia nigra :

- Contains melanin (Precursor for dopamine).
- Fibres to neostriatum via nigrostriatal pathway.

Applied anatomy : Lesions of Basal ganglia

00:54:43

Lesion	Defect
Globus pallidus	Athetosis : Spontaneous writhing movements of hand, arm, neck & face.
Putamen	Chorea : Involuntary flicking movements of hands, face and shoulders.
Substantia nigra	Parkinson's disease
Subthalamus	Hemiballismus : Sudden flailing movements of an entire limb.

----- Active space -----

Internal capsule :

00:55:50

Projection fibres : Connects cortex to subcortical structures.

Part of Internal capsule	Fibres carried	Blood supply	
		Superior/Dorsal	Inferior/Ventral
Anterior Limb		MCA : Striate branch/ Lateral Striate artery/artery of Charcot hemorrhage	Recurrent artery of Huebner/ medial striate artery
Genu	Corticonuclear tract		Internal carotid artery (capsular branch)
Posterior Limb	Corticospinal tract		Anterior Choroidal artery
Sublentiform	Auditory fibres	Anterior Choroidal artery	
Retrolentiform	Optic fibres		

Cerebellum

01:00:05

Cells :

All cells are inhibitory except Granule cell.

Purkinje cell :

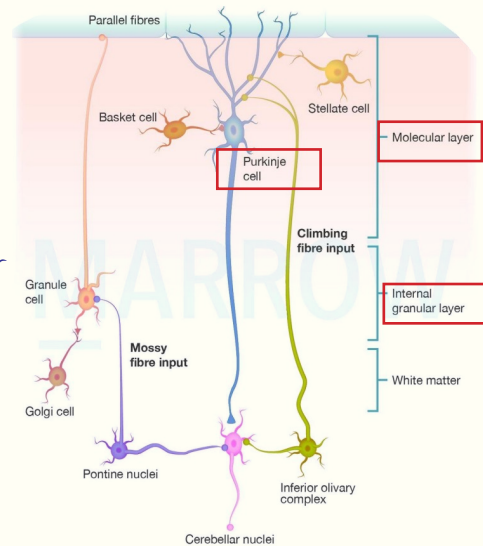
- Flask shaped.
- Gives dendrites to outer molecular layer.
- Gives axons to cerebellar nuclei → Other parts of brain.

Output from cerebellar cortex : Purkinje cell.

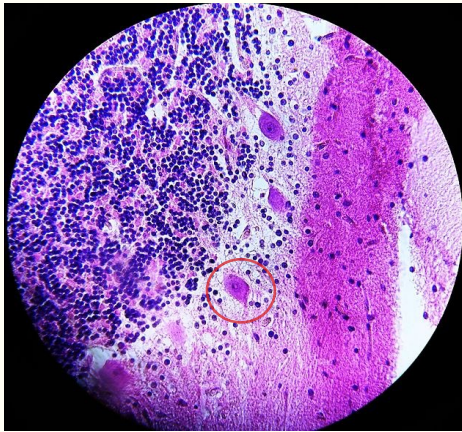
Output from cerebellum : Cerebellar nuclei.

Input to cerebellum :

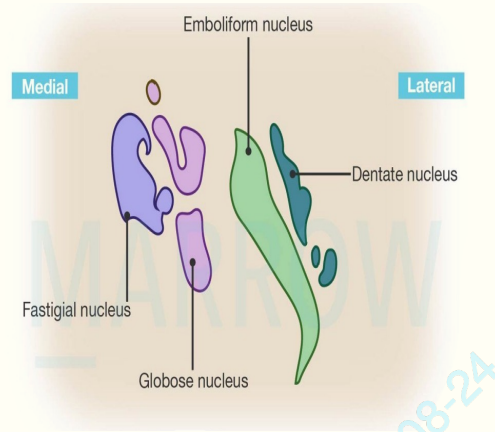
- Climbing fibres (Inferior olivary nucleus → One purkinje cell).
- Cerebello glomeruli : 1 terminal of mossy fibre + 1 granule cell + 1 golgi cell.
- From granule cell → T shaped fibre arises → Joins thousands of purkinje cells.



Purkinje cell :



Cerebellar Nuclei :



----- Active space -----

Cerebellar peduncles :

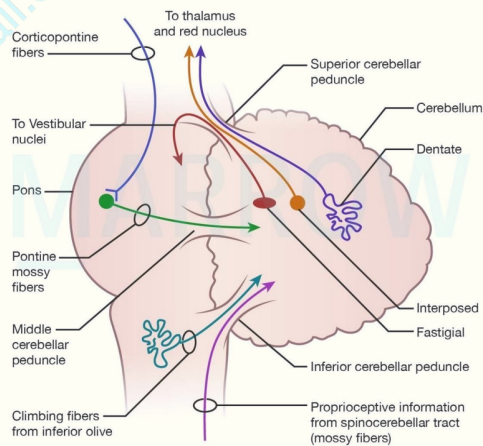
Superior cerebellar peduncle :

- Connects cerebellum to midbrain.
- Afferent : Anterior spinocerebellar tract, tectocerebellar tract.
- Efferents from dentate, emboliform, globose nucleus.
- Fibres from superior cerebellar peduncle → Decussate at midbrain → Inferior colliculus → End in red nucleus & thalamus.

Middle cerebellar peduncle :

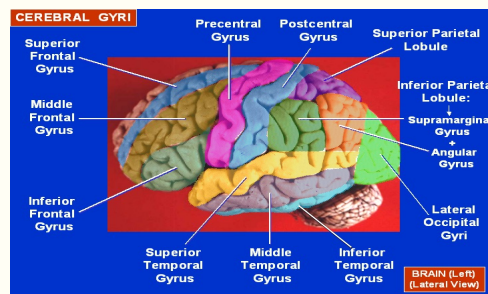
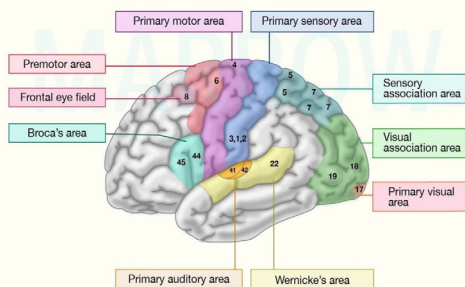
- Connects cerebellum to pons.
- Ponto cerebellar fibres.

Inferior cerebellar peduncle : Connects cerebellum to medulla.



Cerebrum

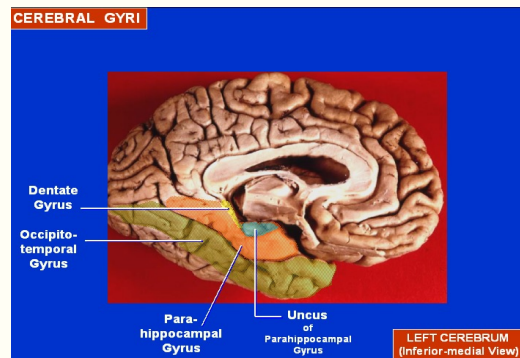
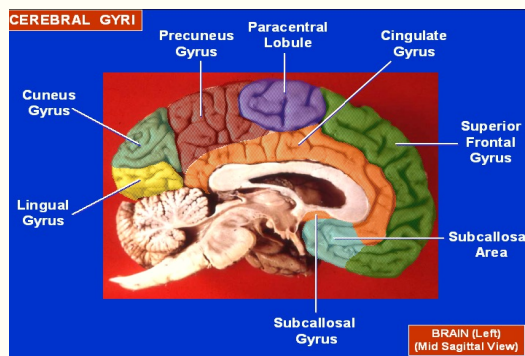
01:07:15



----- Active space -----

Gyrus		Area/Function	Area number
Pre central gyrus		Primary motor area	4
Frontal lobe	Superior frontal gyrus	Premotor area	6
	middle frontal gyrus	Frontal eye field	8
	Inferior frontal gyrus	Broca's area (motor area for speech)	44, 45
Post central gyrus		Primary sensory area	3, 1, 2
Parietal lobe	Superior parietal lobule	Sensory association area	5, 7
	Inferior parietal lobule	Hand eye co-ordination	-
Occipital lobe : Visual cortex		Primary visual area	17
		Visual association area	18, 19
Superior temporal gyrus	Anterior part	Primary auditory area	41, 42
	Posterior part	Wernicke's area (Sensory area for speech)	22

Gyrus	Function
Cingulate gyrus	<ul style="list-style-type: none"> Integrates sensory input to emotion. Emotional response to pain. Regulates aggressive behavior. Highest centre for satiety.
Paracentral lobule	<ul style="list-style-type: none"> Lower limb & perineum are represented. Highest centre for micturition & defecation.
Parahippocampal gyrus & uncus	<ul style="list-style-type: none"> Area No. 28 (Olfactory area) Smell mediated sexual behavior



Aphasia :

01:07:15

----- Active space -----

Disorder of language : In dominant lobe lesions.

Aphasia	Comprehension	Fluency	Repetition
Broca's	Present	One word speech (Telegraphic speech)	Absent
Wernicke's	Absent	Present • Jargon aphasia • Neologism • Paraphasia	Absent
Conduction aphasia (Le- sion in arcuate fasciculus)	Present	Present	Absent

Blood supply of Brain

01:14:48

Carotido Basilar system

vertebral artery :

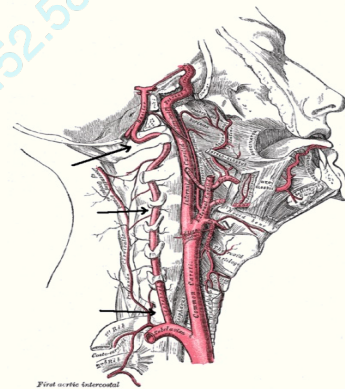
Branch of first part of subclavian artery.

1st part → In neck : very close to stellate ganglion.

2nd part → Pass through foramen transversarium of C6 to C1.

3rd part → In sub-occipital triangle.

4th part → Passes through foramen magnum and joins with opposite side to form basilar artery.



Internal carotid artery :

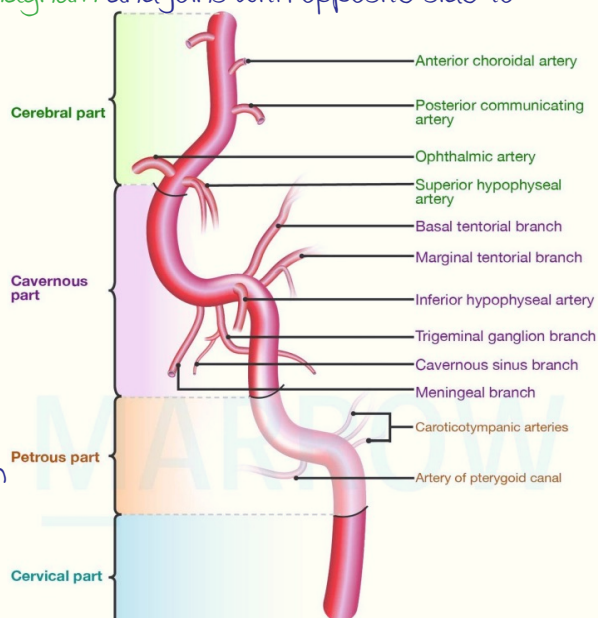
Branch of common carotid at the level of C₃-C₄.

In neck : No branches .

Petrous part : ICA → Enters cranial cavity through carotid canal → Pass inside the petrous temporal bone → Traverse the superior part of foramen lacerum.

Cavernous part : Pass inside the cavernous sinus .

Cerebral part : Gives terminal branch (middle & anterior cerebral artery).

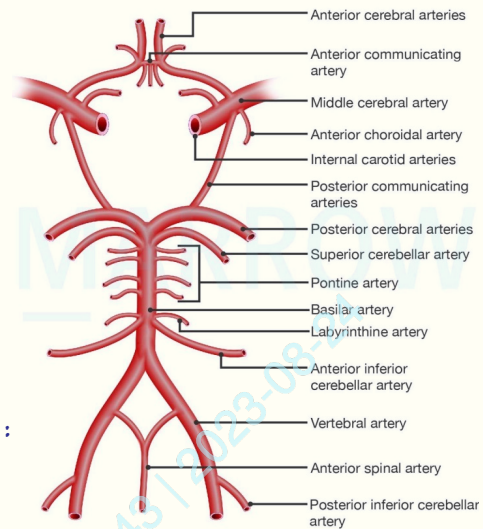


----- Active space -----

Circle of Willis :

Blood supply of medulla :

- **Anterior spinal artery** : Supplies medulla
→ Passes through foramen magnum → Supplies anterior 2/3rd of spinal cord.
- **Posterior spinal artery** : Branches of vertebral artery in medulla.
Supplies medulla → Descends posteriorly through foramen magnum → Supplies posterior 1/3rd of spinal cord.
- **Posterior inferior cerebellar artery (PICA)** : Branch of vertebral artery in medulla → Supplies medulla & cerebellum.
- **Basilar artery** : Gives branches to medulla.

medial medullary syndrome : **Anterior spinal artery** involved.Lateral medullary syndrome (Wallenberg syndrome) : **vertebral artery > PICA.**

Blood supply of Pons :

1. Anterior inferior cerebellar artery : Gives labyrinthine artery in 80% (20% from basilar artery).
2. Pontine branches from basilar artery.
3. Superior cerebellar artery.

Blood supply of cerebellum :

- Superior cerebellar artery.
- Anterior inferior cerebellar artery.
- Posterior inferior cerebellar artery.

Blood supply of midbrain, thalamus, visual cortex : Posterior cerebral artery.

Note : **MCA** is not involved in formation of Circle of Willis.**Aneurysms :**

Aneurysms of anterior communicating artery : Compress optic chiasma.

Aneurysms of posterior communicating artery : Compress oculomotor nerve.

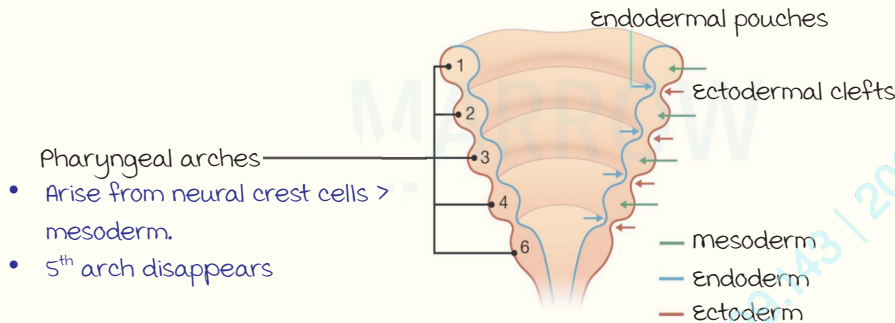
ANATOMY REVISION 3

----- Active space -----

Development of head and neck

00:00:12

Development and derivatives of pharyngeal arch :



Pharyngeal arches

Pharyngeal arch derivatives : Artery, cartilage, bone, ligaments, muscle, nerve.

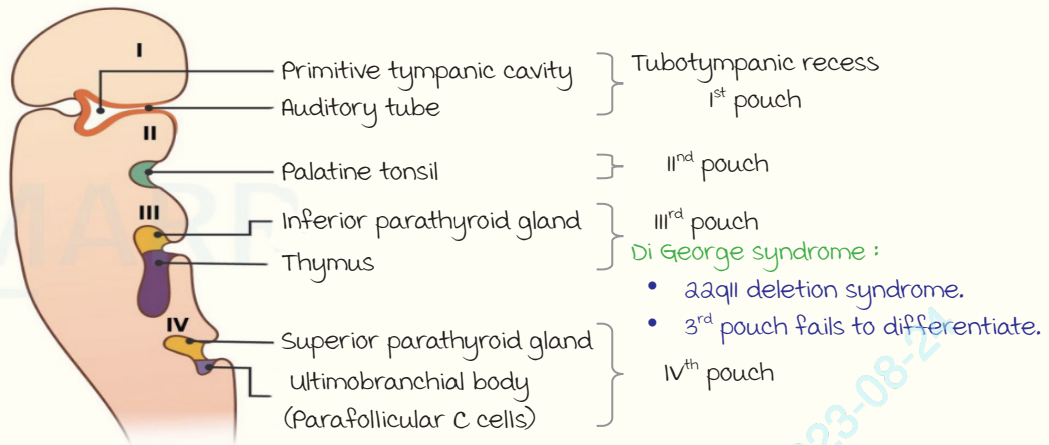
Pharyngeal arch	Cartilage	muscle	Nerve
1 st arch	malleus, incus, skull.	mastication muscles, tensor palatini, tensor tympani, mylohyoid, anterior belly of digastric.	mandibular
2 nd arch	Stapes, Styloid, Stylohyoid lig, Small horn of hyoid, Sup. surface of hyoid (SS).	Facial muscles, stylohyoid, posterior belly digastric, Stapedius	Facial
3 rd arch	Greater horn of hyoid, Inferior surface of hyoid.	Stylopharyngeus	Glossopharyngeal
4 th arch	Cartilages of larynx	muscles of pharynx, palate, cricothyroid	Superior laryngeal
6 th arch	except epiglottis.	muscles of larynx except cricothyroid	Recurrent laryngeal

High yield points :

- All muscles of larynx develop from 6th arch except cricothyroid : 4th.
- All muscles of pharynx develop from 4th arch except stylopharyngeus : 3rd.
- All muscles of palate develop from 4th arch except tensor palatini : 1st.
- All muscles of tongue derived from somites except palatoglossus : 4th.
- Anterior belly of digastric derived from 1st arch.
- Posterior belly derived from 2nd arch.
- Tensor tympani derived from 1st arch.
- Stapedius derived from 2nd arch.

----- Active space -----

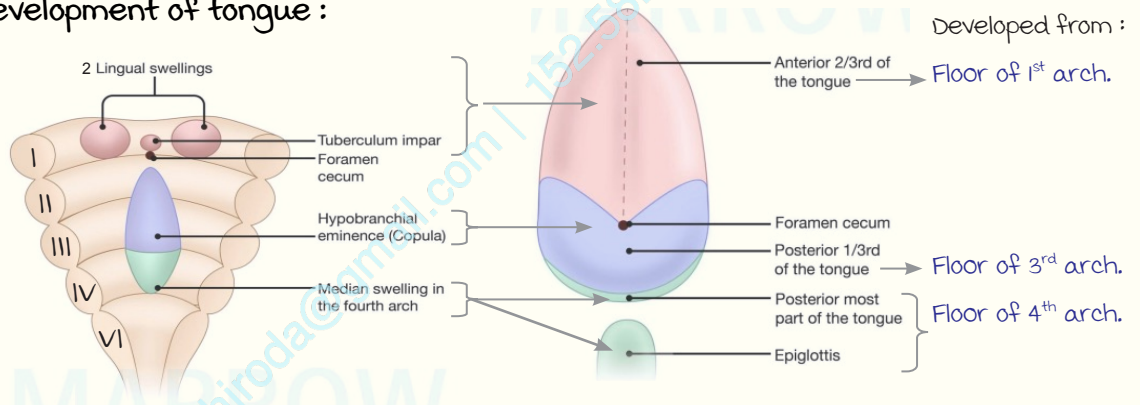
Pharyngeal pouch derivatives :



Pharyngeal pouch derivatives

Note : Parafollicular C cells arise from **neural crest cells** > ultimobranchial body.

Development of tongue :



Note : 2nd arch is not contributing to the development of tongue

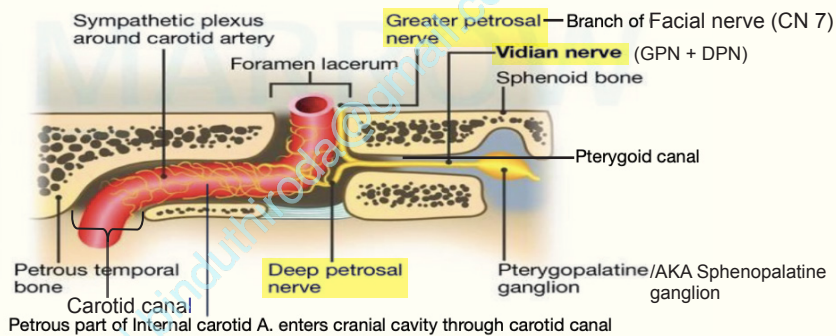
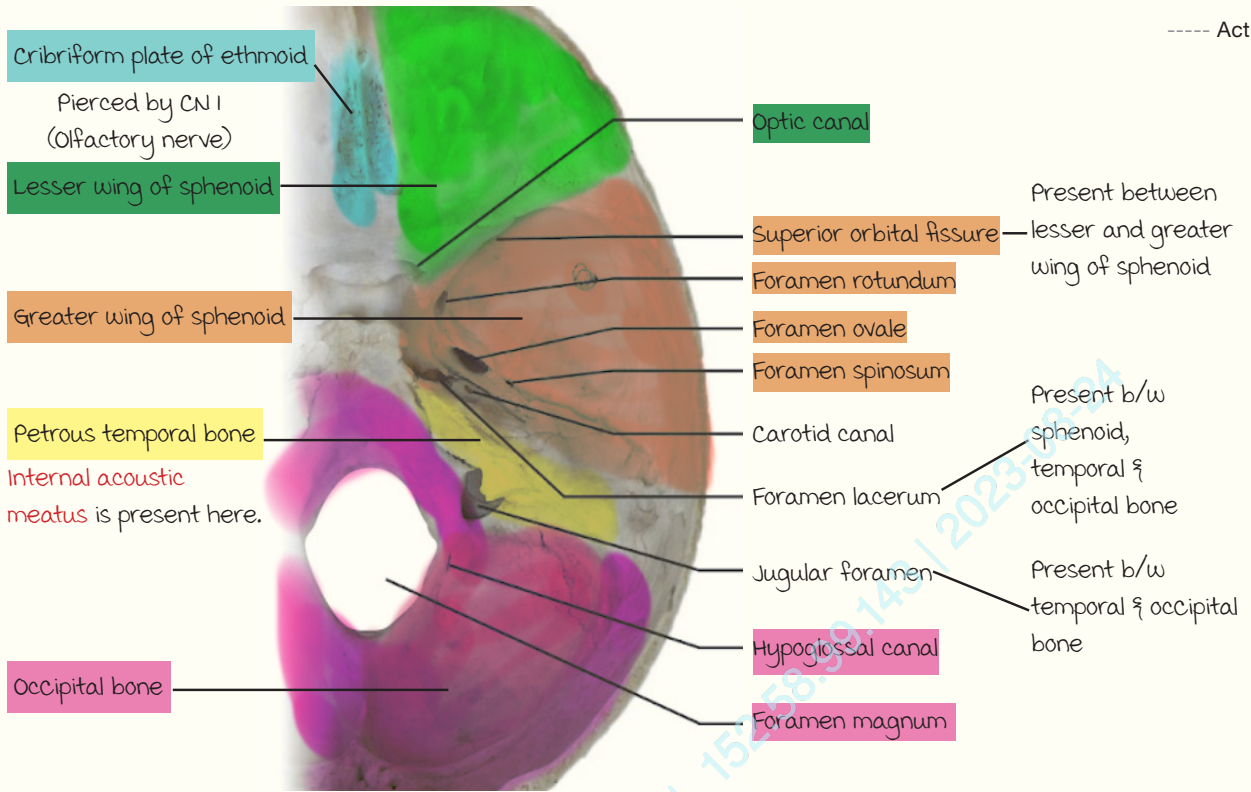
Osteology of head and neck

00:10:36

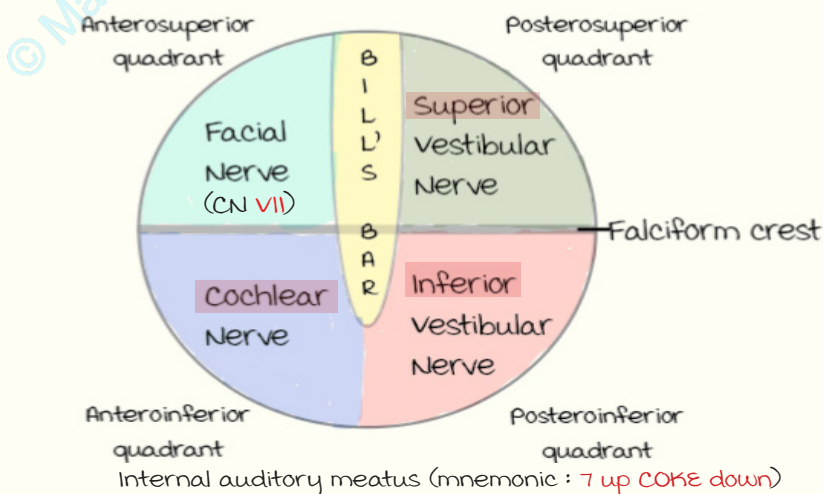
Foramina in the skull :

Foramen	Contents
Optic canal	Optic nerve. Ophthalmic artery.
Ovale	Mandibular nerve. Accessory meningeal artery. Lesser petrosal nerve. Emissary vein connecting cavernous sinus & pterygoid venous plexus.
Spinosum	Middle meningeal artery and vein. Emissary vein. Nervous spinosum.
Rotundum	maxillary nerve.

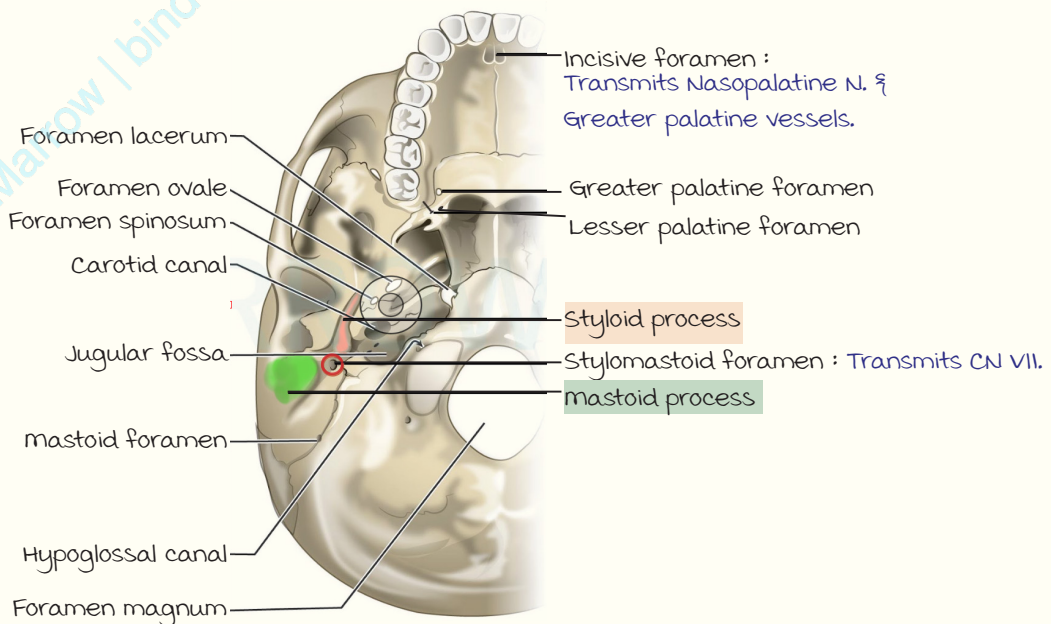
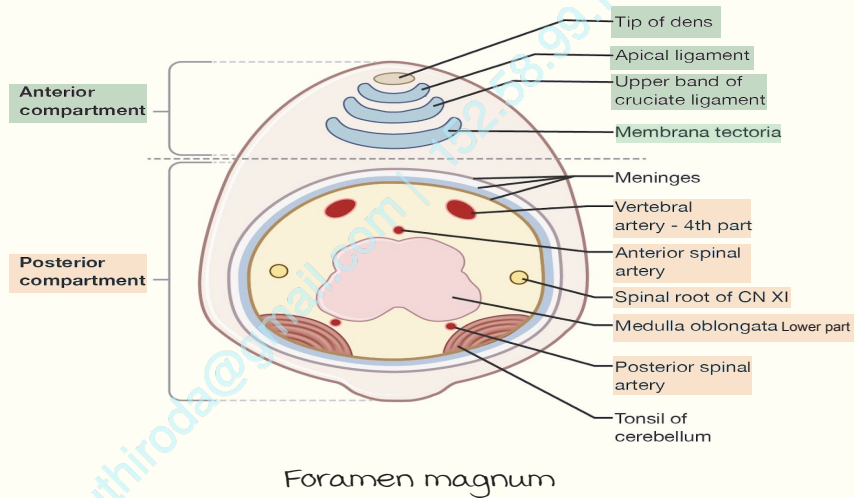
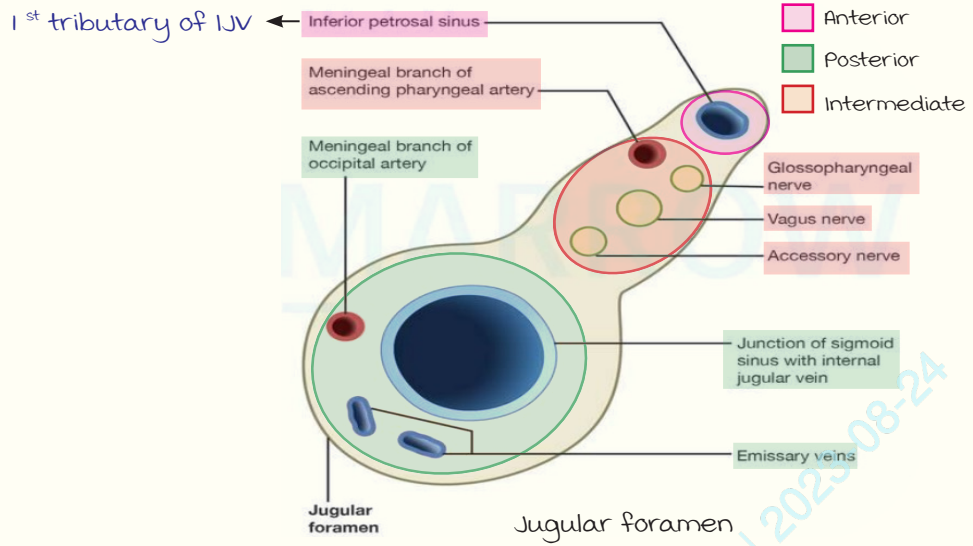
----- Active space -----



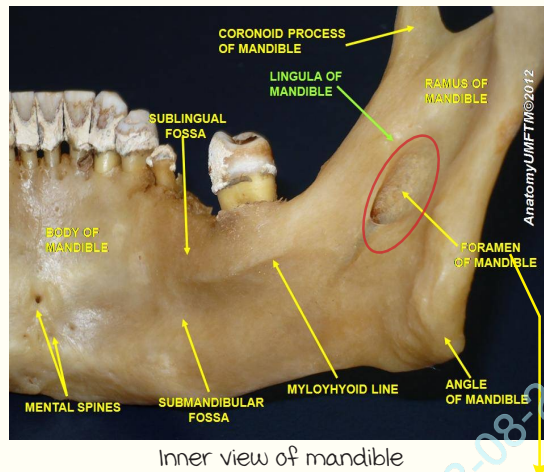
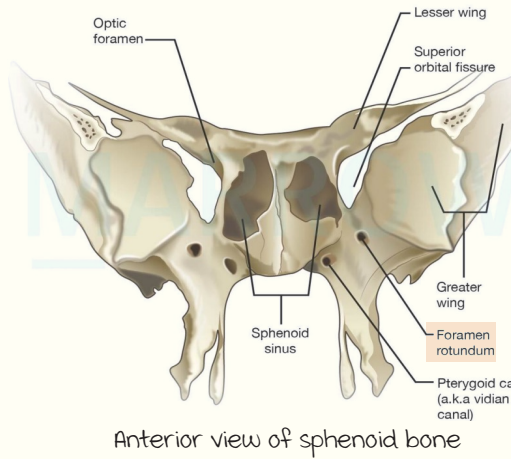
Structures passing through foramen lacerum



----- Active space -----



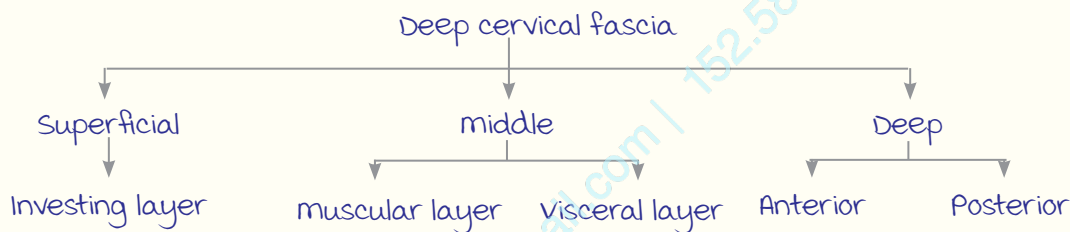
----- Active space -----



Transmits Inferior alveolar nerve & vessels.

Deep cervical fascia of the neck

00:24:34



Superficial (Investing) layer :

- Splits to enclose 2 muscles : sternocleidomastoid and trapezius.
- It forms the roof of posterior triangle.
- It provides capsule for 2 glands : Parotid & submandibular.

Applied aspect : Parotid swellings are painful due to unyielding nature of the capsule.

middle layer :

1. muscular : Infrahyoid muscle.

2. visceral

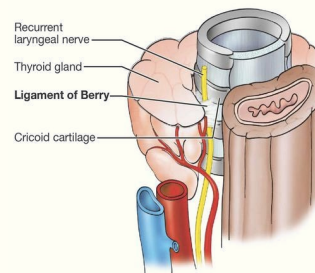
A. Pretracheal layer:

- Splits to enclose thyroid gland, trachea & esophagus
- Ligament of berry: Post. thickening of fascia Connecting thyroid gland to cricoid cartilage.

Hence thyroid gland and it's swellings moves with deglutition.

Note : Thyroglossal cyst moves with the protrusion of tongue.

B. Bucco pharyngeal layer.



----- Active space -----

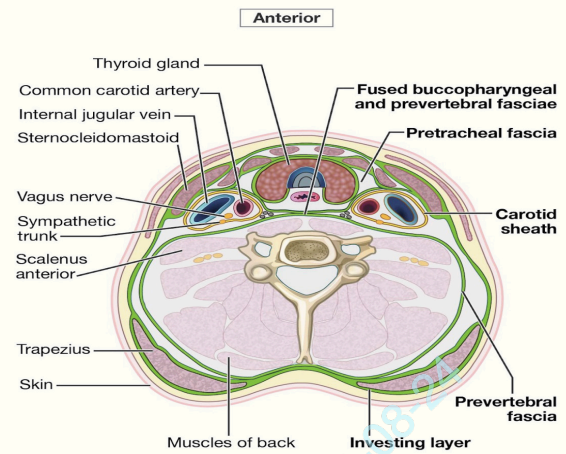
Deep layer :

- Anterior: Alar fascia fuses with buccopharyngeal fascia at C7.
- Posterior : prevertebral fascia.
 - a. Covering for prevertebral muscles.
 - b. Forms floor of posterior triangle.
 - c. Contributes to axillary sheath.

Contents : Axillary A. & Brachial plexus.

Axillary vein is not present inside the axillary sheath.

Note : Posterior triangle lies in between Sternocleidomastoid and Trapezius.



Deep fascia in the neck

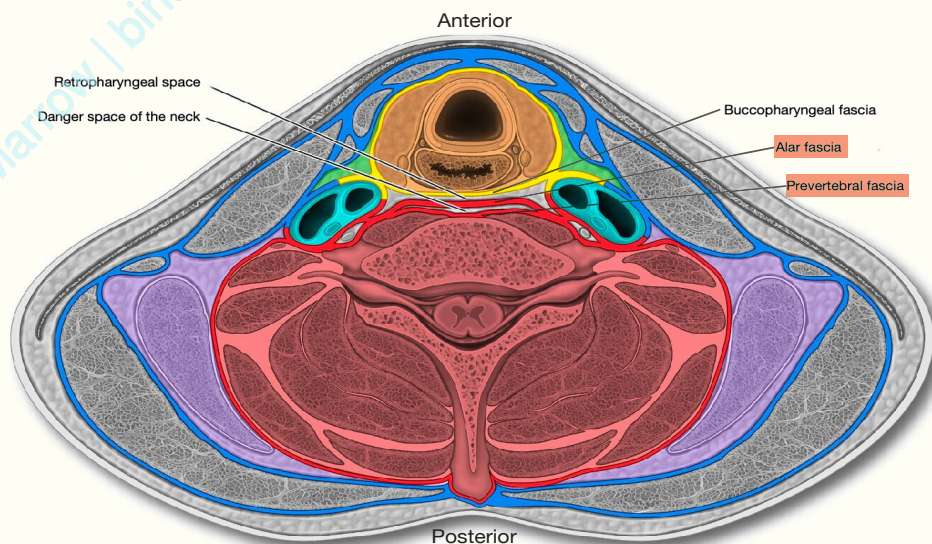
Carotid sheath :

- All the layers of deep cervical fascia contribute to carotid sheath.
- Contents : **vessels** : CCA, ICA, IJV, **Nerves** : CN X ± CN IX, XI, XII (only near base of skull).

Note : **Cervical sympathetic chain** is present **behind** the carotid sheath and is not a content.

CCA : Common Carotoid A., ICA : Internal carotid A., IJV : Internal jugular vein.

Danger area in the neck



- This area extends from base of skull to mediastinum.
- Any infection might easily spread to base of skull or mediastinum.

Neurovascular structures & Lymph nodes in neck

00:32:13

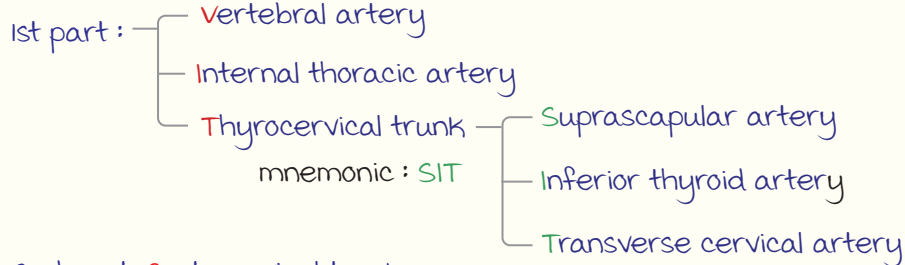
----- Active space -----

Arteries in the neck :

1. Subclavian A. and its branches :

Scalenus muscle divides subclavian A. into 3 parts :

mnemonic : **VIT C-D**



2nd part: **C**ostocervical trunk

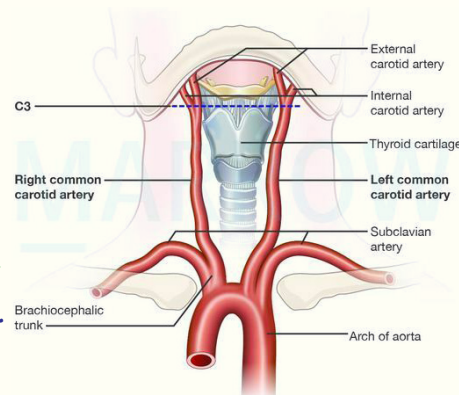
3rd part: **D**orsal scapular artery

Inferior thyroid artery supplies

- a. Cervical esophagus
- b. Parathyroid gland
- c. Thyroid gland
- d. Thymus (main supply : Int. thoracic A.)

2. Common carotid A. :

- Left common carotid artery arises from arch of aorta.
- Right common carotid artery arises from brachiocephalic trunk.
- Common carotid artery **bifurcates** into internal and external at the level of **C3-C4** (**C4 > C3**)/upper border of thyroid cartilage.



A. Internal carotid artery has no branches in the neck.

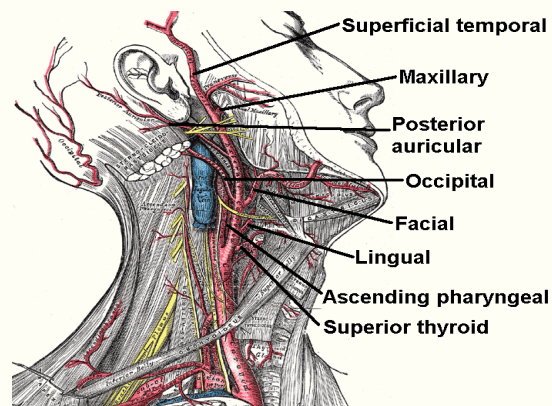
B. External carotid artery and its branches :

Anteriorly : Superior thyroid, Lingual & Facial artery.

medially : Ascending pharyngeal (1st branch).

Posteriorly : Occipital & Posterior auricular artery.

Terminally : Superficial temporal & maxillary artery.



----- Active space -----

Nerves in the neck :

Ansa cervicalis

C1 : Superior root }
 C2, C3 : Inferior root } — Ansa cervicalis

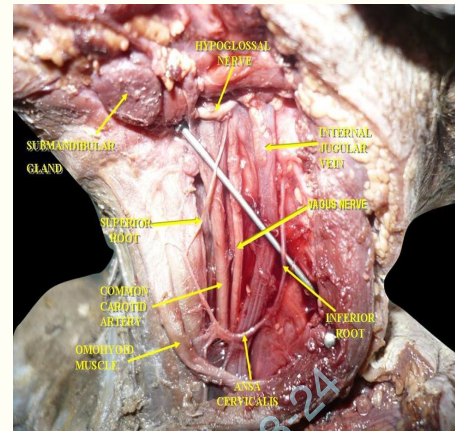
C1 + CN XII supplies geniohyoid & thyrohyoid ms.

Phrenic nerve

Root value : C3, C4, C5

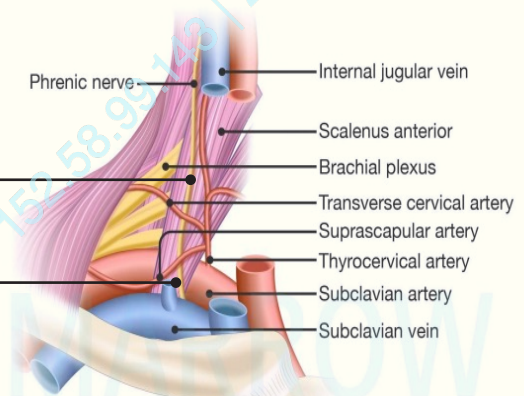
mixed nerve.

- motor supply to diaphragm.
- Sensory supply to pleura, pericardium & diaphragm.



Passes anterior to Scalenus anterior

Enters thorax in between Subclavian vein in front and artery behind

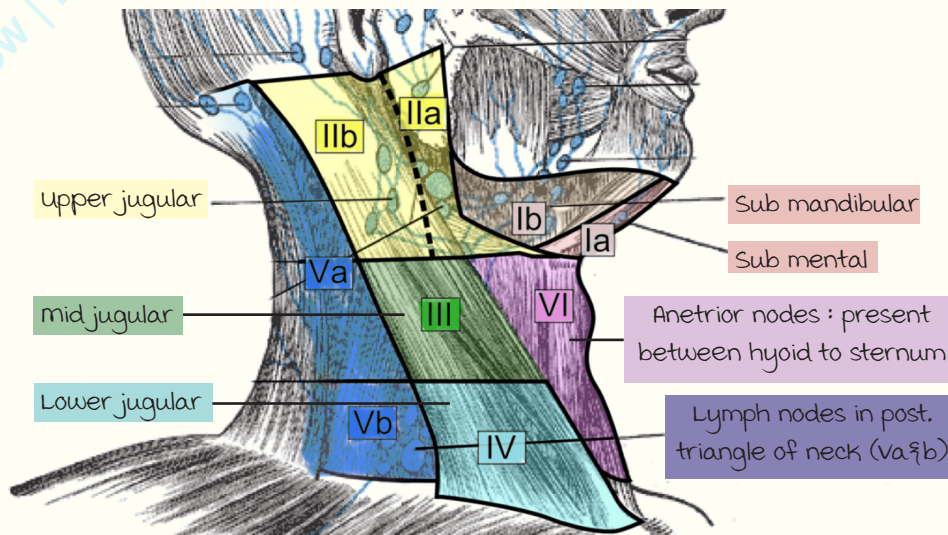


Note : In thorax,

Phrenic nerve passes anterior to hilum of lung.

vagus passes posterior to hilum of lung.

Lymph nodes in the neck :



Level VII : mediastinal nodes

Radical neck dissection :

Lymph node clearance + Sternocleidomastoid + IJV + Spinal accessory N.

modified radical neck dissection :

Lymph node clearance + Preservation of non lymphatic structures.

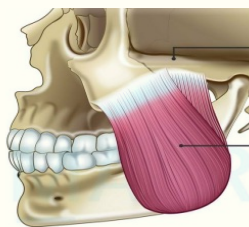
----- Active space -----

Infratemporal region

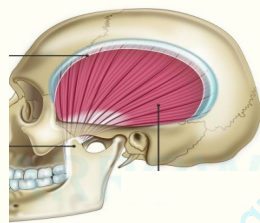
00:43:00

muscles of mastication :

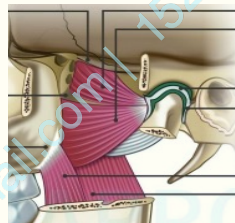
muscles	Origin	Insertion	Action
masseter	Zygomatic arch	Outer surface of ramus of mandible	Strong elevator
Temporalis	Temporal fossa	Coronoid process of mandible	Elevation > Retraction
Lateral pterygoid	Infra temporal crest of sphenoid & lateral pterygoid plate.	Head of mandible, articular disc & capsule of TMJ	Depression (only muscle) > Protrusion.
medial pterygoid	Lateral pterygoid plate & maxillary tuberosity	Inner surface of ramus of mandible	Elevation > Protrusion



masseter



Temporalis

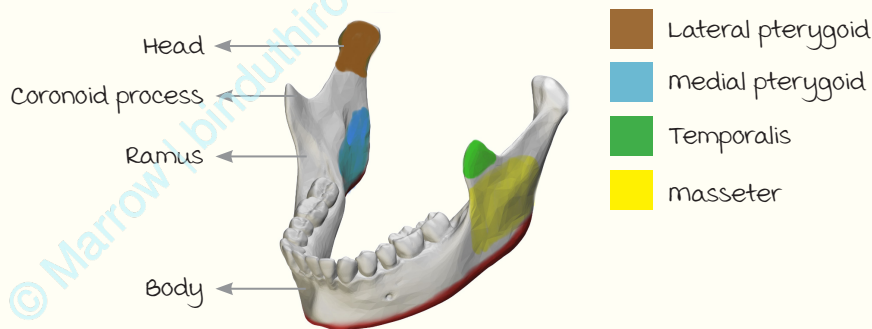


Upper & lower head of Lateral pterygoid

TMJ

Superficial & deep head of medial pterygoid

Pterygoids



Insertion of muscles

Note : All masticatory muscles are supplied by mandibular nerve.

Best muscle for:

- Elevation : masseter > Temporalis > medial pterygoid.
- Depression : Lateral pterygoid.
- Protrusion : Lateral pterygoid muscle > medial pterygoid.
- Retraction : Temporalis.

----- Active space -----

maxillary artery :

00:46:48

Terminal division of external carotid artery.

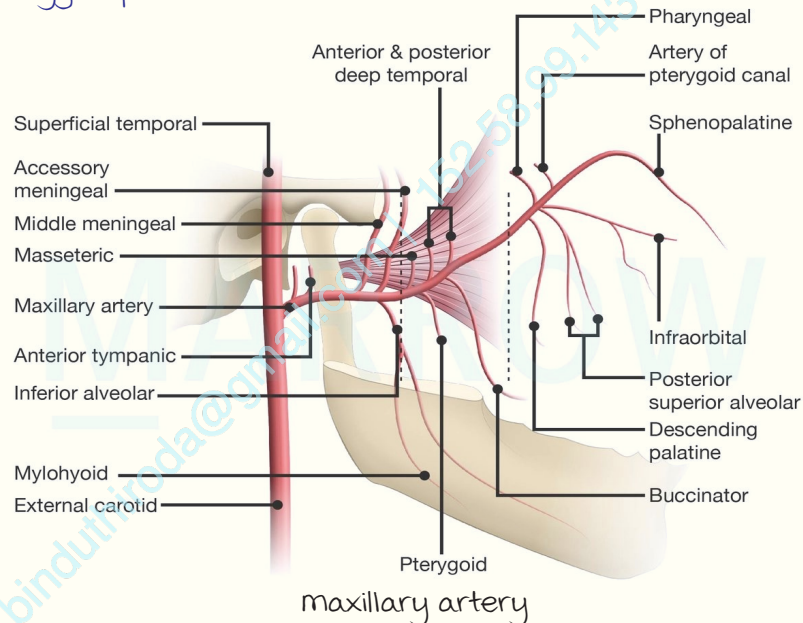
Divided into 3 parts by lateral pterygoid muscle :

1st part/mandibular part (MAIDA) :

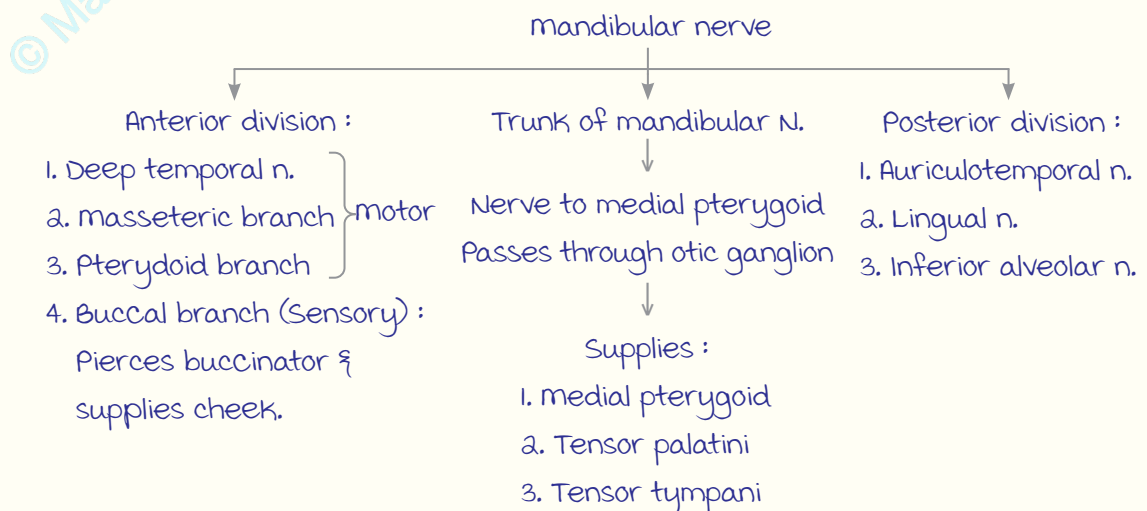
- middle meningeal a.
- Accessory middle meningeal a.
- Inferior alveolar a.
- Deep auricular a.
- Anterior tympanic a.

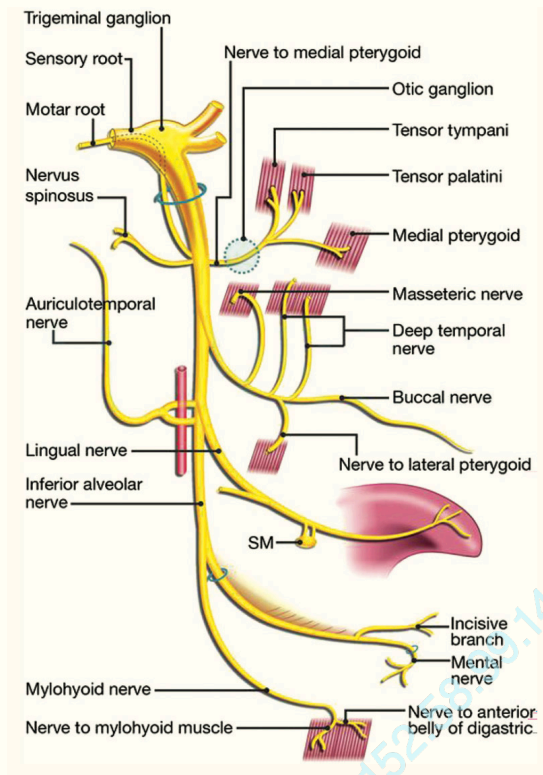
3rd part/Pterygopalatine part (PIG PAS) :

- Posterior superior alveolar a.
- Infraorbital a. (Inferior orbital fissure)
- Greater palatine a.
- Pharyngeal a. (Pharyngeal canal)
- Artery to pterygoid canal
- Sphenopalatine a. (Sphenopalatine foramen)

2nd part/pterygoid part : muscular branches to muscles of mastication.**mandibular nerve : mixed nerve.**

00:46:46





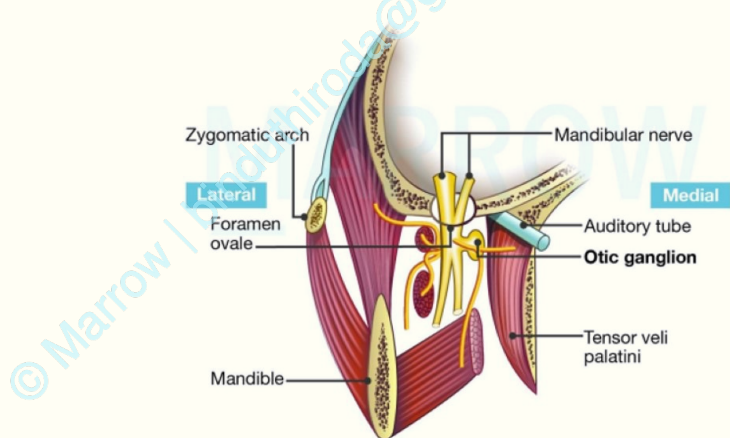
----- Active space -----

Course of mandibular nerve

Otic ganglion :

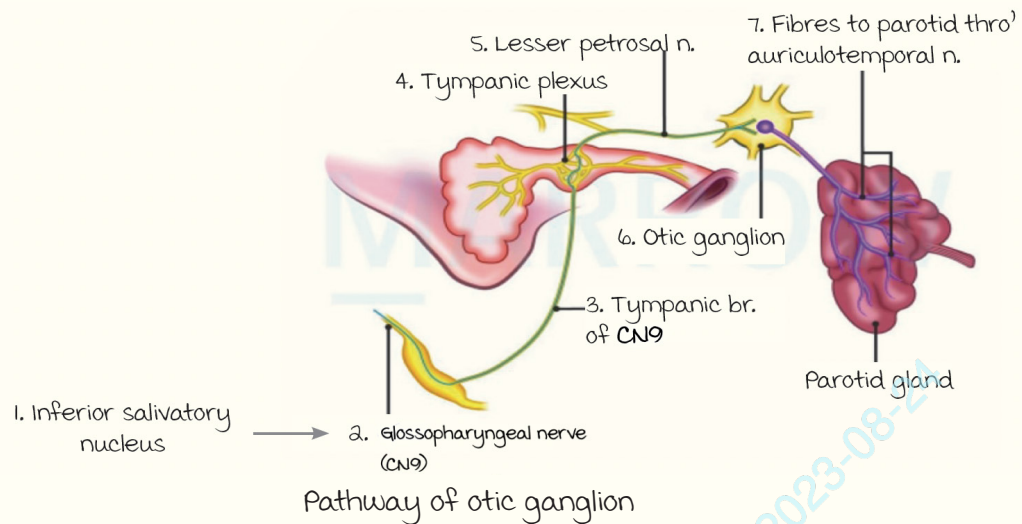
Attached to mandibular nerve topographically.

Attached to glossopharyngeal nerve functionally.



Relation of otic ganglion (coronal view of infratemporal fossa)

----- Active space -----



Applied aspect :

Frey syndrome :

Injury to auriculotemporal n. (Parotidectomy)

↓
Regenerated auriculotemporal n.

↓
Innervates sweat glands (instead of parotid gland).

Lingual nerve :

- Receives chorda tympani (branch of facial nerve).
- Crosses submandibular duct → m/c nerve affected during Sm duct excision.

Inferior alveolar nerve :

- Gives nerve to mylohyoid (supplies anterior belly of digastric & mylohyoid).
- Passes through mandibular foramen → Sensory supply to face.

Dural Venous Sinuses

00:55:19

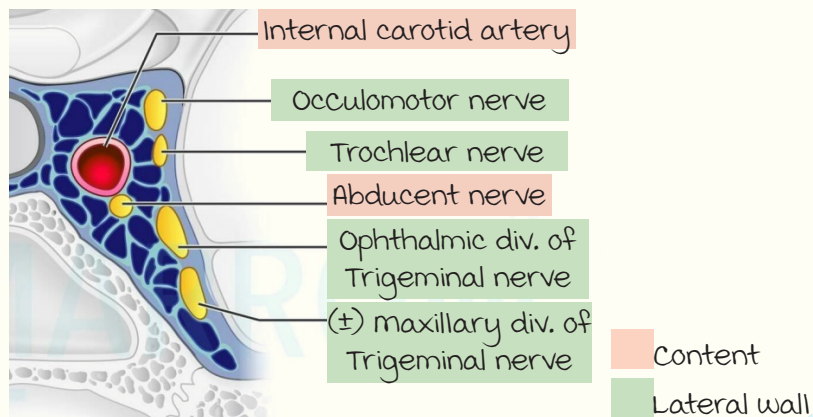
Cavernous sinus :

Paired dural venous sinus located on either side of body of sphenoid bone.

Relations :

medial : Sphenoidal sinus, pituitary gland.

Lateral : Trigeminal ganglion.

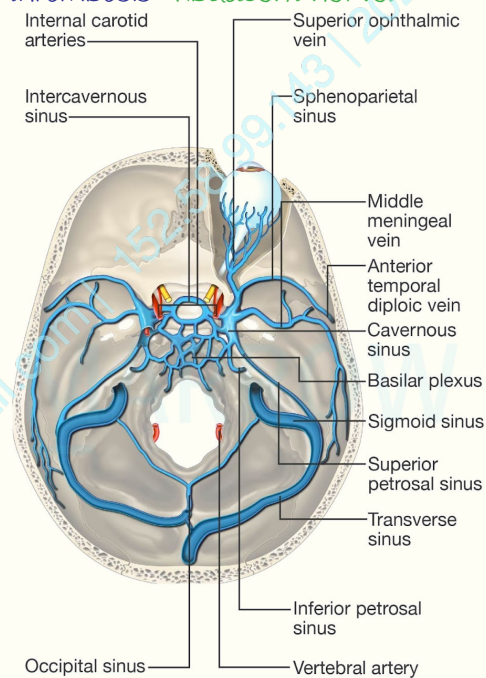


Relations of cavernous sinus

1st nerve to get affected in cavernous sinus thrombosis : **Abducent nerve.**

Tributaries (Inflow) :

- Superior ophthalmic vein
- Inferior ophthalmic vein
- Central vein of retina
- Superficial middle cerebral vein
- Inferior cerebral vein
- Sphenoparietal sinus
- middle meningeal vein



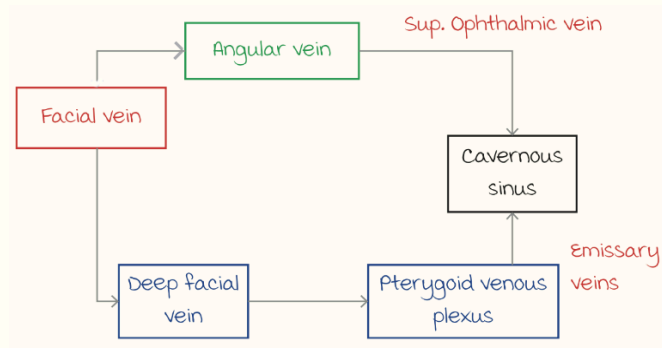
Dural venous sinuses

Communicating (out flow) channels :

- **Superior petrosal sinus** : Cavernous sinus → Transverse sinus.
- **Inferior petrosal sinus** : Cavernous sinus → Internal jugular vein.
- **Anterior & posterior inter cavernous sinus** : Connect cavernous sinus of two sides. Hence, Cavernous sinus thrombosis always present bilaterally.

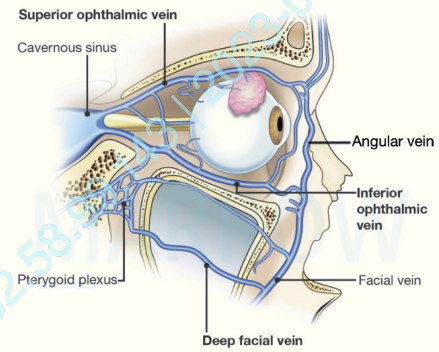
----- Active space -----

Communication b/w cavernous sinus & facial vein :



m/c communicating channel :

Superior ophthalmic vein > Deep facial vein.



Communication b/w cavernous sinus & facial vein

© Marrow | binduthiroda@gmail.com | 152.58.77.223 | 23-08-24

ANATOMY REVISION 4

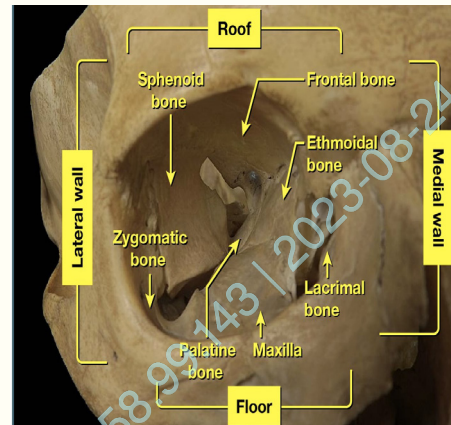
----- Active space -----

Orbit & extra ocular muscles

00:00:22

Bones forming orbit :

Wall	Structures
Roof	Frontal, lesser wing sphenoid.
Floor (m/c to #)	maxilla, zygomatic, palatine.
Lateral wall	Zygomatic, greater wing of sphenoid.
medial wall (thinnest)	Lacrimal, ethmoid, body of sphenoid, maxilla.



Optic canal/foramen : In lesser wing of sphenoid.

Superior orbital fissure (SOF) : B/w roof & lateral wall.

Inferior orbital fissure : B/w floor & lateral wall.

Structures passing through SOF	
Superolateral compartment	Lacrimal, frontal and trochlear nerve, superior ophthalmic vein.
Intermediate compartment/ common tendinous ring	Superior and inferior division of oculomotor nerve, nasociliary and abducent nerve.
Inferomedial compartment	Inferior ophthalmic vein.

Mnemonic :

LFT for superolateral compartment.

SONIA passes through intermediate compartment.

Extraocular muscles :

Levator palpebrae superioris : For elevation of eyelid.

muscle	1° action	2° action	3° action
Superior rectus	Elevation	Intorsion	Adduction
Inferior rectus	Depression	Extorsion	Adduction
medial rectus	Adduction	-	-
Lateral rectus	Abduction	-	-
Superior oblique	Intorsion	Depression	Abduction
Inferior oblique	Extorsion	Elevation	Abduction

----- Active space -----

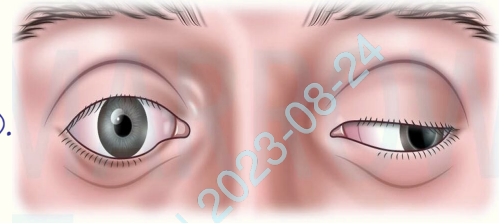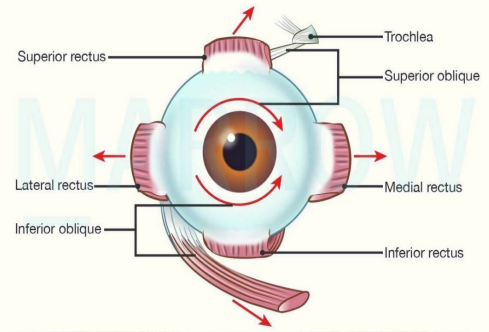
Note :

SIN → Superior muscles : Intorsion.

RAD → Recti : Adductors.

Oculomotor nerve palsy :

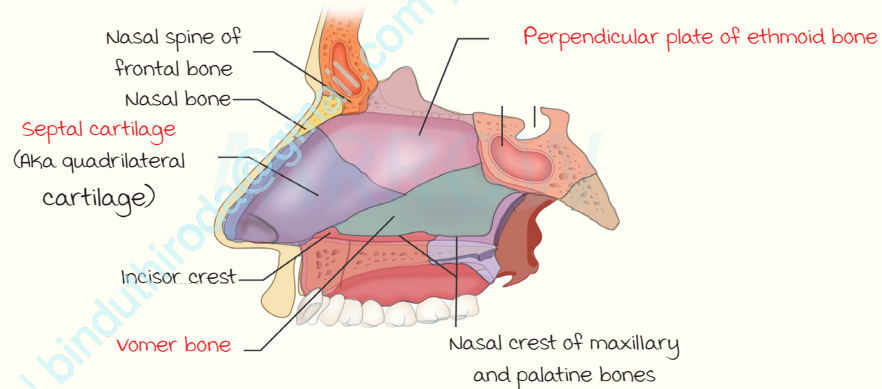
- Ptosis (LPS palsy).
- Dilated pupil (Sphincter pupillae muscle palsy).
- Down and out (SO4 and LR6 are spared).
- Loss of light & accommodation reflex.



Left oculomotor nerve palsy

Nose

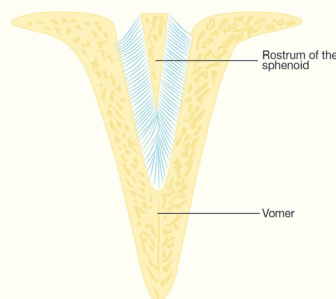
00:09:30

medial wall/nasal septum :

Red : major contributors.

Others are minor contributors.

Schindylesis/sphenovomerian joint : B/w vomer & rostrum of sphenoid.



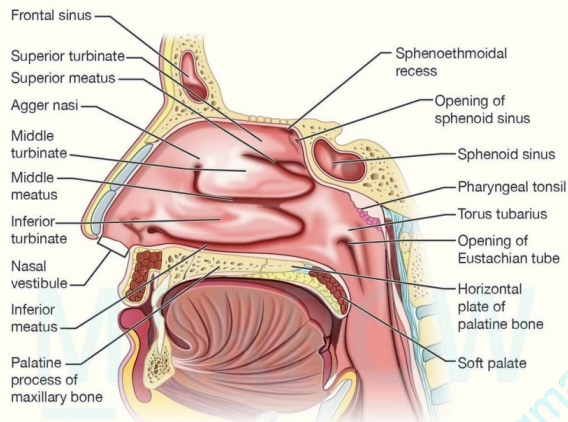
Schindylesis joint

Little's area :

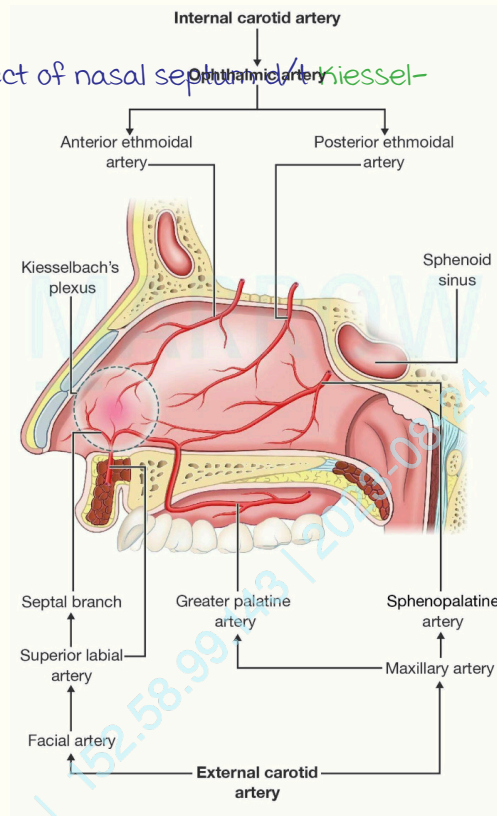
- Highly vascular area in anteroinferior aspect of nasal septum. **Kiesselbach plexus.**
- **Posterior ethmoidal artery** does not contribute to plexus.

Lateral wall of nasal cavity :

- Prominent elevations in lateral wall : Turbinates (3 in no.)
- Inferior turbinate is a **separate bone** (Not part of ethmoid bone).



Lateral wall of nasal cavity



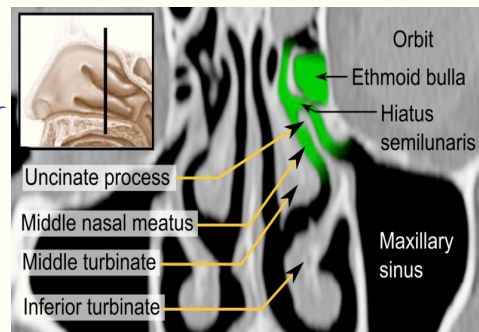
Little's area

----- Active space -----

Osteomeatal complex/OMC :

Comprise of :

- **Bulla ethmoidalis** : most prominent anterior ethmoidal sinus.
- **Uncinate process** : Part of ethmoid bone.
- **Hiatus semilunaris** : Opening b/w uncinate process and ethmoid bulla.
- **Receives opening of 3 sinuses** : maxillary sinus, ant. ethmoidal sinus, frontal sinus.



Osteomeatal complex

Block in OMC → Sinusitis.

meatus	Openings
Sphenoethmoidal recess	Sphenoid sinus
Superior meatus	Posterior ethmoidal sinus
middle meatus	OMC
Inferior meatus	Nasolacrimal duct

Tongue

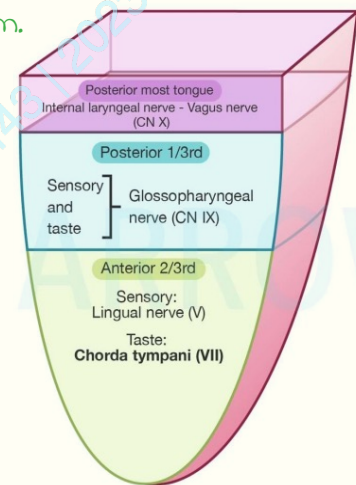
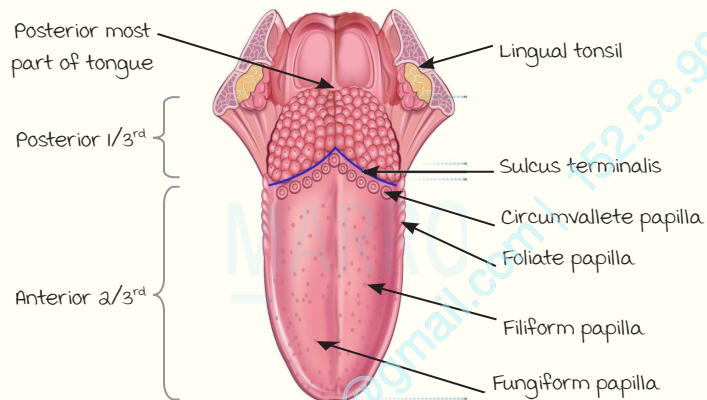
00:17:45

Papillae :

- Have taste buds (except **filiform**).
- Lined by **stratified squamous non keratinised epithelium** (except **filiform**).
- Supplied by **chorda tympani** (except **circumvallate papillae** which are supplied by **glossopharyngeal nerve**).

Filiform papillae :

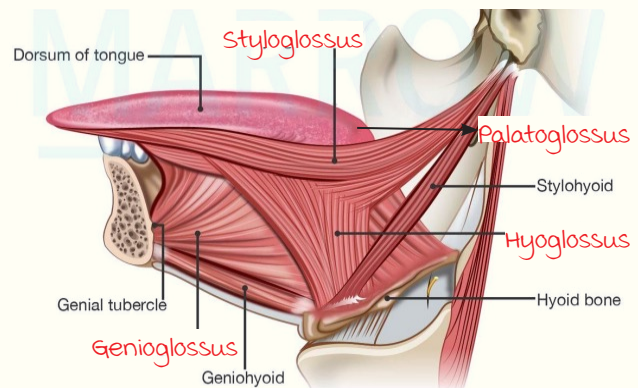
- Have no taste buds.
- Lined by **keratinised stratified squamous epithelium**.
- Holds food particles together.



Nerve supply of tongue

muscles of tongue :

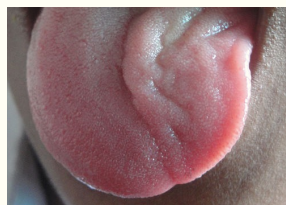- Nerve supply : Hypoglossal nerve (except palatoglossus : pharyngeal plexus).
- Genioglossus : Protrusion of tongue (Safety muscle of tongue).



muscles of tongue

Hypoglossal nerve palsy :

- Ipsilateral tongue atrophy.
- Tongue deviation to **lesion side**.



Hypoglossal nerve palsy (l/L deviation)

Pharynx

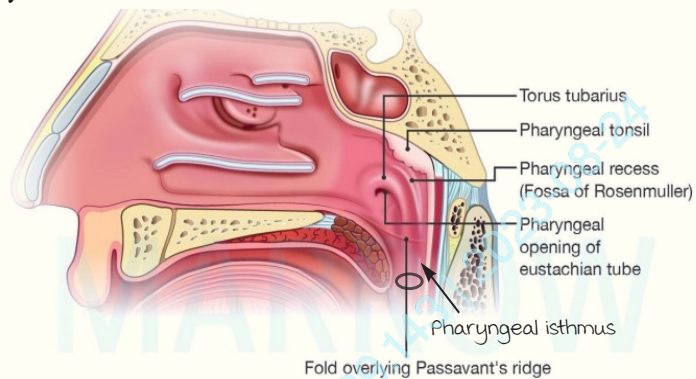
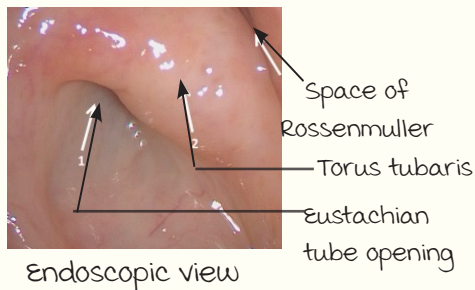
00:23:40

----- Active space -----

Extent : Base of skull → C6 (Continues as esophagus).

Parts of pharynx : Nasopharynx, oropharynx, laryngopharynx.

Structures seen in nasopharynx :



Structures seen in Nasopharynx

Pharyngeal isthmus :

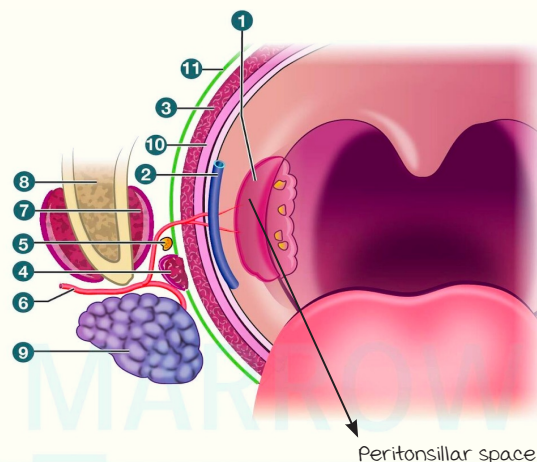
- Gap b/w soft palate & posterior pharyngeal wall.
- Closed by **Passavant's ridge** : Palatopharyngeus (PP) + Superior Constrictor (PP > SC).

Structures seen in oropharynx :

In it's lateral wall : Tonsil.

Tonsil :

- m/c source of bleeding post-tonsillectomy : **Paratonsillar vein**.
- Peritonsillar space infection : **Quinsy**.
- Bed of tonsil : Superior constrictor muscle.
- Glossopharyngeal nerve (CN 9) supplies tonsil and middle ear (Referred pain to middle ear).



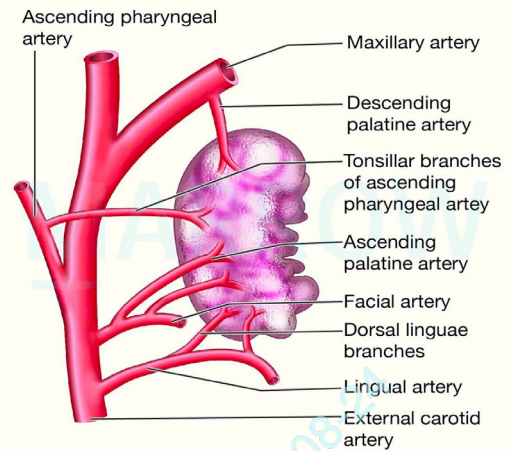
- | | |
|--------------------------------|--|
| 1 Capsule | 2 Loose areolar tissue containing paratonsillar vein |
| 3 Superior constrictor muscle | 4 Styloglossus |
| 5 Glossopharyngeal nerve | 6 Facial artery |
| 7 Medial pterygoid muscle | 8 Angle of mandible |
| 9 Submandibular salivary gland | 10 Pharyngobasilar fascia |
| 11 Buccopharyngeal fascia | |

Relations of the tonsil.

----- Active space -----

Blood supply of tonsil :

1. Principal artery : Facial artery.
2. maxillary artery.
3. Tonsillar branches of ascending pharyngeal artery.
4. Ascending palatine artery.
5. Lingual artery.



Blood supply of tonsil

Hypopharynx :

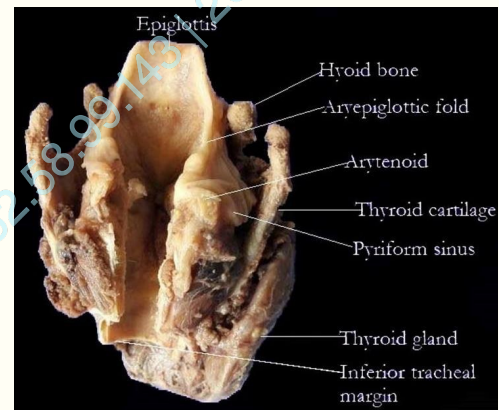
Piriform fossa :

Boundaries :

- medially → Aryepiglottic fold
- Laterally → thyroid cartilage.

Significance :

- Internal laryngeal nerve (ILN) present → Site for ILN block.
- Foreign body entrapment.



Piriform fossa

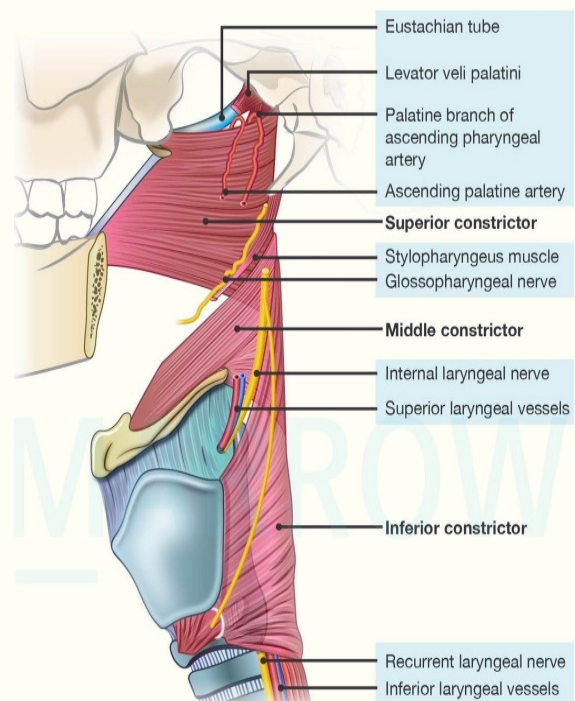
muscles of pharynx :

1. Constrictors : Superior, middle & inferior.
2. Palatopharyngeus.
3. Stylopharyngeus.
4. Salpingopharyngeus.

Nerve supply :

- 1, 2, 4 (From above) → Pharyngeal plexus.
- 3 → Glossopharyngeal nerve.

Triangular gap b/w thyropharyngeus and cricopharyngeus is Killian's dehiscence.



Larynx

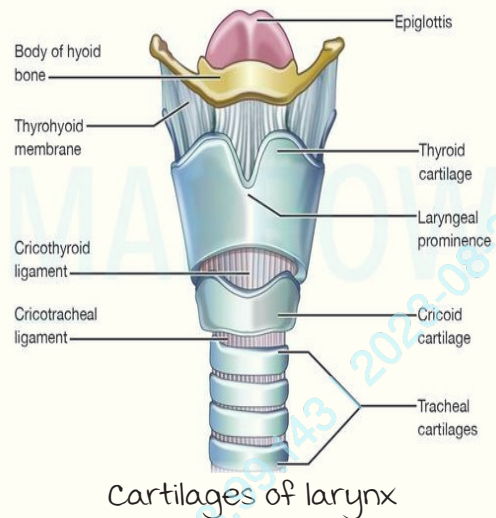
00:33:25

----- Active space -----

Cartilaginous tube extending from C3 to C6.

Unpaired cartilage	Paired cartilage
Thyroid	Arytenoid
Cricoid	Corniculate
Epiglottis	Cuneiform

Hyaline cartilage	Elastic cartilage
Thyroid	Epiglottis
Cricoid	Corniculate
Arytenoid	Cuneiform
	Apex of arytenoid



Coronal section of larynx :

Vestibular ligament : Thickening of lower part of quadrangular membrane.

Vocal ligament/true vocal cord : Thickening of upper part of cricovocal membrane.

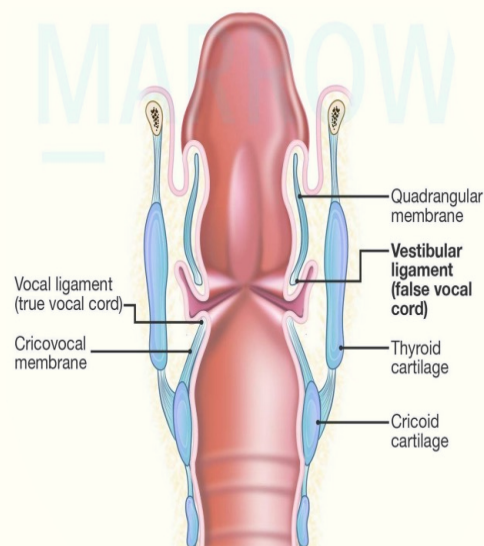
Parts of larynx :

- Supraglottis : B/w laryngeal inlet & vestibular fold.
- Glottis : B/w vestibular ligament & vocal fold.
- Infraglottis/subglottis : Below vocal ligament.

Carcinoma of larynx is m/c seen in glottis.

Ca glottis : Good prognosis (No lymphatics & early presentation).

Ca supra glottis & sub glottis : Lymphatic metastasis is common (Rich in lymphatics).



----- Active space -----

muscles of larynx :

muscle	Action
Transverse arytenoid Lateral cricoarytenoid	Adductor of larynx.
Posterior cricoarytenoid	Only abductor of larynx (Safety muscle of larynx).
Cricothyroid	Tensor of larynx > adductor.
Thyroarytenoid	Relaxer.
Thyroepiglotticus	Opens the inlet.
Aryepiglotticus	Closes the inlet.

Nerve supply of larynx :**Sensory :**

- Above vocal cord : Internal laryngeal nerve.
- Below vocal cord : Recurrent laryngeal nerve (RLN).

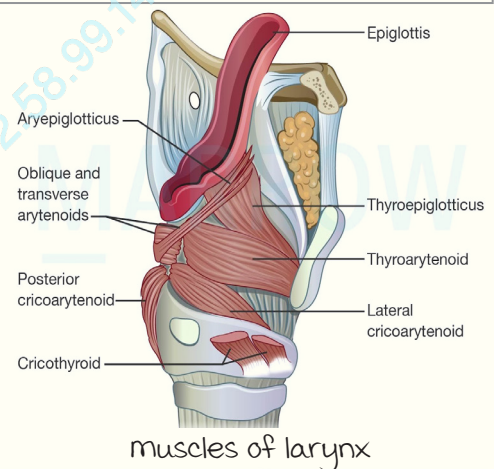
motor :

- All muscle except cricothyroid : RLN.
- Cricothyroid : External laryngeal nerve (ELN).

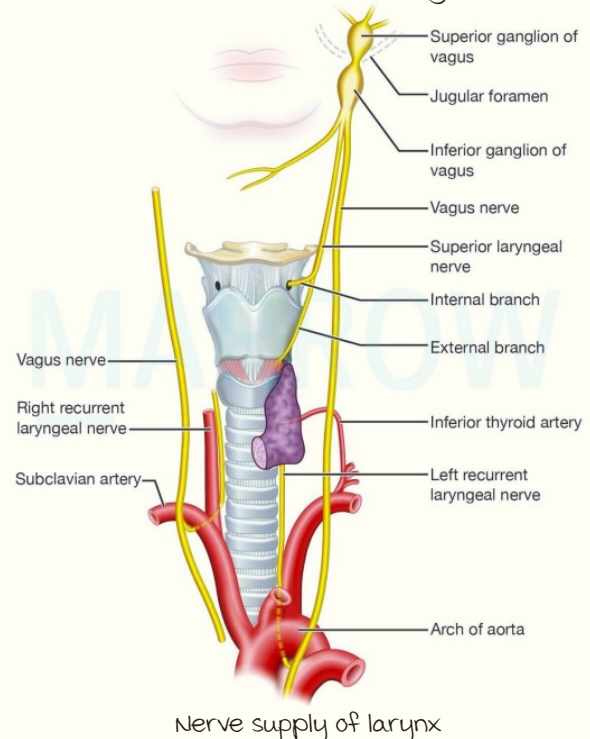
ELN : Accompanies superior thyroid artery.

Recurrent laryngeal nerve (RLN) :

- Right RLN : Arises at the level of right subclavian artery.
- Left RLN : Arises at the level of arch of aorta.
Longest course.
more commonly injured.
- Accompanies inferior thyroid artery (Affected in tracheoesophageal groove).



muscles of larynx



Nerve supply of larynx

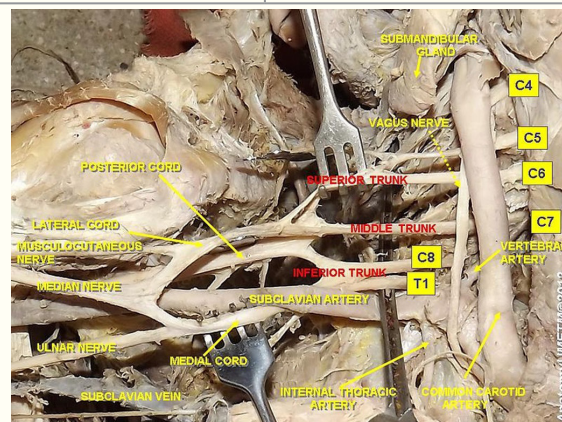
ANATOMY REVISION 5

----- Active space -----

Brachial plexus

00:00:14

		Branches
Roots	C5, C6, C7, C8, T1	<ul style="list-style-type: none"> Dorsal scapular nerve (C5) : Rhomboid minor, Rhomboid major, Levator scapulae. Long thoracic nerve (C5, C6, C7) : Serratus anterior
Trunk	Upper trunk : C5, C6	<ul style="list-style-type: none"> Nerve to subclavius (C5, C6). Supra scapular nerve (C5, C6) : Supraspinatus & Infraspinatus muscle.
	Middle trunk : C7	
	Lower trunk : C8, T1	
Divisions	Each trunk is divided into anterior & posterior division	Do not give any branches.
Cord	Lateral cord : Anterior division of upper & middle trunk	<ul style="list-style-type: none"> Musculocutaneous nerve : Anterior compartment of arm. Lateral pectoral nerve : Pectoralis major, pectoralis minor. Lateral root of median nerve.
	Medial cord : Anterior division of lower trunk	<ul style="list-style-type: none"> Medial pectoral nerve. Medial cutaneous nerve of arm. Medial cutaneous nerve of forearm. Ulnar nerve. Medial root of median nerve.
	Posterior cord : Posterior division of all trunks	<ul style="list-style-type: none"> Upper subscapular nerve : Upper part of subscapularis. Lower subscapular nerve : Lower part of subscapularis, Teres major. Nerve to latissimus dorsi. Axillary nerve : Deltoid, Teres minor. Radial nerve.



----- Active space -----

Musculocutaneous & Axillary Nerve Injuries :

Musculocutaneous N. Injury :

Loss of

1. Elbow flexion

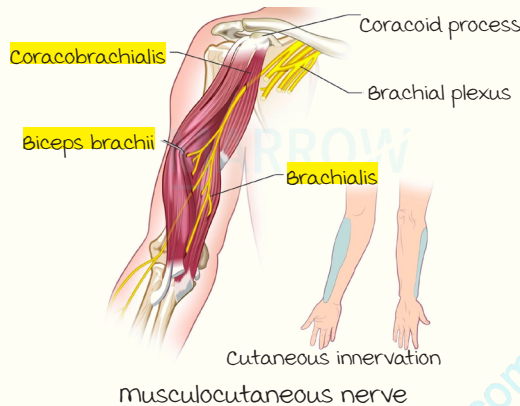
(Biceps brachii, brachialis).

2. Supination

(Biceps brachii).

3. Sensation in lateral

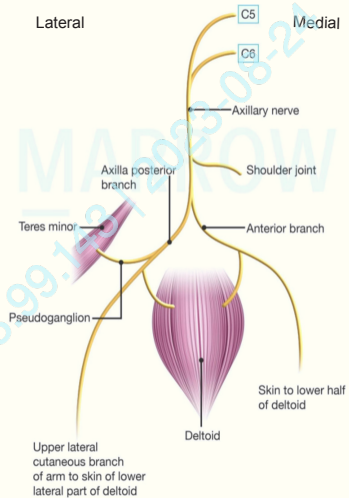
aspect of forearm.



Axillary N. Injury :

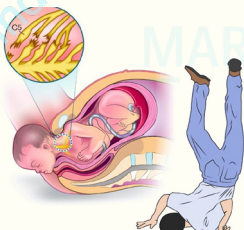


- Causes : Fracture of surgical neck of humerus, dislocation of shoulder joint, palsy of deltoid, teres minor.

- C/F : Regimental badge area anaesthesia (Sensory loss in upper lateral aspect of arm).



Axillary nerve

Erb's palsy vs Klumpke's palsy :

Erb's palsy	Klumpke's palsy
Upper trunk injury (C5, C6).	Lower trunk injury (C8, T1).
D/t injury at Erb's point : Falling on their shoulder. 	D/t hyperabduction injury. 
Nerves affected : <ul style="list-style-type: none"> • Musculocutaneous nerve. • Axillary nerve. • Suprascapular nerve. 	Nerves affected : C8, T1 of ulnar & median nerve affected (supply small muscles of hand).
Deformity : Policemen's tip deformity. <ul style="list-style-type: none"> • Shoulder joint : Adducted & medially rotated. • Elbow : Extended. • Forearm : Pronated. 	Deformity : Complete claw hand > Horner's syndrome.

Note : Cutaneous branches of brachial plexus.

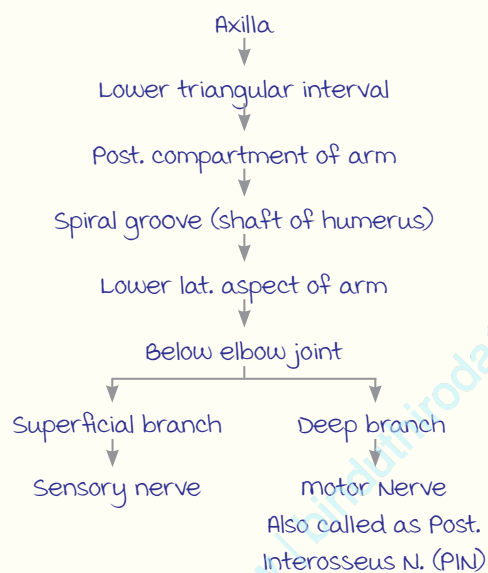----- Active space -----

Nerve	Branch of
medial cutaneous nerve of arm	medial cord of brachial plexus
medial cutaneous nerve of forearm	
upper lateral cutaneous nerve of arm	Axillary nerve
Lower lateral cutaneous nerve of arm	Radial nerve
Posterior cutaneous nerve of arm	Radial nerve
Lateral cutaneous nerve of forearm	musculocutaneous nerve

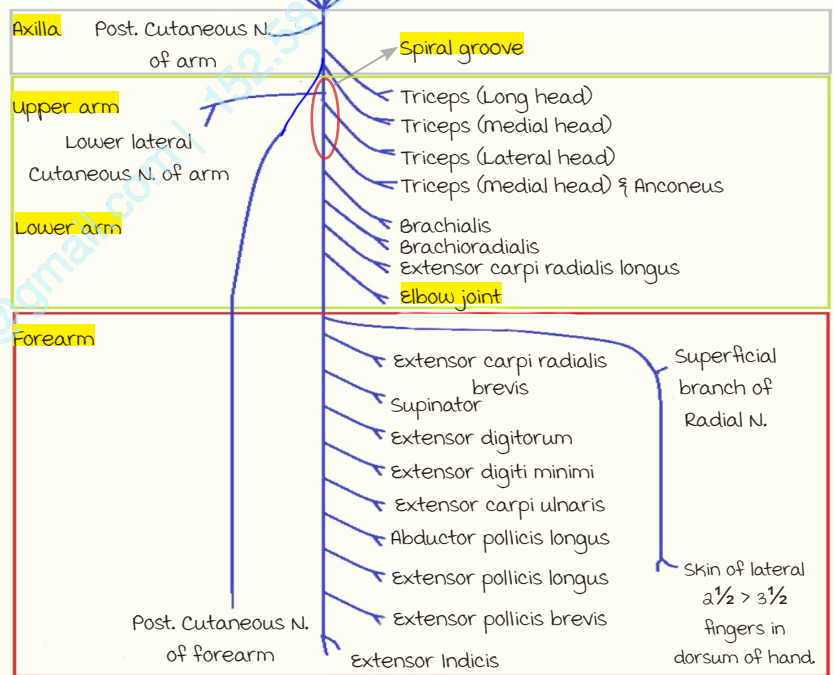
Radial Nerve :

00:08:31

Course :



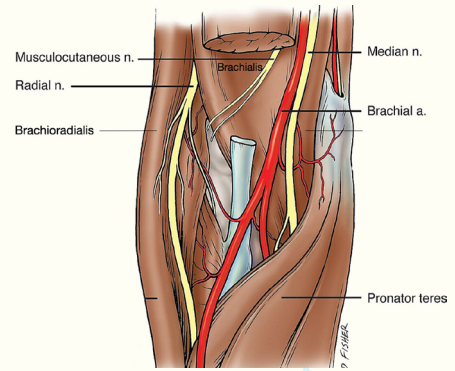
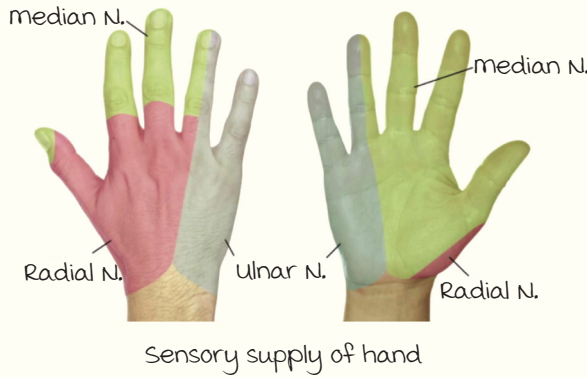RADIAL NERVE (C5, C6, C7, C8, T1) mixed nerve + Largest nerve of brachial plexus.



Applied aspect :

- Holstein Lewis # :** # shaft of humerus with radial nerve involvement.
- Crutch palsy :** Compression of radial nerve in the axilla.
- PIN palsy :**
 - Extension of elbow intact as triceps (Radial N) is unaffected.
 - Extension of wrist intact as ECRL (Radial N) is unaffected.
 - Finger drop d/t loss of extension of MCP.
 - No sensory loss (PIN is pure motor nerve).

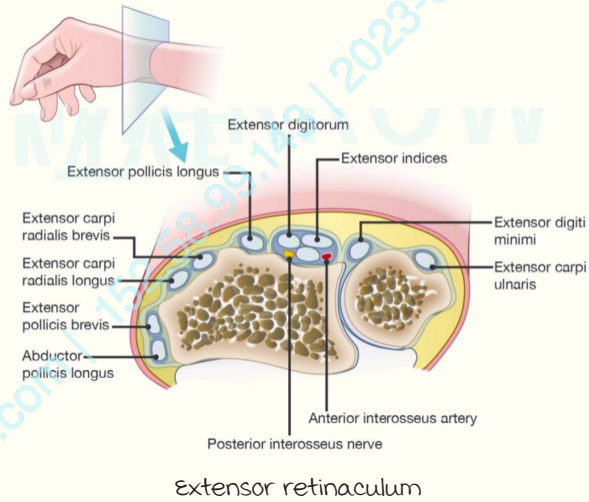
----- Active space -----



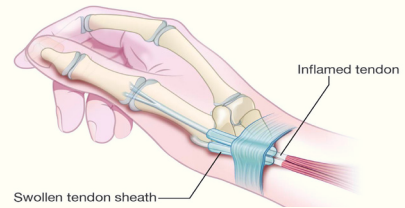
Extensor retinaculum :

6 compartments (Lateral to medial) :

1st	Abductor pollicis longus, Extensor pollicis brevis.
2nd	ECRL, ECRB.
3rd	Extensor pollicis longus.
4th	Extensor digitorum, Extensor indices, Posterior interosseous nerve.
5th	Extensor digiti minimi.
6th	Extensor carpi ulnaris.



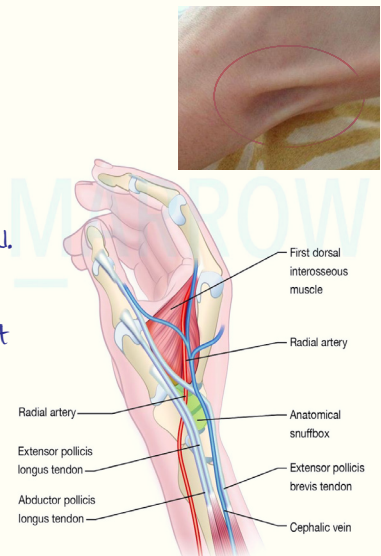
Applied aspect : De Quervain's tendinitis
Synovitis of 1st compartment tendon (AbPL, EPB).



Anatomical snuff box :

- Present b/w 1st & 3rd compartment.
- Boundaries :
Laterally : AbPL, EPB.
medially : EPL.
Roof : Cephalic vein, Superficial branch of Radial N.
Floor : Lower end of radius, Scaphoid, Trapezium, Base of 1st metacarpal & 2nd compartment tendons (ECRL, ECRB).
- Content : Radial artery.

scaphoid : Pain in anatomical snuff box.
m/c fractured carpal bone.



Median Nerve :

00:22:09

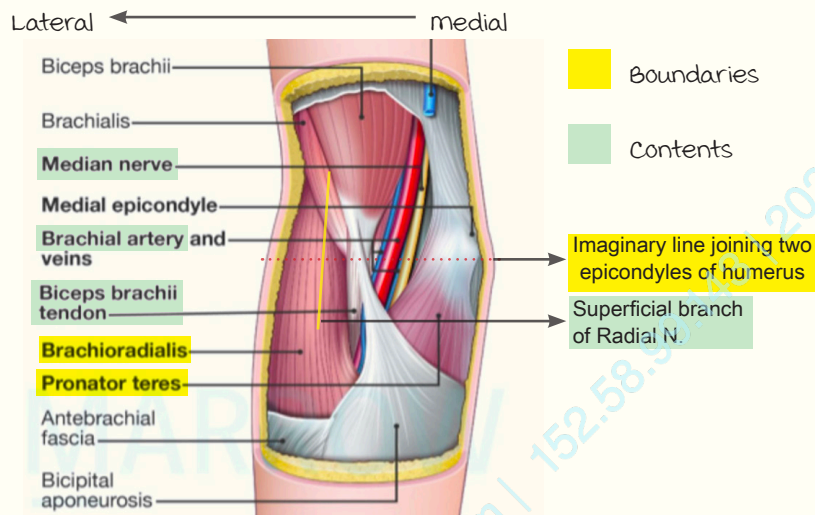
----- Active space -----

mixed nerve, Root value : C5-C8, T1.

Formed by union of medial root of median N. + lateral root of median N.

Supplies mainly long flexors of forearm → Labourer's nerve.

median nerve in Cubital fossa :



median nerve in forearm :

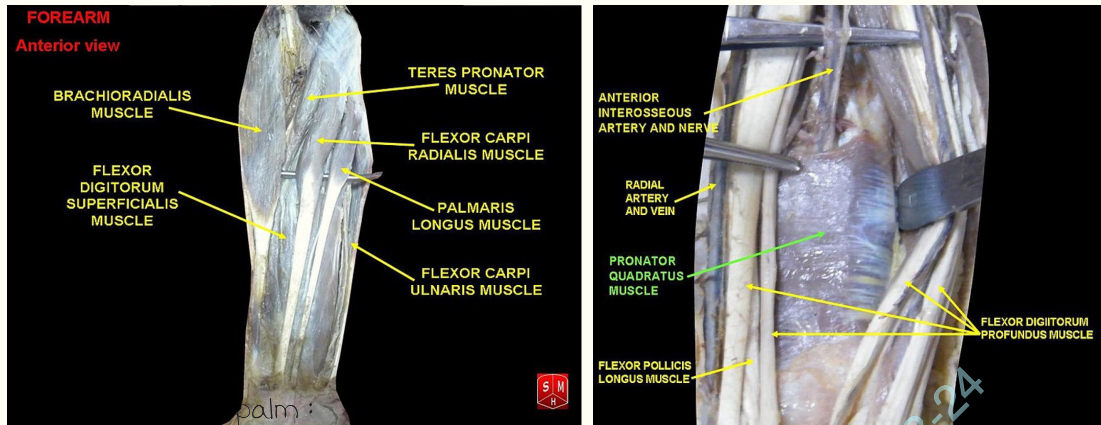
In flexor compartment of forearm, muscles are arranged in 2 layers :

Superficial layer & Deep layer.

Layer	muscles	Action	Nerve
Superficial layer	Pronator teres	Pronation	Median N.
	Flexor carpi radialis	Flexion of wrist, Radial deviation of wrist	Median N.
	Flexor carpi ulnaris	Flexion of wrist, Ulnar deviation of wrist	Ulnar N.
	Palmaris longus	Flexion of wrist	Median N.
	Flexor digitorum superficialis (upto middle phalynx)	Flexion of wrist, Flexion of MCP joint, Flexion of proximal IP joint	Median N.
Deep layer	Flexor digitorum profundus (distal phalynx) : Lateral half → Index & middle finger. medial half → Little & ring finger.	Flexion of wrist, flexion of MCP joint, Flexion of proximal & distal IP joint	Lateral half : AIN medial half : Ulnar N.
	Flexor pollicis longus	Flexion of IP jt of thumb	AIN
	Pronator quadratus	Pronation	AIN

Note : MCP → metacarpophalyngeal, IP → Interphalangeal, AIN → Ant. Interosseus N.

----- Active space -----



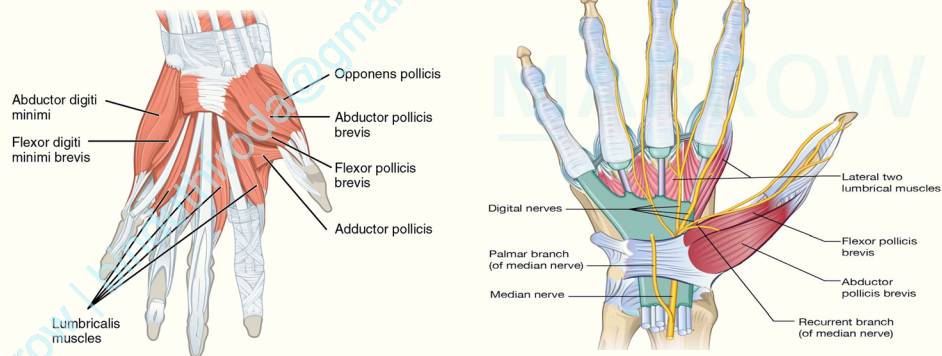
It gives recurrent branch (motor).

Then divides into medial & lateral palmar digital branches (Sensory supply to lateral $3\frac{1}{2}$ digits in palmar aspect).

muscles supplied by median nerve in palm : mnemonic **LOAF**

- Lumbricals 1, 2.
 - Opponens pollicis.
 - Abductor pollicis brevis.
 - Flexor pollicis brevis.
- } Forms thenar eminence

Note : Adductor pollicis : Not a thenar eminence muscle. It is supplied by deep br. of ulnar N.



Trunk of median N. : Passes below flexor retinaculum (FR).

Palmar br. of median N. : Passes above FR. Gives sensory supply to thenar eminence.

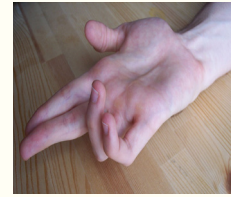Applied aspect :

Carpal tunnel syndrome :

- Compression of median nerve below the FR.
- Thenar eminence atrophy.
- Loss of sensory supply over lateral $3\frac{1}{2}$ digits in palmar aspect.
- Sensory supply over the thenar eminence remains intact.

Hand of benediction :

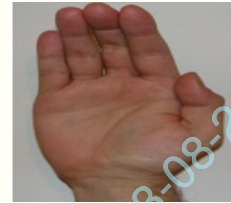- median N. injury.
- D/t involvement of lateral half of FDP tendon.
- Inability to flex IP joint of index & middle fingers.
- FDP medial half (Supplied by ulnar N.) is normal.



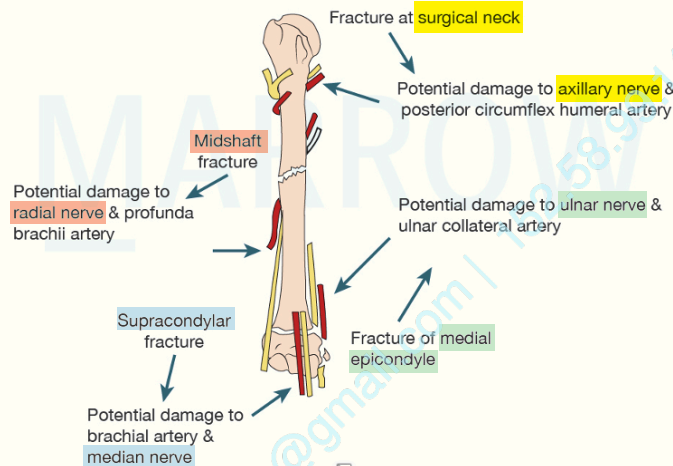
----- Active space -----

Ape thumb deformity :

- median N. injury.
- D/t Thenar eminence atrophy.
- Inability to oppose thumb.



Note :



Arteries & Nerves liable to damage at 4 sites of # of Humerus

Ulnar Nerve :

Root value : C7, C8, T1.

mainly supplies palm muscles → musician's nerve.

Course :

Ulnar N. passes behind medial epicondyle of humerus.

Ulnar N. in forearm : Supplies FCU & medial half of FDP.

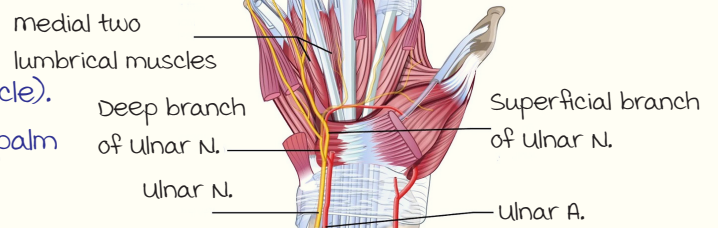
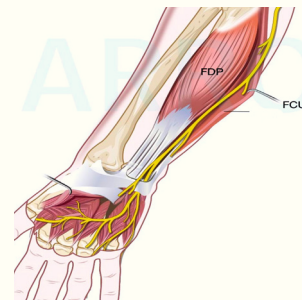
Ulnar N. in palm : Passes above FR & enters palm.

Passes in Guyon's canal (Contents : Ulnar N. & ulnar artery).

In the palm :

- Superficial branch : mainly sensory, motor to palmaris brevis (subcutaneous muscle).
- Deep branch : motor supply to all muscles of palm except LOAF muscles.

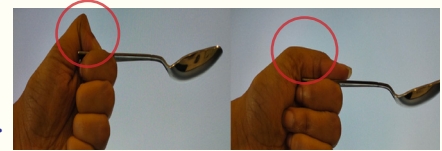00:38:06



----- Active space -----

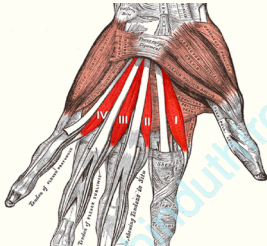
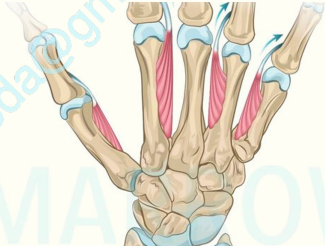
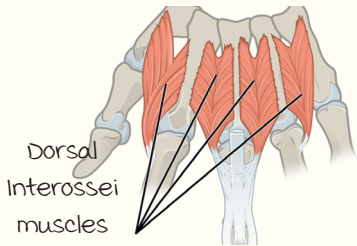
Applied aspect : **Froment sign**

Compensatory flexion of IP joint of thumb.

Adductor pollicis muscle palsy d/t ulnar N. injury.

Froment's +ve Adductor pollicis normal

Lumbricals, Palmar and Dorsal Interossei :

Lumbricals	Palmar interosseus	Dorsal interosseus
4 - Lateral to medial : • 1, 2 : Unipinnate. • 3, 4 : Bipinnate.	4 - Lateral to medial : Unipinnate.	4 - Lateral to medial : Bipinnate.
1, 2 - median nerve. 3, 4 - ulnar nerve.	Deep br. of ulnar nerve.	Deep br. of ulnar nerve.
Origin : FDP tendon. Insertion : DDE.	Insertion : DDE (Dorsal digital expansion)	Insertion : DDE
Action : • Flexion of MCP jt. • Extension of IP jt.	Action : • Flexion of MCP jt. • Extension of IP jt. • Adduction of fingers (PAD).	Action : • Flexion of MCP jt. • Extension of IP jt. • Abduction of fingers (DAB).
Aka link muscle .	Middle finger does not have attachment of palmar interosseus.	Little finger & thumb do not have attachment of dorsal interosseus. Abductors of little finger : Abductor digiti minimi. Abductors of thumb : AbPL, AbPB.
		

Vessels of upper limb

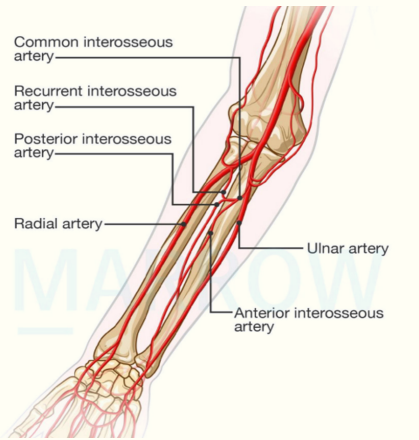
00:47:47

Axillary A. : From upper border of 1st rib to lower border of teres major.

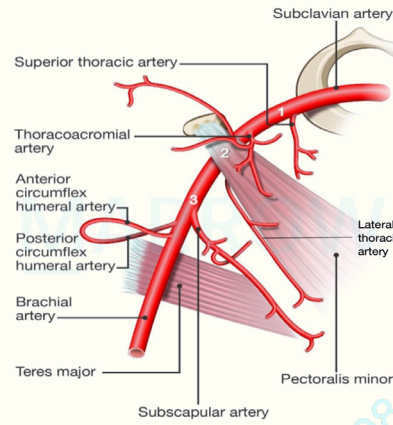
Divided into 3 parts by Pectoralis minor

1 st part	Superior thoracic A.
2 nd part	Thoraco acromial A.
	Lateral thoracic A.
3 rd part	Subscapular A (Gives circumflex scapular A & continues as Thoraco dorsal A).
	Antr. circumflex humeral A.
	Postr. circumflex humeral A.

----- Active space -----



Axillary A. course



Parts of Axillary A.

Axillary artery continues as brachial artery.

At Neck of radius : Brachial A. divides into

Ulnar A. & Radial A.

They supply forearm & palm.

Applied aspect :

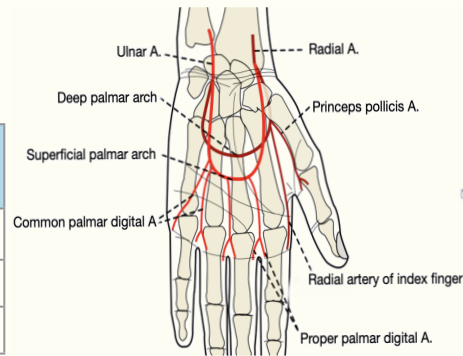
Supracondylar fracture of humerus :

- m/c affected nerve : AIN > median nerve.
- m/c affected artery : Brachial artery (Can lead to **volkmann's ischemic contracture**).

Scapular anastomosis :
Formed between 1st part of Subclavian A. & 3rd part of Axillary A.

Superficial and Deep palmar arch :

	Superficial Palmar arch	Deep palmar arch
Cont. of	Ulnar A.	Radial A.
minor Artery	Radial A.	Ulnar A.
Allen's test : To check the patency of radial & ulnar A.		



Muscles of shoulder girdle

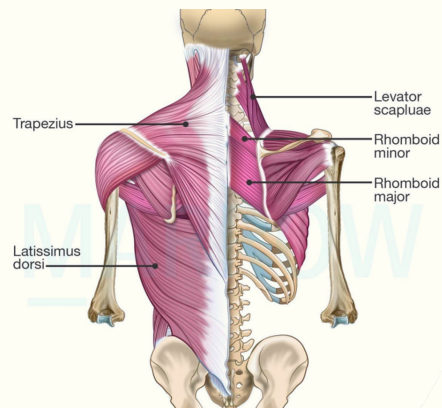
00:55:26

Trapezius :

Supplied by spinal part of accessory nerve.

Action of trapezius :

- Elevation of scapula (Along with levator scapulae).
- Retraction of scapula (Along with rhomboidus).
- Over head abduction (Along with serratus anterior).



----- Active space -----

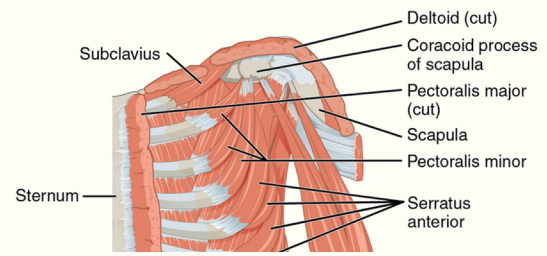
Serratus anterior :

Supplied by long thoracic N. (C5, C6, C7)

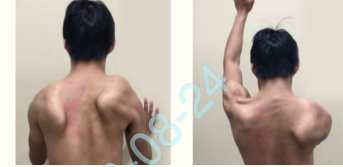Origin : upper 8 ribs.

Insertion : medial border of scapula.

Action : Protraction of scapula (Along with pectoralis minor).

**Winging of scapula :**

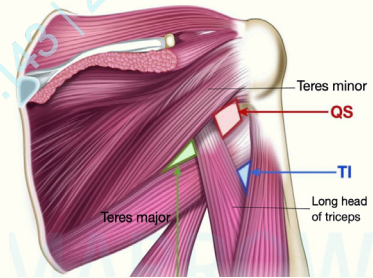
Injury to long thoracic nerve : Prominence of borders of the scapula.



Rotator cuff muscles : Supraspinatus, infraspinatus, teres minor, subscapularis.

muscles attached to greater tubercle :

- Supraspinatus : 0-15° abduction of shoulder joint.
- Infraspinatus.
- Teres minor. } Lateral rotation of shoulder



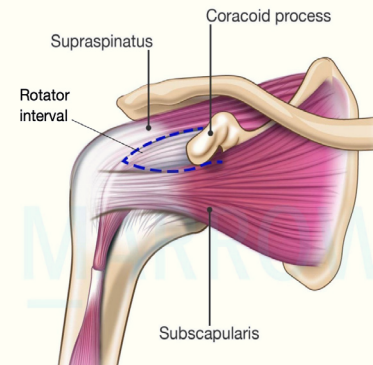
muscles attached to lesser tubercle : Subscapularis.

Subscapularis, teres major : medial rotation & adduction of shoulder joint.

Note : Teres major attachment : medial lip of intertubercular sulcus.

Abduction of shoulder joint :

- 0-15° : Supraspinatus.
- 15-90° : Deltoid.
- 90-180° : Trapezius and serratus anterior.

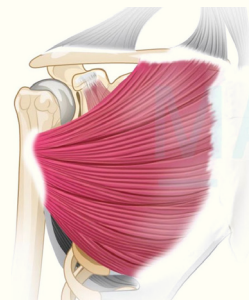
**Pectoralis major :**

Action :

- Adduction,
- medial rotation,
- Flexion of shoulder joint.

Insertion : Lateral lip of bicipital groove of the humerus.

Innervation : medial & lateral pectoral nerves.



Clavipectoral fascia : 3 structures pierce it.

- Thoracoacromial A.
- Cephalic v.
- Lateral pectoral N.]

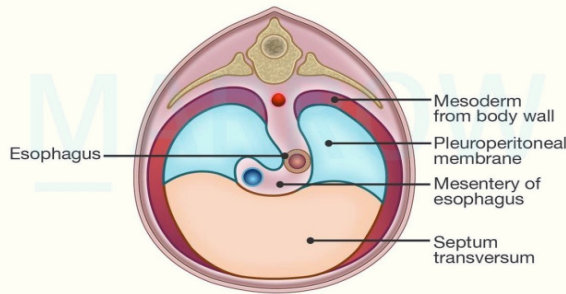
ANATOMY REVISION 6

----- Active space -----

Thorax

00:00:10

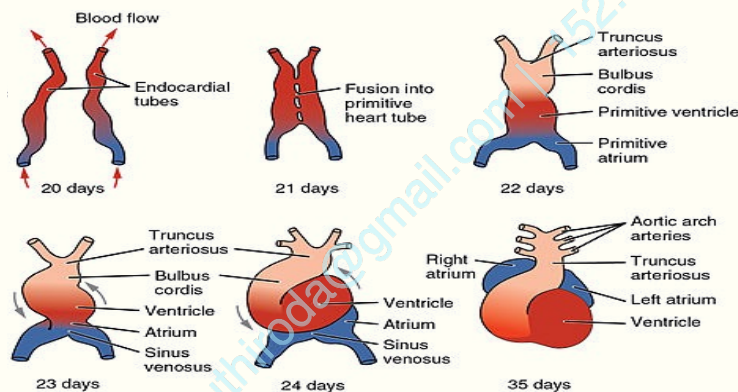
Development of diaphragm :



Congenital diaphragmatic hernia (CDH)

- mc CDH - Bochdalek hernia (defect in pleuroperitoneal membrane posterolaterally)
- more common on left > right

Development of heart :

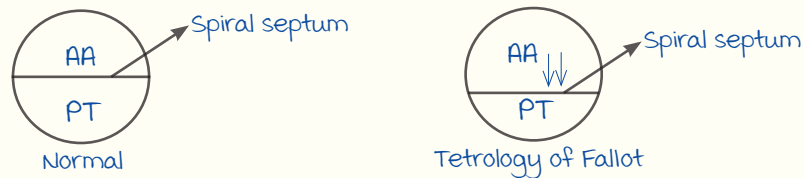

- Cardiogenic tubes formed in splanchnopleuric layer of lateral mesoderm.
- Heart beat starts on 21st day.
- Cardiac activity visible around 6-7 weeks.

Distal 1/3	Bulbus cordis	Truncus arteriosus
middle 1/3		Conus (outflow part) of both ventricles
Proximal		Trabeculated part of right ventricle
Primitive ventricle		Trabeculated part of left ventricle
Primitive atrium		Rough part of left and right atria
Sinus venosus body and right horn		Smooth part of right atrium
Left horn regress to form		Coronary sinus

- Conotruncal septum/Spiral septum :
 - a. Develops from neural crest cells.
 - b. Divides truncus arteriosus into pulmonary trunk & aorta.

----- Active space -----



- Tetralogy of Fallot : Anterior displacement of conotruncal septum.
- Transposition of great vessels : Non spiral course of conotruncal septum.
- Persistent truncus arteriosus : NCC migration defect.

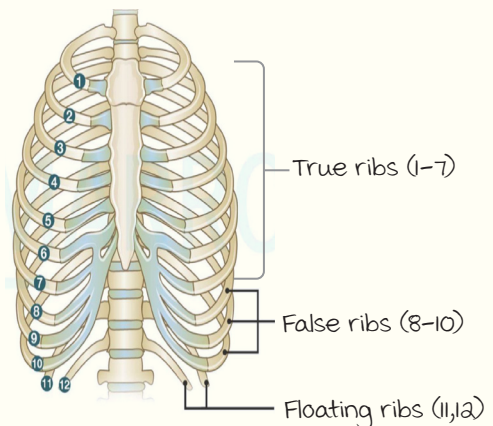
Pharyngeal arch arteries :

00:09:09

1 st arch	maxillary artery
2 nd arch	Stapedial & hyoid artery
3 rd arch	CCA, ECA, ICA
4 th arch	Rt : Rt subclavian artery Lt : Arch of aorta
6 th arch	Proximal (Rt & Lt) : Pulmonary artery Distal (Lt) : Ductus arteriosus

Thoracic cage :

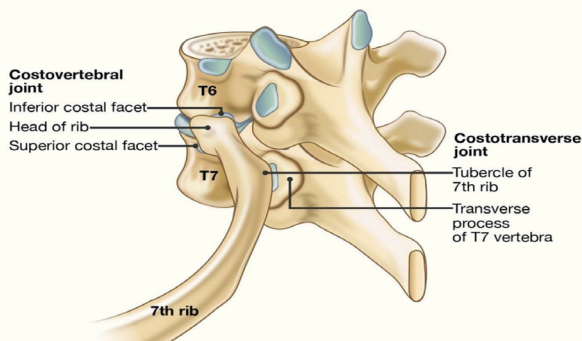
Sterno clavicular joint	Saddle
manubriosternal, xiphisternal	Symphysis (2 ^o cartilagenous)
Costochondral	Synchondrosis (1 ^o cartilagenous)
1st sternocostal	Fibrous
Sternocostal, Interchondral, Costovertebral, Costotransverse	Plane (synovial)

**Blood supply**

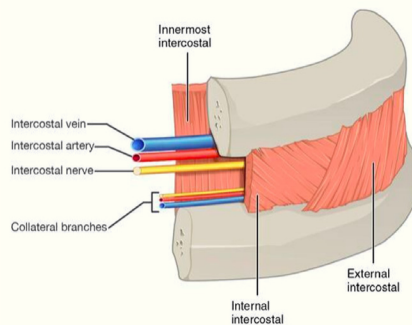
00:13:20

- Costal groove is present in all ribs except first rib.
- Neurovascular plane b/w internal and innermost intercostal.

----- Active space -----



Costo vertebral joint



Intercostal space

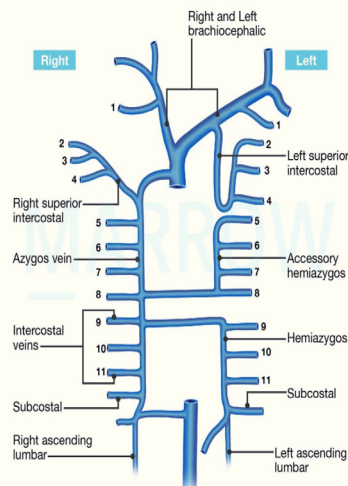
Arterial supply	Arise from	
Anterior intercostal (IC) artery	First 6 spaces	Internal thoracic artery
	7, 8, 9 space	musculophrenic artery (Branch of internal thoracic artery)
Posterior IC artery	First 2 spaces	Superior IC artery (Branch of costocervical trunk)
	Remaining	Direct branches of descending thoracic aorta

	Drains into	
1	Rt brachiocephalic vein	Lt brachiocephalic vein
2	Rt superior intercostal vein → Arch of azygos	Lt superior intercostal vein
3		Lt brachiocephalic vein
4		
5-8	Azygos	Accessory hemiazygos
9-11		Hemiazygos

Structures pierced during pleural tapping

- Skin
- Superficial fascia
- Deep fascia
- Serratus anterior
- External intercostal
- Internal intercostal
- Innermost intercostal
- Endothoracic fascia
- Parietal pleura.

Pulmonary or visceral pleura (not pierced in pleural tapping).

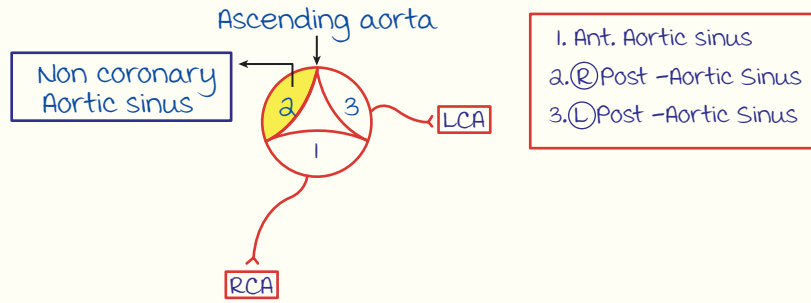


Posterior intercostal veins drainage

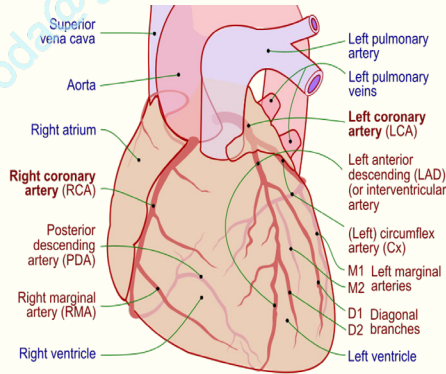
Heart

00:24:05

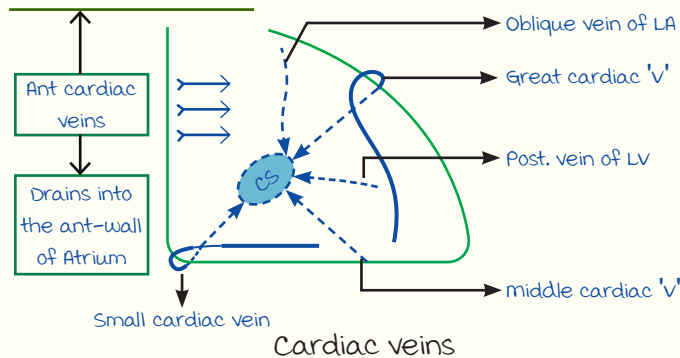
----- Active space -----



Branches of RCA	Branches of LCA
<ul style="list-style-type: none"> Right conus artery (3rd coronary artery) SA nodal artery (65%) Right anterior ventricular rami (right/acute marginal artery is a branch) Posterior interventricular artery (gives off septal branches which supply posterior 1/3rd of interventricular septum, branch to AV node) 	<ol style="list-style-type: none"> Anterior interventricular artery <ol style="list-style-type: none"> Septal branches (ant 2/3rd of interventricular septum) Diagonal artery Left circumflex artery (SA nodal artery in 35%) : gives off left marginal (obtuse) artery Posterior interventricular artery (Left dominant)



Coronary arteries

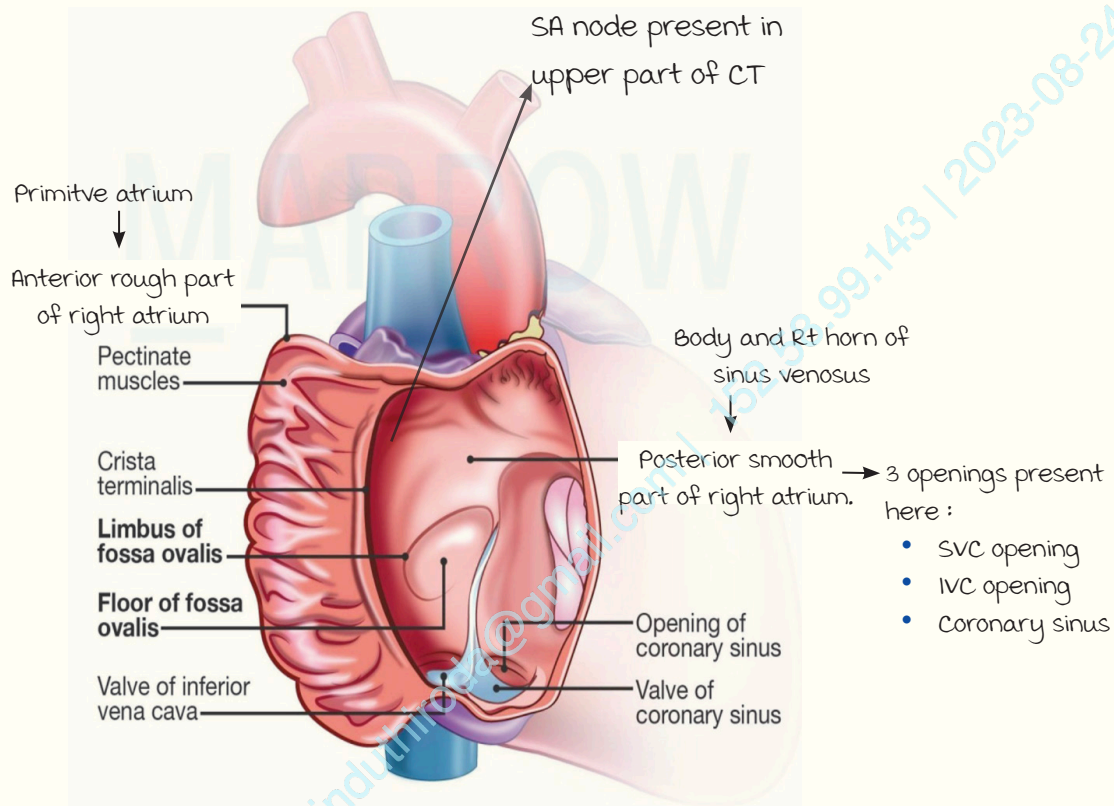


Coronary sinus :

- From left horn of sinus venosus.
- Tributaries : Great cardiac vein , middle cardiac vein, Small cardiac vein, Post vein of left ventricle, Oblique vein of left atrium.
- Anterior cardiac vein is not a tributary of coronary sinus, drains directly into RA.

----- Active space -----

Interior of right atrium :



- Fossa ovalis : Derived from septum primum.
 - Limbus of fossa ovalis : Derived from septum secundum.
 - Triangle of Koch : (location of AV node)
 - a. Base of tricuspid leaflet.
 - b. Opening of coronary sinus.
 - c. Tendon of Todaro.
- } Forms interatrial septum

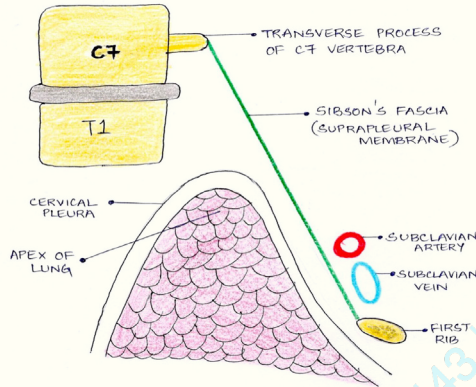
Pleura

00:40:27

- Suprapleural membrane/ Sibson's fascia : Degenerated scalenus medius.
- Costomediastinal line of reflection from stenooclavicular jn to 4th costal cartilage
 - a. Rt : upto xiphisternal joint.
 - b. Lt : Deviate line 1.5mm and reach 6th costal cartilage.

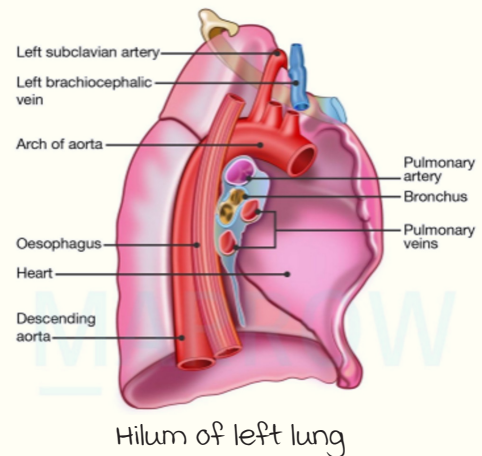
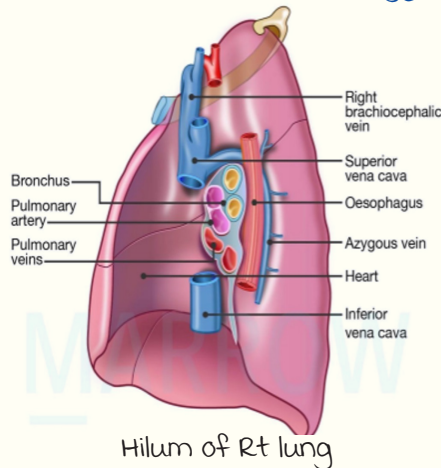
----- Active space -----

- Costodiaphragmatic line of reflection :
 - a. Rt : Start from 7th costal cartilage
 - b. Lt : Start from 6th costal cartilage
- 8th rib in mCL → 10th rib in MAL → 12th rib in scapular line



Sibson's fascia

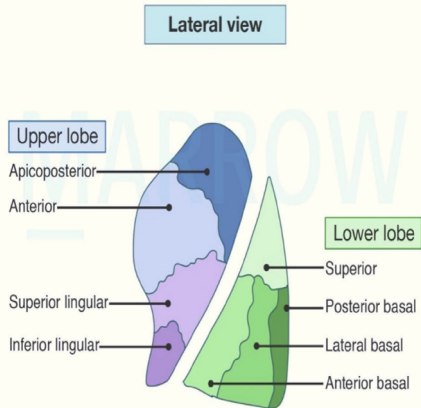
	Arrangement of structures at hilum of right lung	Arrangement of structures at hilum of left lung
From above downwards	Eparterial bronchus Pulmonary artery Hyparterial bronchus Lower pulmonary vein	Pulmonary artery Hyparterial bronchus Lower pulmonary vein
From anterior to posterior	Pulmonary vein Pulmonary artery Bronchus Bronchial vessels	
In front	Phrenic nerve	
Behind	Vagus nerve	
Above hilum	Arch of azygos vein	Arch of aorta



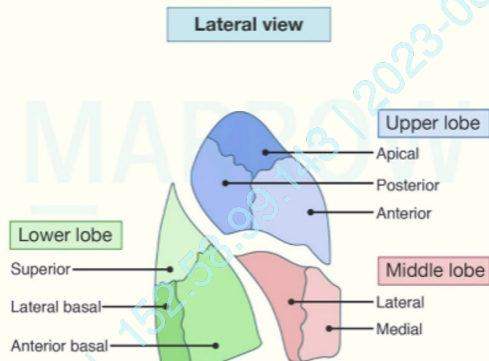
Bronchopulmonary segments :

----- Active space -----

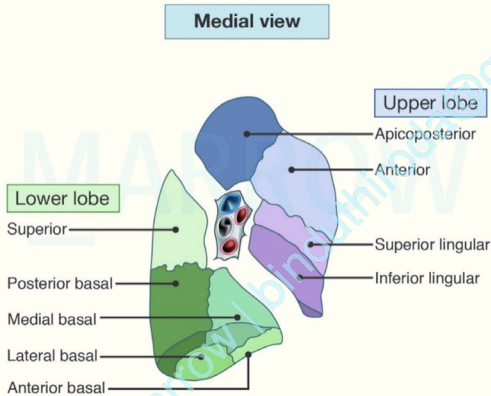
- Segments aerated by tertiary bronchus or segmental bronchus.
- Intersegmental : Pulmonary vein.
- Intra segmental : Pulmonary artery.
- Rt bronchus more vertical than Lt : Increased risk of foreign body aspiration in Rt lung.
- In standing position : Posterobasal lower lobe of right lung dependent
- In supine position : Apical segment of lower lobe of right lung dependent



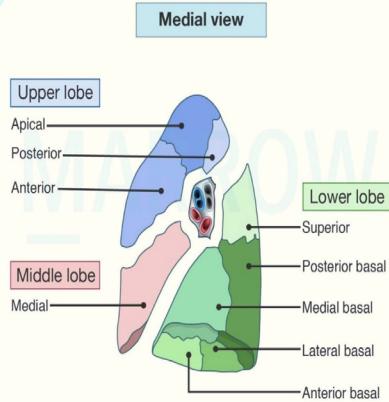
Lateral view



Lateral view



Medial view



Medial view

Bronchopulmonary segments (Lt)

Bronchopulmonary segments (Rt)

Constrictions of esophagus

00:55:55

	Site	Due to	Distance from incisor
1 st	C6	Cricopharyngeal junction	6 inch
2 nd	T4	Arch of aorta	9 inch
3 rd	T6	Left bronchus	11 inch
4 th	T10	Esophageal opening in diaphragm	15 inch

----- Active space -----

Blood supply of esophagus :

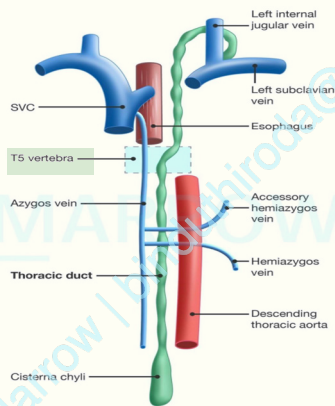
Cervical part	Inf thyroid artery	Inf thyroid vein
Thoracic part	Bronchial artery Descending thoracic aorta	Azygos vein
Abdominal part	Lt gastric artery	Azygos vein Portal vein Lt gastric vein

- Abdominal part is a site of porto caval anastomosis.

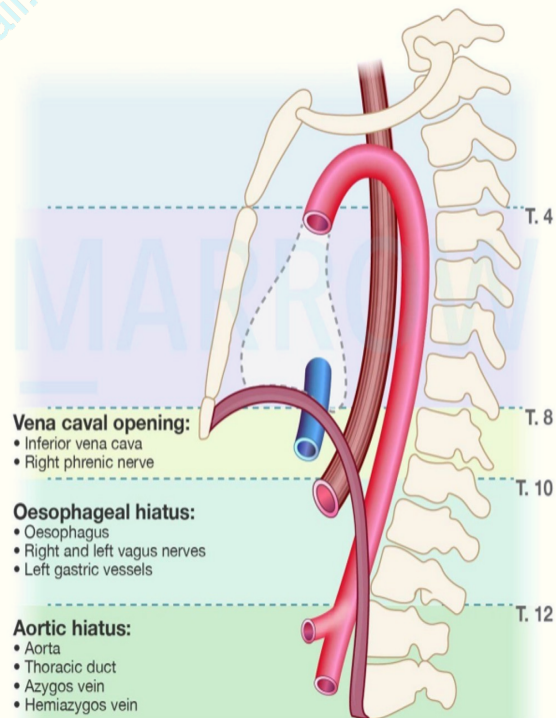
Thoracic duct :

00:58:49

- Largest lymphatic vessel.
- Drains the entire body except : Right head and neck, right thoracic wall, right upper limb, right lung, right surface of heart, convex part of liver.
- At T5 cross from right to left side.
- At C7 terminate into angle between left internal jugular vein and left subclavian vein.



Course of thoracic duct



Structures passing through diaphragmatic apertures

ANATOMY REVISION 7

----- Active space -----

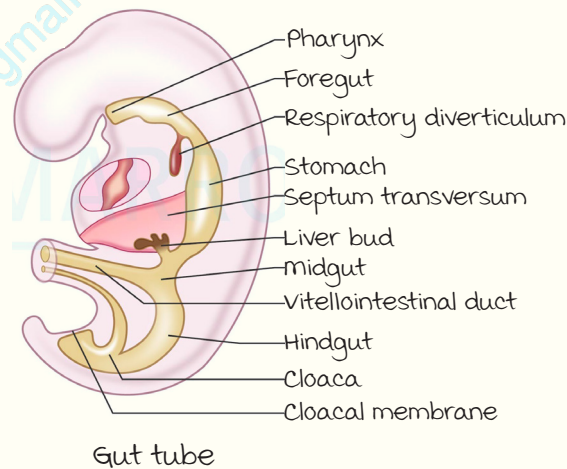
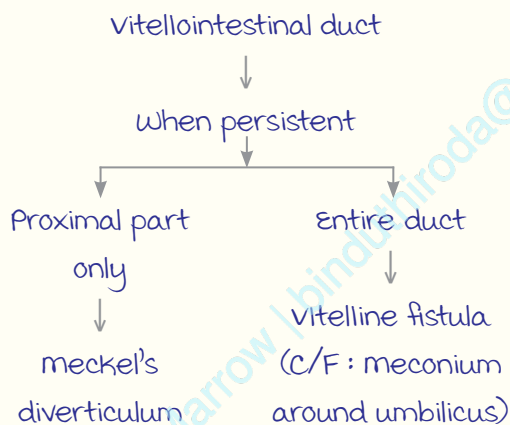
Embryology of Abdomen

00:00:12

Epithelium of gut tube : Endoderm.

Part of gut tube	Arterial supply	Sympathetic supply (Pain fibres)	Parasympathetic supply
Foregut	Celiac	T5-T9	Vagus nerve.
midgut	Superior mesenteric	T10-T11	
Hindgut	Inferior mesenteric	T12-L2	Pelvic splanchnic nerve/ Nervi erigentes.

- Diverticulum in hindgut : **Allantois**.
- Part of hindgut distal to allantois : **Cloaca**.
- Physiological hernia (midgut contents herniate into yolk sac) occurs by **6th week** through vitellointestinal/vitelline duct.



Development of pancreas :

Ventral & dorsal pancreatic buds arise from foregut. As stomach rotates clockwise, C-shaped duodenum comes to lie on the right side.

Ventral bud rotates to lie below dorsal bud.

- Ventral bud → Lower part of head & uncinete process.
- Dorsal bud → Rest of pancreas.



----- Active space -----

main pancreatic duct : Distal part of dorsal duct + whole of ventral duct.

minor pancreatic duct : Proximal part of dorsal duct.

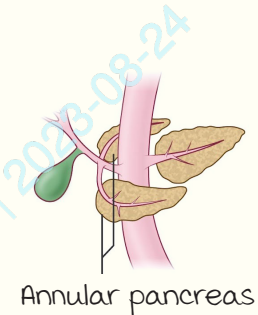
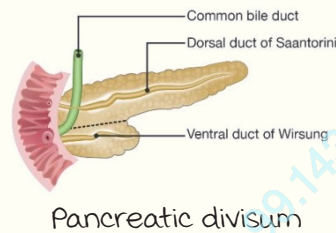
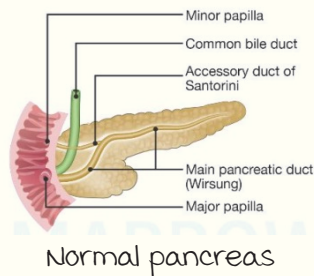
Anomalies in pancreas :

Pancreas divisum :

- Pancreas is divided.
- Ducts remain separated.

Annular pancreas :

- Bilobed ventral bud.
- Ring of pancreatic tissue around duodenum.



Inguinal Region

00:07:23

Inguinal ligament

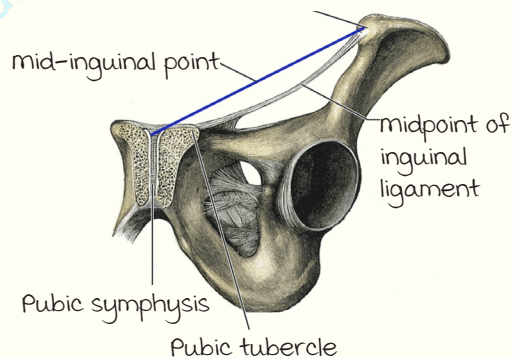
Thickening of external oblique aponeurosis.

Extent : From Anterior Superior Iliac Spine (ASIS) to pubic tubercle.

midpoint of inguinal ligament : midpoint of line b/w ASIS & pubic tubercle.

mid-inguinal point : midpoint of imaginary line b/w ASIS & pubic symphysis.

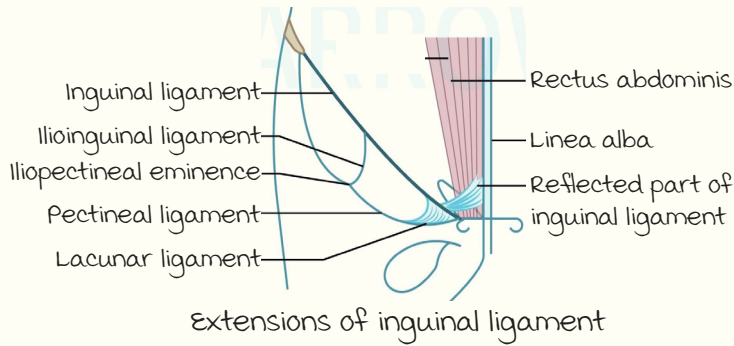
Deep inguinal ring is present 1.25 cm above mid-inguinal point.



Extensions of inguinal ligament :

1. Reflected part of Inguinal ligament : Inguinal ligament to linea alba.
2. Pectineal ligament : Pubic tubercle to pectinate line.
3. Lacunar ligament.

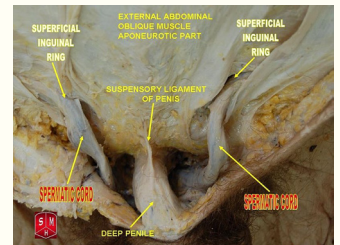
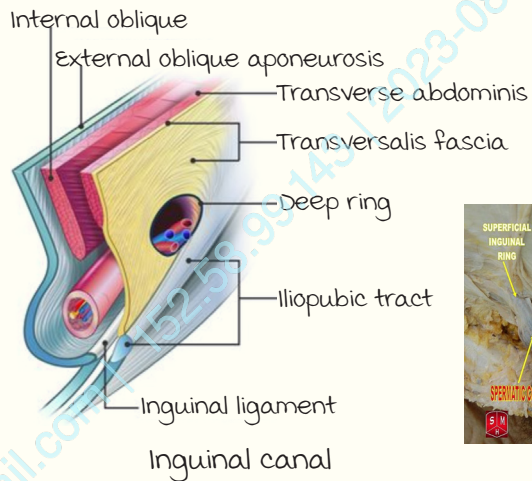
----- Active space -----



Inguinal canal :

Intermuscular canal in anterior abdominal wall.

- True contents (Enter through deep ring & exit through superficial ring) :
 - a. male : Spermatic cord.
 - b. Female : Round ligament of uterus.
- False content (Does not enter canal through deep ring) : Ilioinguinal nerve.



Boundaries of inguinal canal :

Boundary	Structure	Features
Inlet	Deep ring	Defect in fascia transversalis. Located 1.25 cm above mid-inguinal point.
Outlet	Superficial ring	Located above & medial to pubic tubercle.
Anterior wall	External oblique	Strengthened laterally by internal oblique.
Posterior wall	Fascia transversalis	Strengthened medially by conjoint tendon.
Roof	Internal oblique & transverse abdominis	-
Floor	Inguinal ligament	-

Note :

- Conjoint tendon is formed by internal oblique & transverse abdominis.
- Femoral ring situated below & lateral to pubic tubercle.

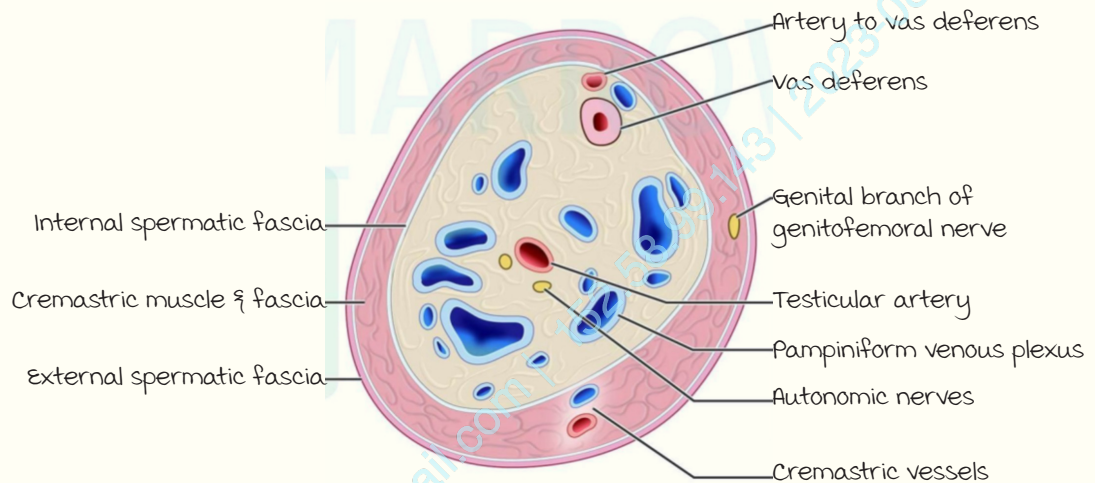
----- Active space -----

Spermatic cord :

Coverings of spermatic cord :

Covering	Derived from
External spermatic fascia	External oblique
Cremastric muscle & fascia	Internal oblique
Internal spermatic fascia	Fascia transversalis

Contents of spermatic cord :

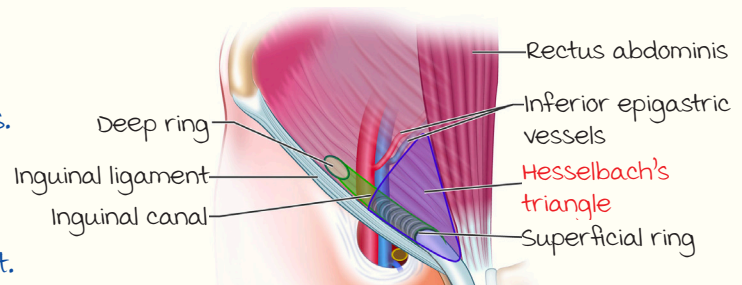


Contents of spermatic cord

Hesselbach's triangle :

Boundaries :

- medial : Rectus abdominis.
- Lateral : Inferior epigastric artery.
- Inferior : Inguinal ligament.



Hesselbach's triangle

Conjoint tendon passes anteriorly to Hesselbach's triangle.

Weakness of conjoint tendon causes Direct Inguinal Hernia

Liver

00:18:56

Liver divided into 8 Couinaud segments by Portal vein >> Hepatic vein (Using 3 major & minor fissures).

Identification of fissures :

Portal vein > Hepatic vein > Bile duct > Hepatic artery (Least important).

major fissures :

Cantlie's line : Line drawn from fossa of gall bladder to groove of IVC.

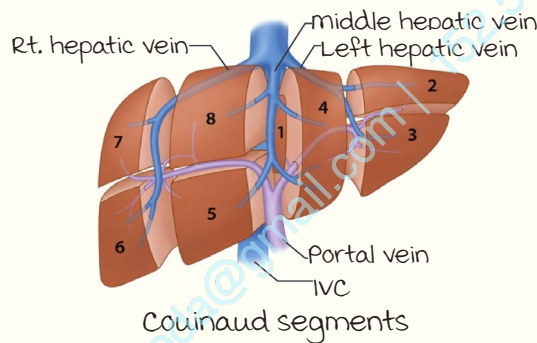
Functional right lobe : Divided into two segments by right fissure.

Functional left lobe : Divided into two segments by left fissure.

----- Active space -----

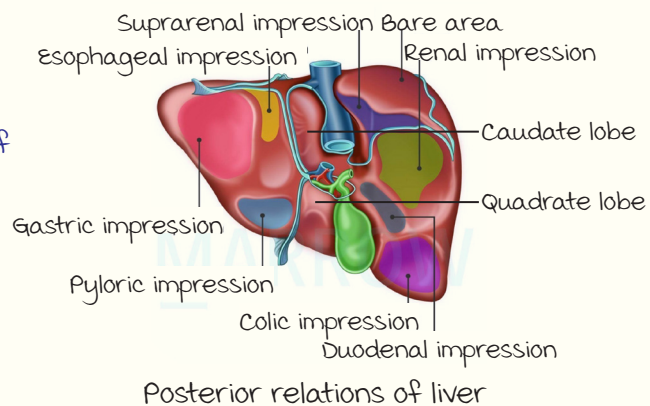
	Right functional lobe	Left functional lobe
Arterial supply	Rt. branch of portal vein & Rt. hepatic artery.	Lt. branch of portal vein & Lt. hepatic artery.
Venous drainage	Rt. hepatic vein.	Lt. hepatic vein.
Biliary drainage	Rt. hepatic duct.	Lt. hepatic duct.
Lobes	5 : Rt. anterior inferior. 6 : Rt. posterior superior. 7 : Rt. posterior inferior. 8 : Rt. anterior superior.	2 : Lt. lateral superior. 3 : Lt. lateral inferior. 4a : Lt. medial superior. 4b : Lt. medial inferior.

Note : Lt. lateral & Lt. medial segments are divided by falciform ligament.



Caudate lobe (Segment 1) :

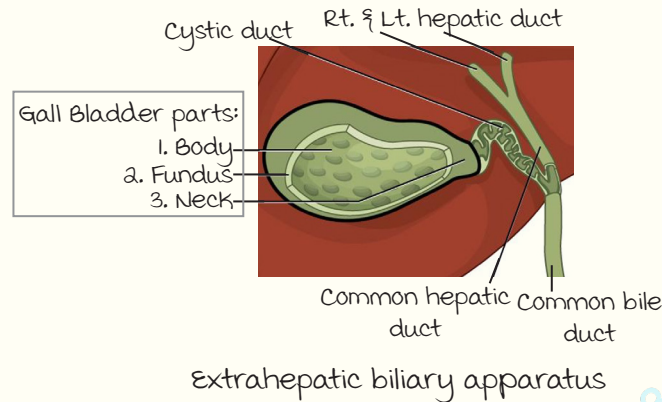
- Independent lobe.
- Supplied by Rt. & Lt. branch of portal vein & hepatic artery.
- Drains bile into Rt. & Lt. hepatic duct.
- venous drainage : **Directly to IVC.**



Extrahepatic Biliary Apparatus

00:28:17

Cystic duct + Common hepatic duct → Common bile duct.



Transpyloric plane : Horizontal plane at lower border of L1.

Structures passing through it :

- Tip of the 9th costal cartilage.
- Pylorus of stomach.
- Fundus of gall bladder.
- Origin of Superior mesenteric artery.
- Termination of spinal cord.
- Hilum of kidney.
- Portal vein formation.

Umbilicus : B/w L3 & L4.

Subcostal plane : Lower border of L3.

Trans tubercular plane : upper border of L5.

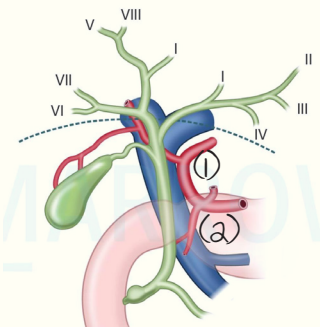
Note : Gall stones can get lodged in Hartmann's pouch.

Common Bile Duct (CBD) :

- Supraduodenal
- Retroduodenal
- Infraduodenal/retropancreatic

Relations :

- Posterior to CBD : Portal vein, IVC.
- Left of supraduodenal part of CBD : Proper hepatic artery (1).
- Left of retroduodenal part of CBD : Gastroduodenal artery (2).



Intra- & Extrahepatic biliary apparatus

Carcinoma head of pancreas obstructs retropancreatic part of CBD causing obstructive jaundice.

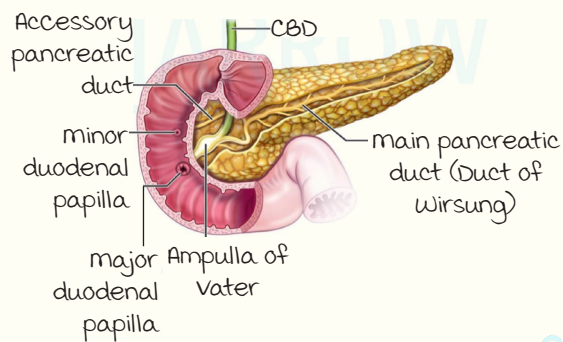
Stone in retropancreatic part of CBD can irritate head of pancreas and cause acute pancreatitis.

----- Active space -----

major duodenal papilla :
Posteromedial part of 2nd part of
duodenum.

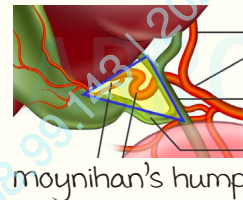
Sphincters :

- Ampulla of Vater : CBD & pancreatic duct.
- Sphincter of Boyden : Sphincter around CBD.
- Sphincter pancreaticus : Sphincter around pancreatic duct.
- Sphincter of Oddi : Sphincter around ampulla of Vater.



Moynihan's hump/caterpillar hump :

Tortuous right hepatic artery found inside Calot's triangle.



Pancreas

00:37:19

Relations :

Behind the head of pancreas :

- Right renal vein
- Left renal vein
- IVC

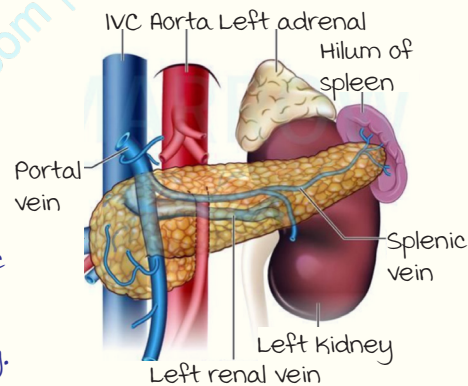
Behind neck : Superior mesenteric vein + splenic vein → Portal vein.

Body of pancreas : Crosses aorta & left kidney.
Leinorenal ligament holds tail of pancreas.

Structures crossing uncinete process :

1. Superior mesenteric vessels.
2. Left renal vein : Crosses the aorta anteriorly below the Superior mesenteric Artery (SMA).

Nutcracker syndrome : Compression of left renal vein b/w aorta & SMA.



Posterior relations of pancreas

Blood supply :

Splenic artery (Doesn't accompany splenic vein) runs along upper border of body of pancreas.

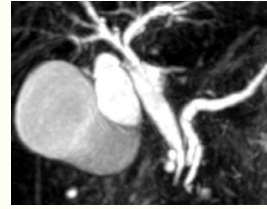Right gonadal vein drains into IVC.

Left gonadal vein drains in left renal vein (Obstruction causes left testicular pampniform plexus to dilate → varicocele).

----- Active space -----

Double duct sign :

Simultaneous dilatation of common bile duct & pancreatic duct d/t periampullary cancer/cancer head of pancreas.



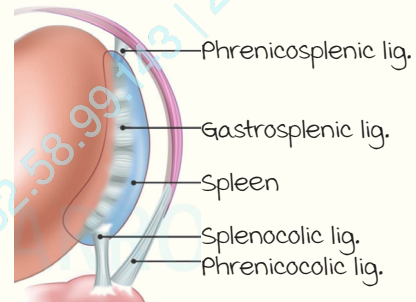
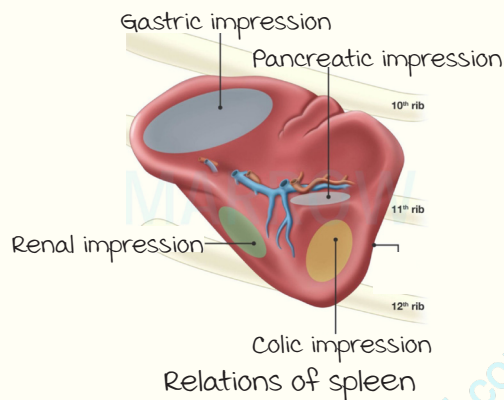
Double duct sign

Spleen

00:45:58

Notches present on superior border of spleen.

Axis of spleen passes through left 11th rib.

**Ligaments :**

1. **Gastrosplenic ligament** : Left gastroepiploic & short gastric arteries.
2. **Leinorenal ligament** : Tail of pancreas, splenic artery.
3. **Phrenicocolic ligament (Aka sustentacular leinis)** : Prevents downward displacement of spleen.

Renal System and Ureters

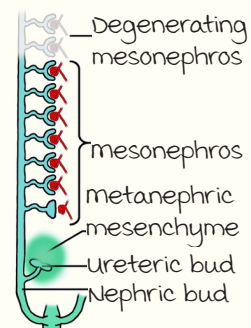
00:45:58

Embryology of Renal system :

urogenital tract derived from Intermediate mesoderm.

metanephros : Functions from 3rd month.

ureteric bud : Diverticulum of **mesonephric duct**.

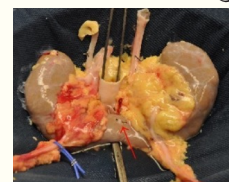


Development of Kidney

Horshoe Kidney :

Inferior poles of kidneys fused.

Ascent of kidney prevented by inferior mesenteric vein.



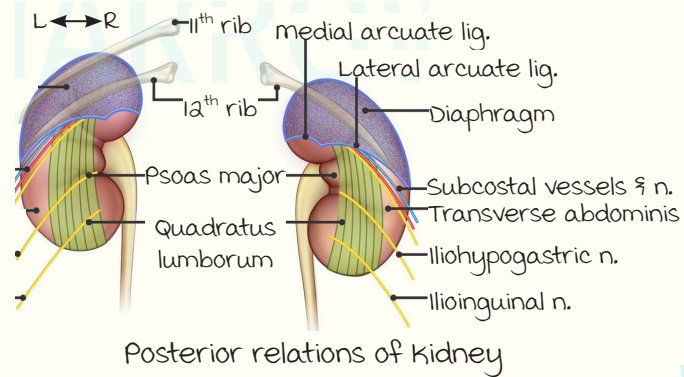
Horshoe Kidney

Kidney :

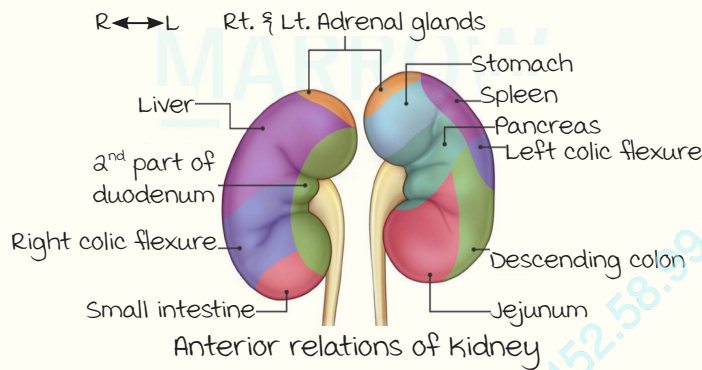
Relations of Kidney :

Posterior relation :

- Right Kidney : 12th rib only.
- Left Kidney : 11th & 12th rib.



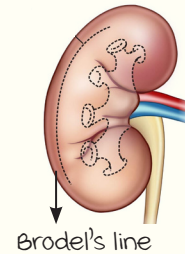
----- Active space -----



Blood supply :

Renal artery : Divides into 4 anterior & 1 posterior segmental arteries (5 arteries).

Junction of anterior & posterior segmental arteries : **Brodell's line** (Avascular plane; Surgical incisions can be made here).



Ureter :

Parts of ureter :

1. Pelvis of ureter : Hilum to lower pole of kidney.
2. Abdominal part : Lower pole of kidney to crossing of common iliac artery.
3. Pelvic part : From common iliac artery to opening inside bladder.

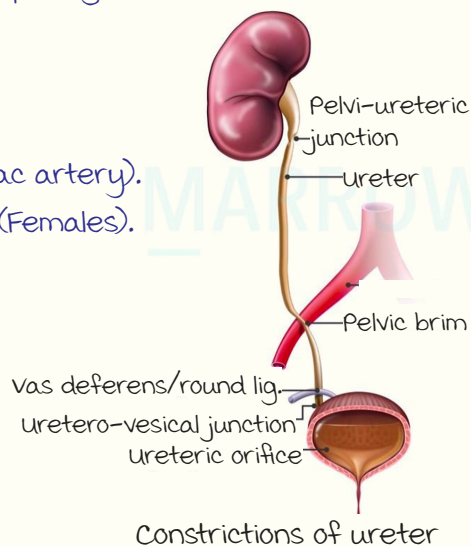
Constrictions of ureter :

5 surgical constrictions :

1. Pelvi-ureteric junction
2. Brim of pelvis (ureter crossing common iliac artery).
3. Crossing of : vas (males), round ligament (Females).
4. **Uretero-vesical junction** (Narrowest)
5. Ureteric orifice

3 anatomical constrictions :

1. Pelvi-ureteric junction
2. Brim of pelvis
3. Uretero-vesical junction



Blood vessels of abdomen

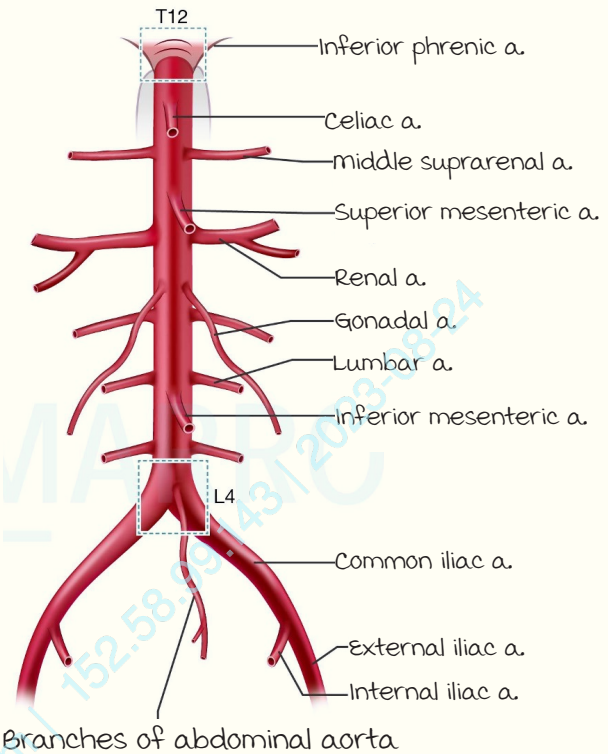
01:01:13

Branches of abdominal aorta :

Anterior
<ul style="list-style-type: none"> • Celiac artery (T12) • Superior mesenteric artery (L1) • Inferior mesenteric artery (L3)

Lateral
<ul style="list-style-type: none"> • Inferior phrenic artery • Middle suprarenal artery • Renal artery • Gonadal artery

Dorsal
<ul style="list-style-type: none"> • 4 pairs of lumbar arteries • Median sacral artery



Blood supply of adrenal gland :

Arterial supply :

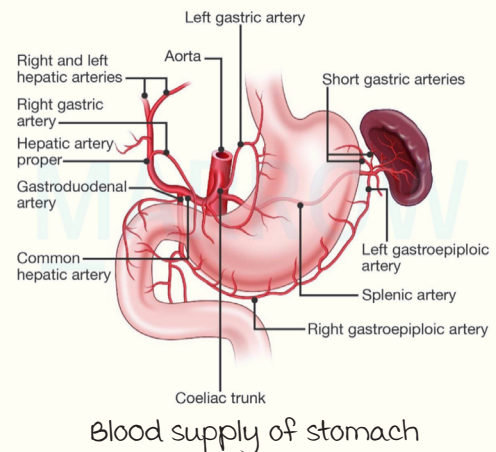
- Superior suprarenal artery (Branch of inferior phrenic artery).
- Middle suprarenal artery (Direct branch of aorta).
- Inferior suprarenal artery (Branch of renal artery).

Venous drainage :

- Right adrenal vein drains into IVC.
- Left adrenal vein drains into left renal vein.

Blood supply of stomach :

1. Left gastric artery (Smallest artery of celiac trunk) : Principal artery.
2. Right gastric artery (Branch of Proper hepatic a. > Common hepatic a.).
3. Right gastroepiploic artery (Branch of gastroduodenal a.).
4. Left gastroepiploic artery (Branch of splenic a.).



5. Short gastric artery (Branch of splenic a.) : Supplies fundus.

----- Active space -----

Note : Right & left gastric arteries anastomose along lesser omentum.

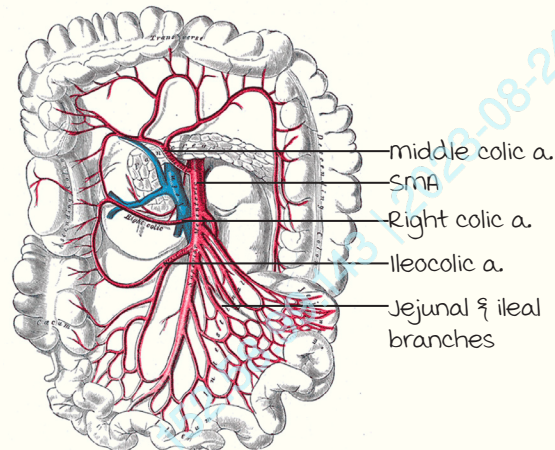
Superior mesenteric artery :

Artery of midgut.

Supplies from ampulla of Vater to right 2/3rd of transverse colon.

Branches :

- middle colic artery
- Right colic artery
- Jejunal & ileal branches
- Ileocolic artery
- Anterior & posterior caecal arteries
- Appendicular artery
- Ileal artery



Branches of SMA

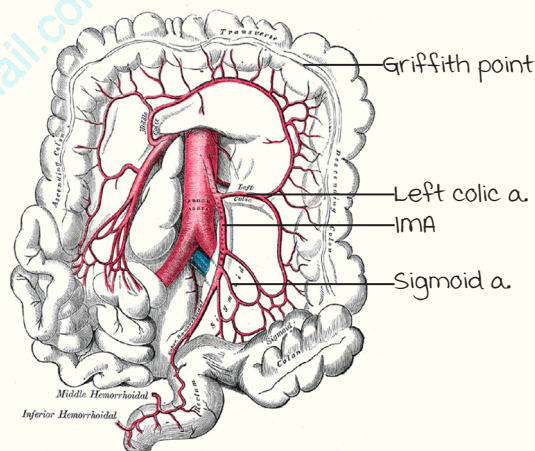
Inferior mesenteric artery (IMA) :

Branches :

- Left colic artery
- 2-3 sigmoidal artery
- Terminates as superior rectal artery.

Splenic flexure/Griffith's point :

- Supplied by left colic artery > left branch of middle colic artery.
- Ischemic colitis most commonly seen here.



Branches of IMA

ANATOMY REVISION 8

Perineum

00:00:12

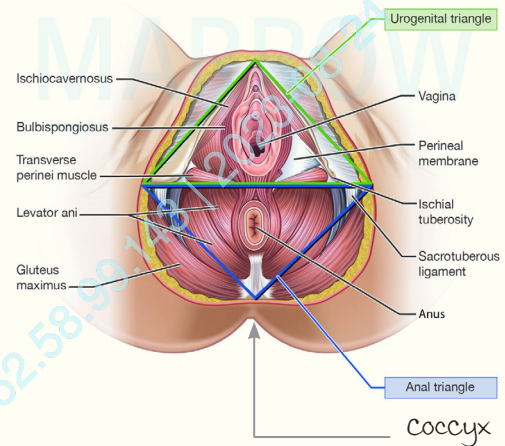
Perineum :

Boundaries :

1. Anteriorly : Pubic symphysis.
2. Posteriorly : Coccyx.
3. Laterally : Ischial tuberosity.

On either side of anal opening : **ischioanal/ischiorectal space.**

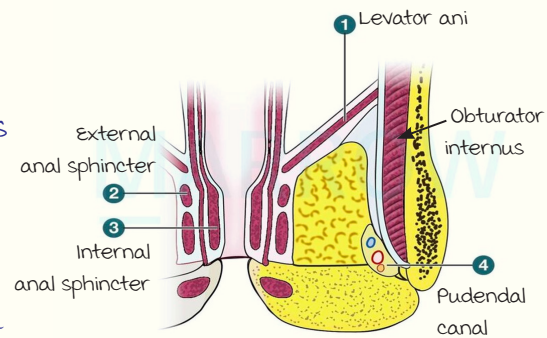
Perineum - urogenital and anal triangles



Ischiorectal fossa :

Boundaries :

- medially : Levator ani (Part of pelvic diaphragm).
- Laterally : Lateral pelvic wall contains
 - a. Obturator internus muscle
 - b. Fascia over obturator internus
 - c. Pudendal/Alcock's canal
(Formed from splitting of fascia over obturator internus).



Contents

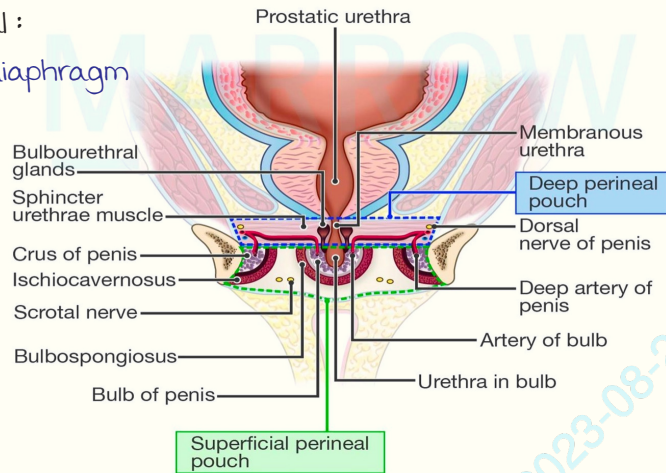
1. Inferior rectal nerve and vessels
 2. Internal pudendal vessels
 3. Pudendal nerve
 4. Posterior scrotal vessels and nerves (In female : Posterior labial vein & nerve).
- } Contents of pudendal canal

This fossa communicates with other side behind rectum and anal canal (**Horse shoe shape**) : Can spread infection to other side.

Urogenital Triangle :

Layers from deep to superficial :

1. Superior layer of urogenital diaphragm
2. Deep perineal space
3. Perineal membrane
4. Superficial perineal space
5. Deep fascia
6. Superficial fascia
7. Skin



----- Active space -----

Internal urethral sphincter :

- Smooth muscle present at the bladder neck.
- Prevent the retrograde ejaculation of semen.
- m/c injured during TURP → Retrograde ejaculation of semen.

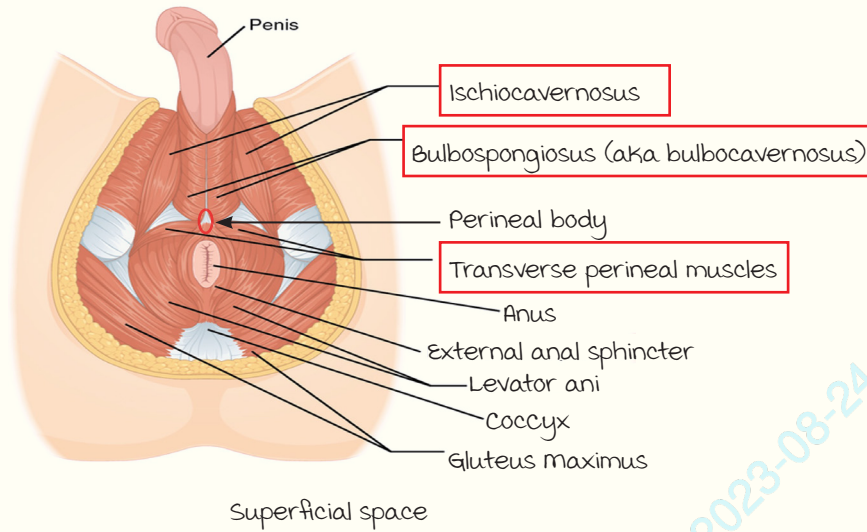
Urethra :

1. Prostatic urethra
2. Membranous urethra : Present in deep space.
3. Spongy urethra : Present in superficial space.
 - a. Bulbar part
 - b. Penile Part

Deep space :

muscles	vessels	Nerve	Other contents
1. Sphincter urethrae muscle/External urethral sphincter (EUS) : <ul style="list-style-type: none"> • Skeletal muscle surrounding the membranous urethra. • Injury : Urinary incontinence. 2. Deep transverse perinei.	Terminal branches of internal pudendal artery : <ul style="list-style-type: none"> • Dorsal artery of penis/clitoris. • Deep artery of penis/clitoris. • Artery to the bulb of penis/clitoris. 	Dorsal nerve of penis/clitoris.	In males : <ul style="list-style-type: none"> • membranous urethra • Cowper's gland (Bulbourethral gland). In females : Urethral & vaginal opening.

----- Active space -----

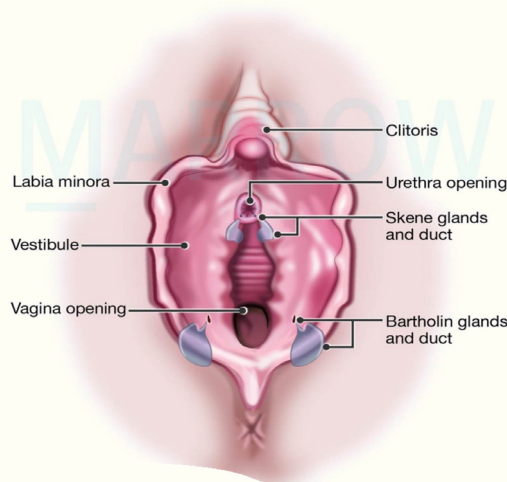


Superficial pouch/space :

muscles	vessels	Nerve	Other contents
1. Bulbospongiosus	Posterior	Posterior	In males :
2. Ischiocavernosus	scrotal/labial	scrotal/	• Spongy urethra
3. Superficial transverse perinei.	vessels.	labial nerve.	• Root of penis (Bulb + Crus)
			In female :
			• urethral & vaginal opening
			• Bartholin's (Greater vestibular gland)

Note :

- All muscles of perineum meet at perineal body **except ischiocavernosus**.
- Swelling in posterior vaginal wall : Bartholin's cyst.
- Swelling in anterior vaginal wall : Gartner's cyst (**Remnant of Wolffian duct**).

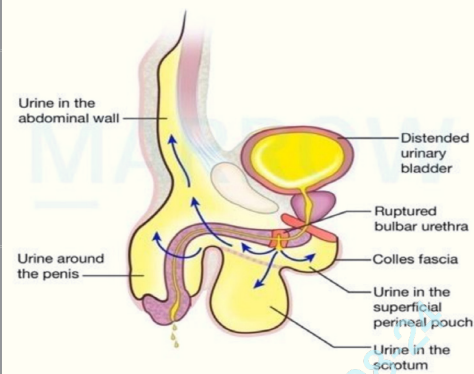


Skene's glands & Bartholin glands

Urinary extravasation in urethral rupture :

----- Active space -----

Urethra	Type of injury	Urine extravasation
Spongy urethra	Straddle injury	<ul style="list-style-type: none"> • Superficial perineal space • Ant abdominal wall • Scrotum • Around penis
Membranous urethra	Pelvic fracture	<ul style="list-style-type: none"> • Deep space • Space of Retzius (Around bladder & prostate).



Note : Only in case of **bladder rupture**, urine extravasates into peritoneum.

Pudendal nerve :

- Root value : S2, 3, 4.
- **Mixed nerve**
- Branches :
 1. Inferior rectal nerve
 2. Dorsal nerve of penis/clitoris
 3. Perineal nerve :
 - a. Superficial branch : Posterior scrotal/labial nerve (**Sensory**).
 - b. Deep branch : **motor**.
- Landmark for pudendal nerve block → **Ischial spine**.

Prostate & prostatic urethra

00:21:03

Trigone of urinary bladder :

mesodermal origin (Bladder except trigone : **Endoderm**).

No rugae (mucosa is adherent to underlying detrusor).

Submucosa absent.

Seminal colliculus :

Extension of trigone to prostatic urethra : **Urethral crest**.

urethral crest expands to form seminal colliculus/verumontanum.

Seminal colliculus has 3 openings :

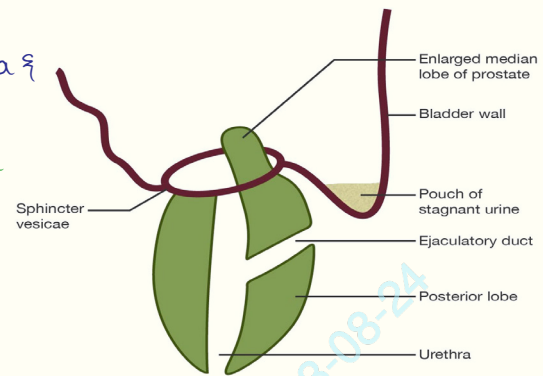
- **2 ejaculatory ducts** (Arises from **mesonephric duct in males**).
- **1 prostatic utricle** (Remnant of **paramesonephric duct in males**).

----- Active space -----

Prostate gland

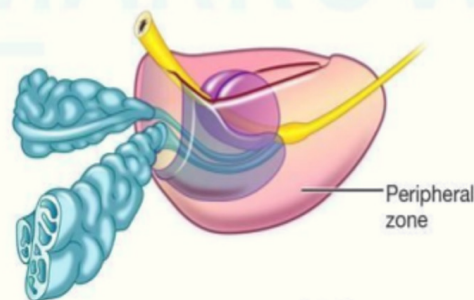
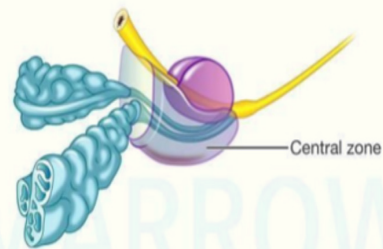
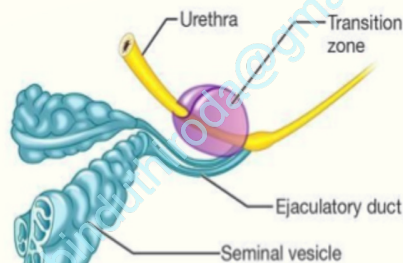
median lobe of prostate :

- Part of prostate b/w prostatic urethra & ejaculatory duct.
- Base : Extends into bladder → *uvula*
- *vesicae*.
- Enlargement of uvula vesica (In BPH) → Stagnation of urine and infection.



Counterpart of prostate gland in female : Paraurethral glands of Skene.

Zone	Location	Disease
Transition zone	Surrounding the proximal part of prostatic urethra	BPH
Central zone	Surrounding the ejaculatory duct	Ca <2% (Highly invasive type)
Peripheral Zone	Surrounding distal part of prostatic urethra	Ca >80%



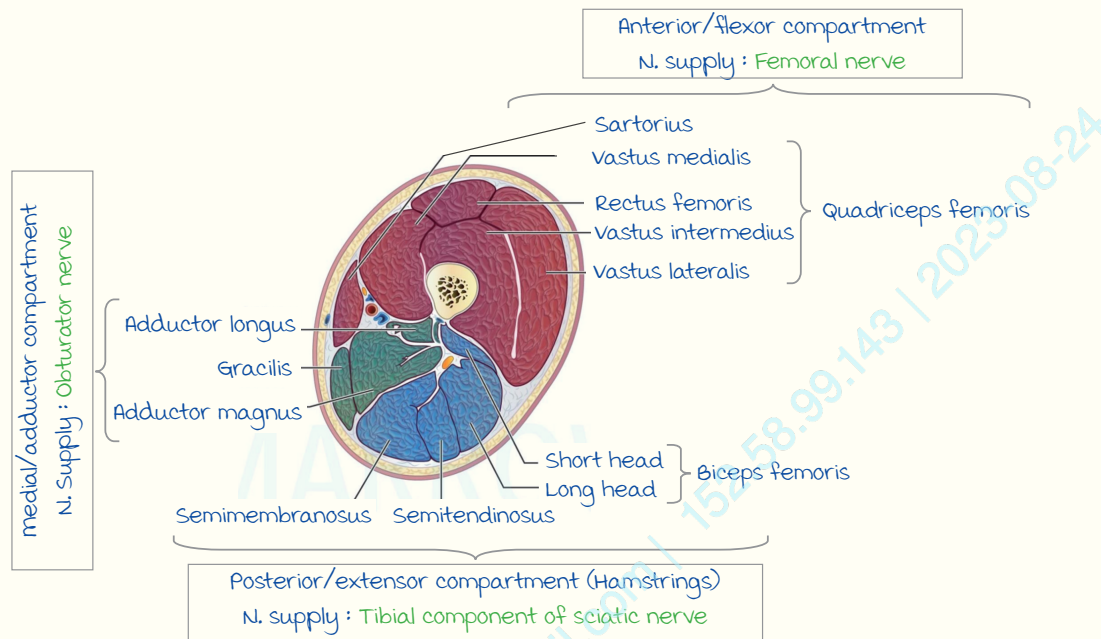
Zones of Prostate gland

ANATOMY REVISION-9

----- Active space -----

Thigh - Compartments

00:00:26



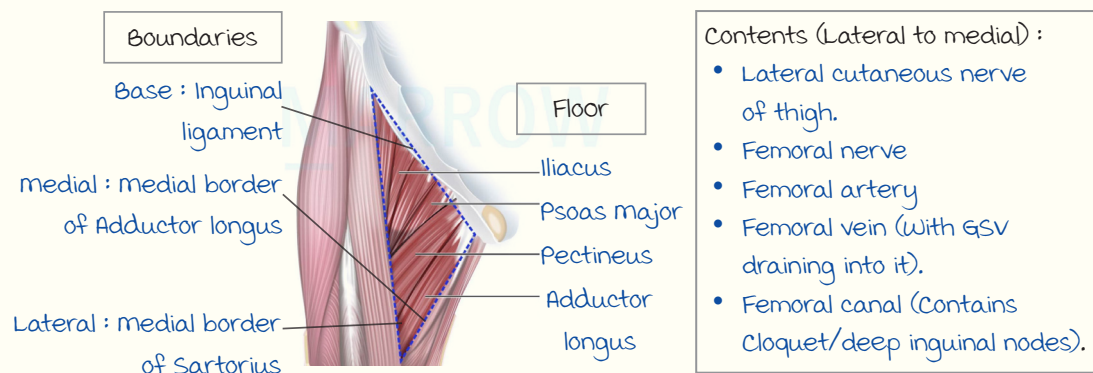
Hybrid muscles of thigh :

	Pectineus	Adductor magnus
Location	Jn. b/w flexor & adductor compartment	Jn. b/w extensor & adductor compartment
N. supply	Femoral Nerve Obturator nerve	Tibial component of sciatic Nerve Obturator nerve

Anterior Compartment of Thigh

00:04:50

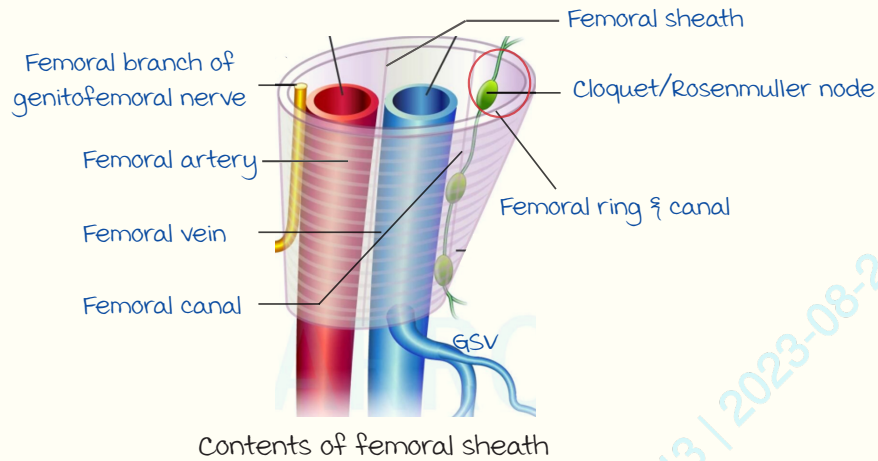
Femoral triangle :



----- Active space -----

Femoral Sheath :

Fascial prolongation onto the proximal part of femoral vessels.



Femoral ring : Below & lateral to pubic tubercle.

- Anteriorly : Inguinal ligament.
- Posteriorly : Pectineus muscle & pectineal ligament of Cooper.
- Medially : Lacunar ligament.
- Laterally : Femoral vein.

Note : Superficial Inguinal ring - Above & medial to pubic tubercle.

Important muscles of front of thigh :

muscle		Origin	Insertion	Action	
				Hip joint	Knee joint
Quadriceps femoris	Rectus femoris	A.I.I.S	Quadriceps tendon to tibial tuberosity (Sesamoid bone in the tendon : Patella)	Flexion	Extension
	vasti muscles	Femur		No action	
Sartorius		ASIS	medial surface of tibia (Pes anserinus)	Flexion Abduction Lateral rotation	medial rotation Flexion

A.I.I.S : Anterior inferior iliac spine; ASIS : Anterior superior iliac spine.

Pes anserinus :

Insertion of guy rope muscles (Semitendinosus, sartorius, gracilis) on the medial surface of tibia.

Adductor Canal and Popliteal Fossa

00:16:40

----- Active space -----

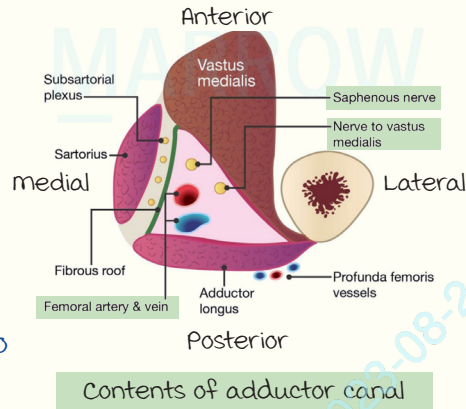
Adductor Canal (Subsartorial canal) :

Boundaries :

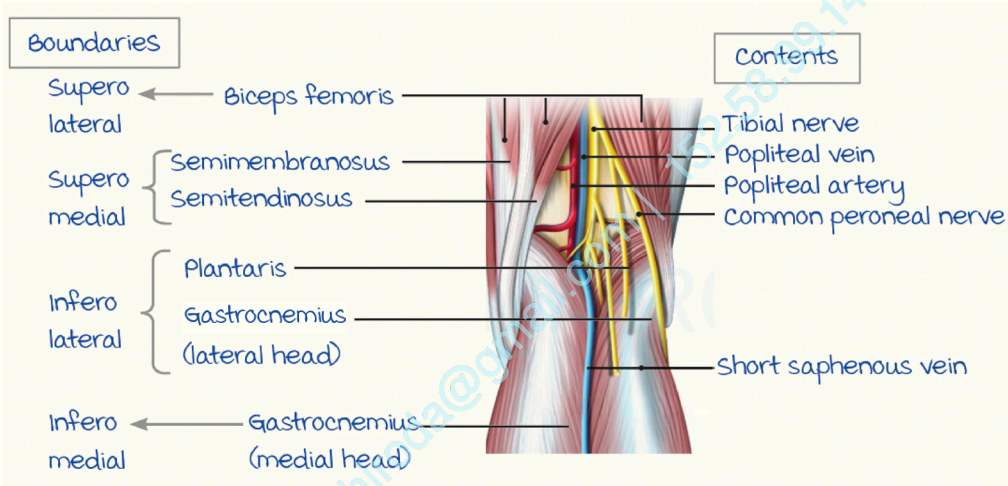
- Roof : Sartorius.
- Anterolateral : Vastus medialis.
- Posteromedial : Adductor longus
→ Adductor magnus.

Significance :

Passage for femoral vessels from femoral Δ to popliteal fossa. Hence easily accessible.



Popliteal fossa :



Gluteal Region

00:21:17

muscle	Attachment	Nerve supply	Action
Gluteus maximus	Origin : Ilium, sacrum, Coccyx, Sacrotuberous ligament Insertion : 1/4 - Gluteal tuberosity. 3/4 - Iliotibial tract	Inferior gluteal nerve	Extension, Lateral rotation (1° muscle for lateral rotation), Abduction of hip
Gluteus medius	Origin : Ilium Insertion : Greater trochanter (Lateral surface)	Superior gluteal nerve	Abduction , medial rotation of hip, prevent pelvis sinking on unsupported side (Trendelenburg test)
Gluteus minimus	Origin : Ilium Insertion : Greater trochanter (Anterior surface)		

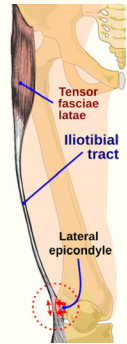
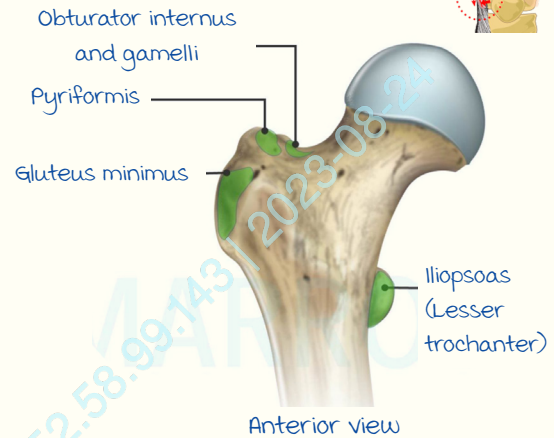
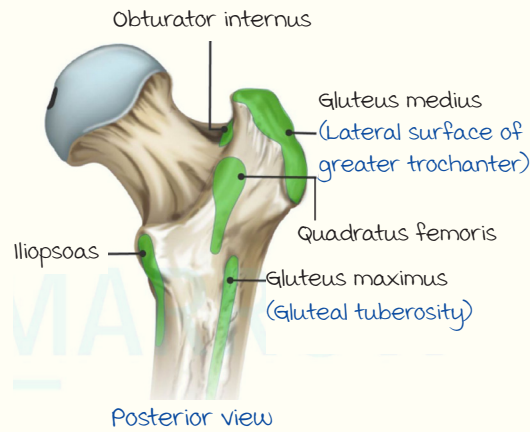
----- Active space -----

Iliotibial tract :

modification of deep fascia on the lateral aspect of thigh.

muscles attached :

- Tensor fascia lata (Anterior).
- Gluteus maximus (Posterior).

**Attachment of muscles to femur****Superior gluteal nerve**

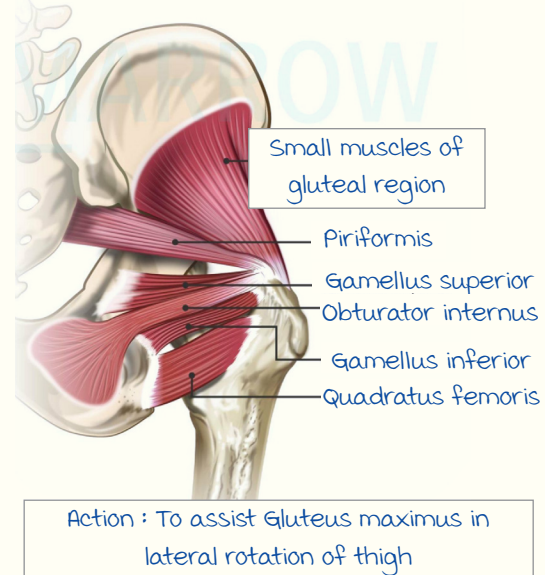
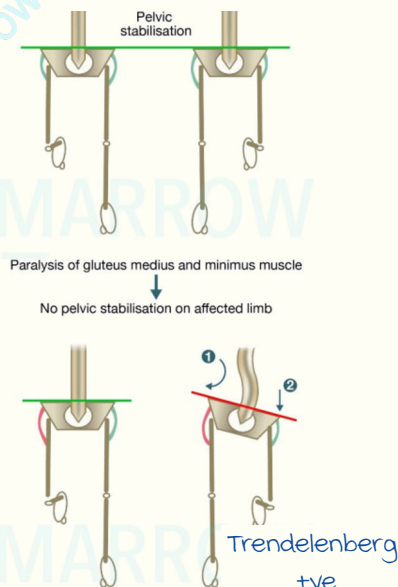
muscles supplied :

- Tensor fascia lata.
- Gluteus medius & minimus.
- Piriformis (usually supplied by S1, S2 fibres)

Trendelenburg sign :

Sinking of pelvis on the **unsupported/unaffected side** when the patient stands on the paralysed side.

D/t injury to the **superior gluteal nerve** (paralysis of Gluteus medius & minimus).



Posterior Compartment of Thigh

00:31:46

----- Active space -----

Hamstring muscles :

- Origin : Ischial tuberosity.
- Insertion : Bones of leg.
- Actions : Extension of hip; Flexion of knee.
- N. supply : Tibial part of sciatic nerve.
- Include : Semimembranosus.
Semitendinosus.
Long head of biceps femoris.
Hamstring part of adductor magnus.

Note : Short head of biceps (Not hamstring)

- Origin : Femur
- Nerve supply : Common peroneal component of sciatic nerve.

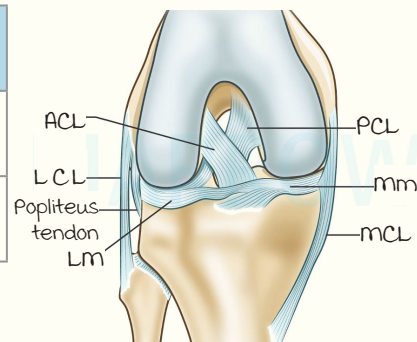
Sciatic nerve (at the upper angle of popliteal fossa) divides into :

1. Tibial nerve → Posterior compartment of leg.
2. Common peroneal nerve (Winds around neck of fibula) :
 - Superficial peroneal nerve → Lateral compartment of leg.
 - Deep peroneal nerve → Anterior compartment of leg.

Knee joint

00:37:10

medial collateral ligament (MCL)	Lateral collateral ligament (LCL)
Primitive insertion of Adductor magnus	Primitive insertion of Peroneus longus
Prevent medial displacement of femur & tibia	Prevent lateral displacement of femur & tibia



	medial meniscus (mm)	Lateral meniscus (Lm)
Shape	C shape	Almost circular
Function	Fibrocartilage (shock absorber function)	
Attached to	MCL	Popliteus tendon
Injury	more (immobile, fixed)	Less (popliteus tendon pulls)

menisci are intra-capsular, intra-synovial.

----- Active space -----

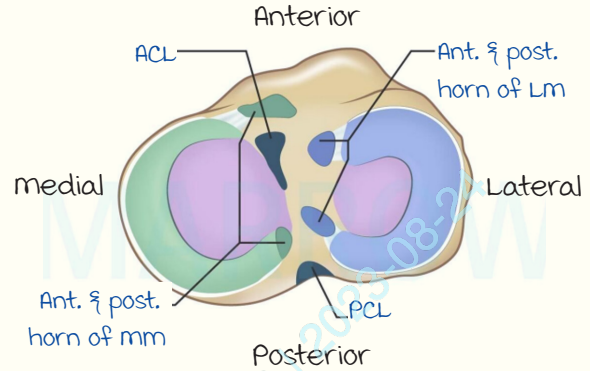
unhappy triad/Terrible triad :

D/t lateral blow → Injury to **mCL + medial meniscus + ACL**.

Intercondylar area of tibia (Anterior to posterior) :

Mnemonic : Brendon **McCuLLum**

- **m**edial meniscus (antr. horn).
- **A**nterior **C**ruciate ligament.
- **L**ateral meniscus (antr. horn).
- **L**ateral meniscus (postr. horn).
- **m**edial meniscus (postr. horn).
- **P**osterior cruciate ligament.



Cruciate ligaments :

Intracapsular, extra-synovial.

	Anterior cruciate ligament (ACL)
Tibial origin	Anterior part of intercondylar area
Femoral insertion	medial surface of lateral condyle (Postero superior aspect)
Direction	Upward; Backward; Laterally
Taut	During extension
Function	Prevent anterior displacement of tibia & posterior displacement of femur

Posterior cruciate ligament (PCL) is **opposite of ACL**.

Compartments of leg

00:50:26

Compartment	Nerve	Artery
Posterior	Tibial nerve	Posterior tibial artery (Branch of popliteal artery)
Anterior	Deep peroneal nerve	Anterior tibial artery (Branch of popliteal artery)
Lateral	Superficial peroneal nerve	Peroneal artery (Branch of posterior tibial artery)

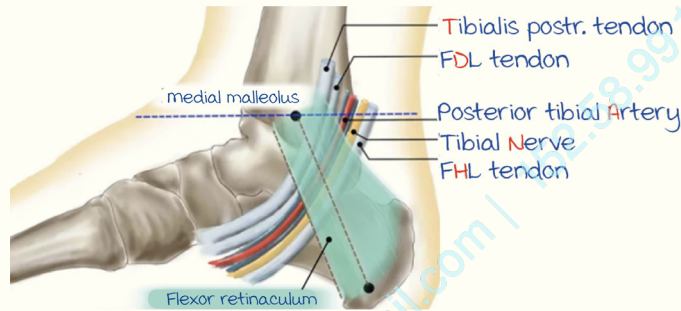
Posterior compartments of leg :

----- Active space -----

Superficial compartment	Deep compartment
<ul style="list-style-type: none"> Gastrocnemius + Soleus : <i>Triceps Surae.</i> Action : Plantar flexion. Plantaris : vestigial muscle (Tendon used for augmentation procedures) 	<ul style="list-style-type: none"> Popliteus : <i>Initiate flexion.</i> Tibialis posterior : <i>Plantar flexion & inversion.</i> Flexor digitorum longus (FDL) : Plantar flexion, flexion of lateral 4 toes. Flexor hallucis longus (FHL) : Plantar flexion, flexion of big toe.

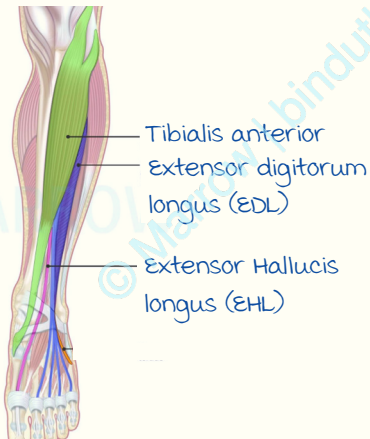
Flexor retinaculum :

medial to lateral : mnemonic - *Tom Dumbledore ANd Harry*



Tarsal tunnel syndrome : Compression of tibial nerve.

Anterior compartment of leg :



muscle	Action
Tibialis anterior	<i>Dorsiflexion , Inversion</i>
EDL	Dorsiflexion, Extend lateral 4 toes
EHL	Dorsiflexion, Extend big toe

Inversion & eversion :

Takes place at 3 joints :

- Subtalar joint (*Posterior talocalcaneal joint*).
 - Calcaneocuboid joint
 - Talocalcaneonavicular joint
- } *Transverse talar joint.*

----- Active space -----

muscles :

Invertors (medial side) : Tibialis anterior, Tibialis posterior.

Evertors (lateral side) : Peroneus longus, Peroneus brevis.

Lateral compartment of leg :

muscles : Peroneus longus, Peroneus brevis.

Action : Eversion of foot.

Cutaneous innervation of dorsum of foot

01:01:12

