

# ENT REVISION 1

----- Active space -----

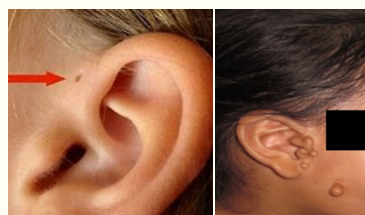## Ear development/Embryology

00:01:16

Ear Structures	Origin
Tragus & anterior helix	1 <sup>st</sup> pharyngeal arch
Rest of Pinna	2 <sup>nd</sup> pharyngeal arch
External auditory meatus	1 <sup>st</sup> pharyngeal arch
Tympanic membrane	All 3 germ layers
malleus & Incus	1 <sup>st</sup> pharyngeal arch
Stapes suprastructure	2 <sup>nd</sup> pharyngeal arch
Stapes footplate & annular ligament	Otic capsule (Bony labyrinth)
Middle ear cleft (middle ear cavity, mastoid antrum & Eustachian tube)	1 <sup>st</sup> pharyngeal pouch/ tubotympanic recess
Semicircular canals, utricle, Endolymphatic sac.	Pars superior
Sacculle and cochlea	Pars inferior

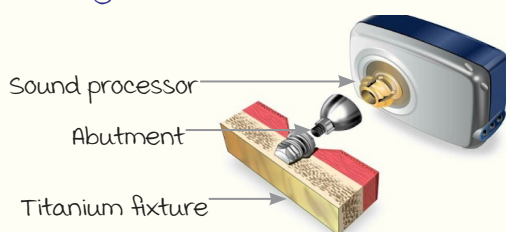
### Disorders of ear development

1. Preauricular sinus : Fusion defect of auricular tubercles (MC site is root of helix).
2. Accessory auricles/ preauricular skin tags :  
D/t abnormal fusion.

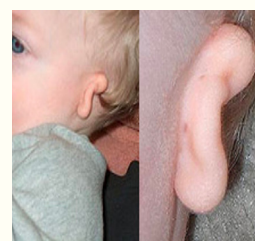


Preauricular sinus      Accessory auricle

3. microtia/Anotia (seen in Goldenhar syndrome, Treacher Collins syndrome).  
Rx : Otoplasty/ Pinnaplasty : Reconstruction done using autologous rib cartilage (after 6 yrs of age). Indications of hearing rehabilitation by BAHA :
  - Atresia.
  - Discharging ear.
  - Big ear cavity post op.
  - Single ear deafness.



BAHA : Implanted ideally at 5y/3mm of skull thickness



microtia

----- Active space -----

## 4. Callaural fistula :

External opening at angle of mandible, internal opening at floor of EAC.

mx : excision while taking care of **facial nerve**.

5. Persistent petrosquamous suture/**Korners septum** :

meeting point of petrous & squamous parts of temporal bone d/t which disease in antrum can be missed.

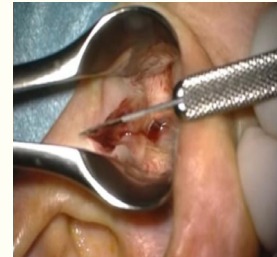- mastoid tip develops at 2yrs. Significance : A post auricular incision before 2 years of age can injure facial nerve at the stylomastoid foramen.

Scheibe dysplasia	Cochelosaccular dysplasia (mc anomaly of inner ear)
mondini dysplasia	Only 1 1/2 turns of cochlea present. (Normal : 2 <sup>3</sup> /4 turns)
Michel aplasia	Absent labyrinth(C/I for cochlear transplant)

- Organ of Corti develops by 20-25 weeks of gestation.
- Structures of Ear not developed at Birth : Bony EAC, mastoid tip.

## Anatomy of Pinna

- Cartilagenous landmark for mastoid antrum : Cymba conchae.
- Bony landmark for mastoid antrum : Mac Ewan's triangle.
- Skin is more tightly adherent on lateral side of Pinna.



Lemperts incision

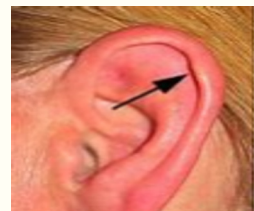
## Diseases of pinna :

Darwins tubercle : used for identification.

**Lemperts incision** : Intercartilagenous incision

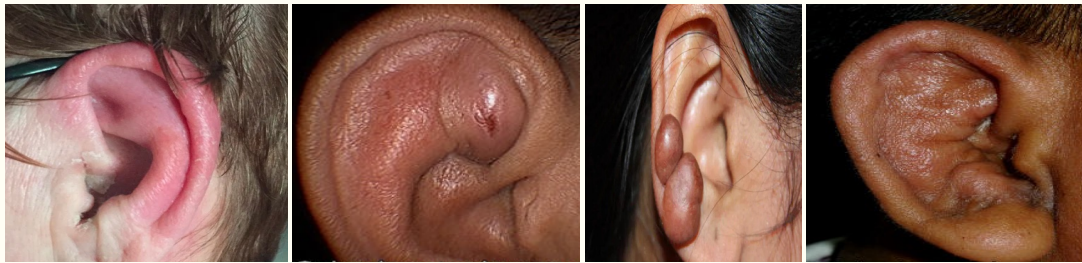site : **Incisura terminalis**.

00:14:10



Darwins tubercle

Condition of pinna	Presentation	mx
Hematoma (organised hematoma aka cauliflower ear)	Swelling lateral side of ear, h/o trauma +	Aspiration. For cauliflower ear : Plastic Sx.
Perichondritis (m/c d/t Pseudomonas)	Red hot painful pinna sparing lobule.	Antibiotics (Ciprofloxacin)
Keloid	h/o trauma, firm rubbery nodule on pinna.	Intralesional steroids/Excision f/b postop intralesional steroids/ radiation to prevent recurrence.



Perichondritis

Hematoma

Keloid

Cauliflower ear

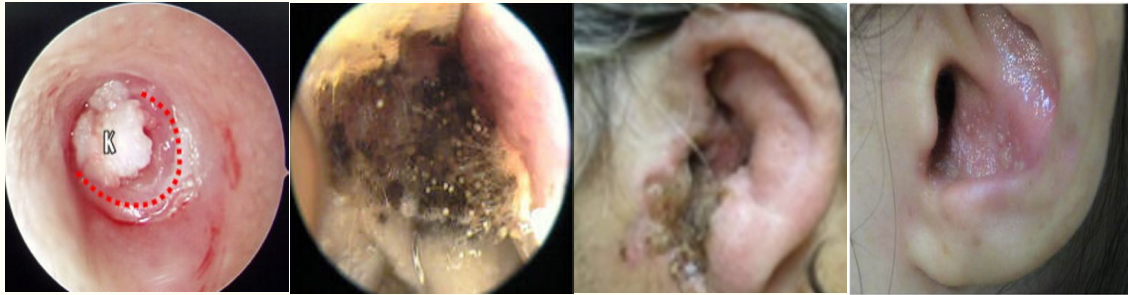----- Active space -----

### Anatomy of EAC

- Narrowest part : Isthmus.
- Outer 1/3<sup>rd</sup> (8 mm) Cartilagenous : Wax production from apocrine glands.
- Inner 2/3<sup>rd</sup> (16 mm) Bony.
- Deficiencies in the floor of EAC : Fissure of santorini (cartilagenous) & fissure of Huskhe (bony) : Can lead to spread of infection to parotid & base of skull respectively & vice versa.

Condition of EAC	Description
Folliculitis / Furuncle m/c cause : Staph.	C/f : Pain in ear ↑es on jaw movement. O/E : Lesion seen in outer 1/3 <sup>rd</sup> of EAC + tragal sign + Rx : Topical antibiotics. Investigate for <b>DM</b> in case of recurrent folliculitis.
Diffuse otitis externa (swimmers ear) : Cause : Pseudomonas	C/f : Pain, discharge, blocked ear, h/o trauma. O/E : Diffuse edema of EAC/tragal sign + Rx : Topical antibiotics.
Otomycosis (m/c cause <b>aspergillus</b> > candida)	C/f : Pain, discharge, blocked ear + itching O/E : Wet newspaper/ cotton ball appearance. Rx : Aural toilet, topical antifungal
Herpes Zoster Oticus Ramsey hunt syndrome (reactivation of VZV in <b>geniculate ganglion</b> )	C/f : Pain, discharge, blocked ear. O/E : vesicles in outer 1/3 <sup>rd</sup> of EAC, facial palsy, otalgia. Rx : Systemic antivirals.
malignant otitis externa aka skull base osteomyelitis (caused by pseudomonas)	Immunocompromised/severe otalgia/granulations/ discharge/ Facial palsy (m/c nerve to get involved) On biopsy: No mitotic figures. On Tc99 bone scan : High uptake. Rx : Antibiotics, Debridement. Ga-67, In-111, serial <b>ESR</b> to check resolution.
Keratosis obturans (Abnormal migration of skin in EAC)	C/f : Severe otalgia, H/o chronic sinusitis, bronchiectasis. O/e : white mass in deep meatus, facial palsy, widening of EAC. Rx : Excision under local anaesthesia.

----- Active space -----



Keratosis obturans

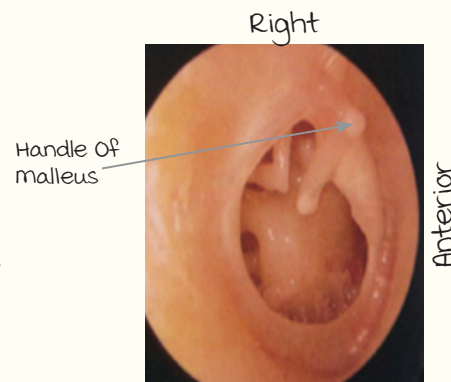
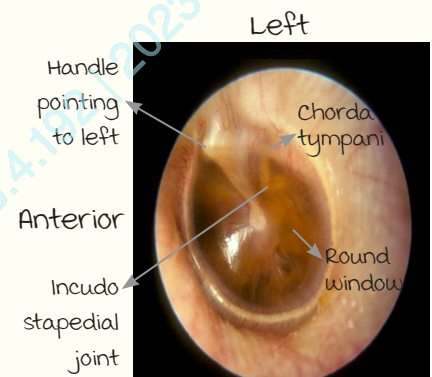
Otitomycosis  
(wet newspaper app.)malignant otitis  
externaRamsay hunt  
syndrome

### Anatomy of tympanic membrane

- Colour : Pearly white/grey, 3 layered, translucent. Heals in 2 layers.
- Angle with horizontal :  $55^\circ$ .
- Effective vibratory SA :  $55 \text{ mm}^2$ . (TSA :  $90 \text{ mm}^2$ ).
- most mobile : Pars flaccida (Shrapnell's membrane : m/c site of retraction pocket).
- most mobile part of pars tensa : Periphery/paramedian.
- Cone of light : Antero inferior quadrant.
- Umbo : TM attaches to tip of malleus.

#### Determination of side :

- Handle of malleus (If points to Rt, indicates Rt side Tm).
- Cone of light.



### Anatomy of middle ear

00:39:33

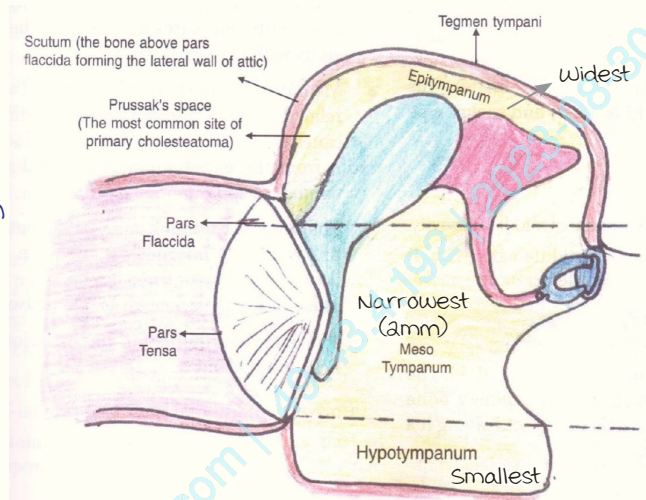
Structures on medial wall	Significance
Promontory	Formed by basal turn of cochlea
Processus cochleariformis	Landmark for 1 <sup>st</sup> genu of facial & geniculate ganglion Tensor tympani takes a lateral turn to attach to upper end of malleus handle
Facial N tympanic /horizontal	MC dehiscent segment of Facial nerve

LSC bulge	mc SCC eroded/ fistula formation by cholesteatoma Stimulated by caloric test, landmark for facial nerve.
Tympanic plexus	Formed by Jacobson's Nerve, sympathetic plexus around ICA, sup & inf caroticotympanic nerves & 9 <sup>th</sup> cranial nerve.
Round window	Electrodes of cochlear implant & drug delivery (Scala tympani)
Oval window	Foot process of stapes present here transmits sound vibrations to scala vestibuli (sv)

----- Active space -----

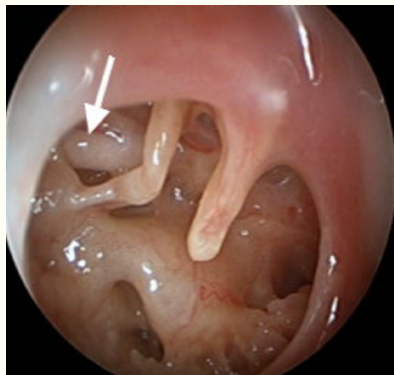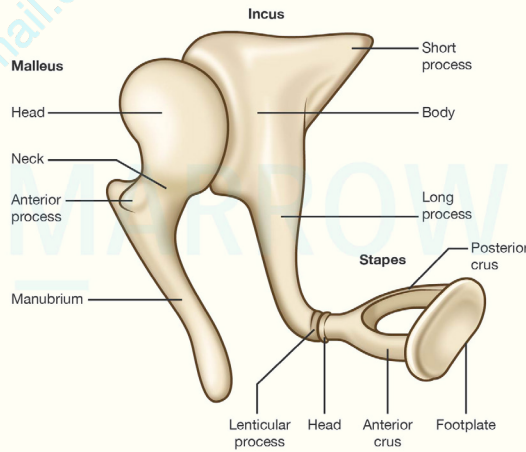
Anterior wall/ Carotid wall :

- Canal of Huguier : Exit of chorda tympani.
- On anterior wall : Eustachian tube opening.
- Tensor tympani origin.

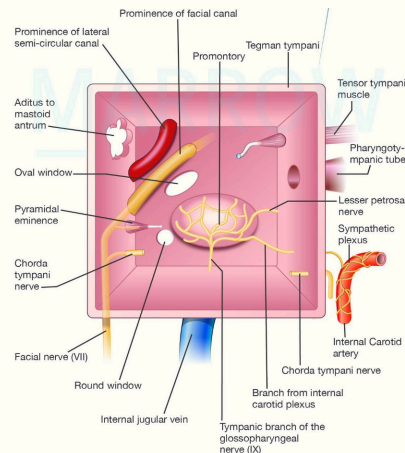


Ear ossicles :

- Incudomalleolar joint : Saddle joint.
- Incudostapedial joint : Ball & Socket.
- Ossicle necrosis : Long process of incus > head of stapes.
- Largest : malleus.
- Smallest : Stapes.



middle ear : Endoscopic view



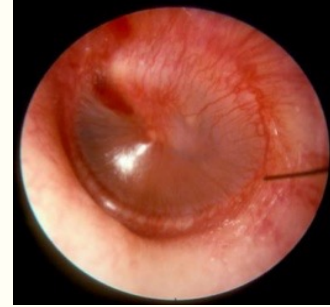----- Active space -----

## Acute Otitis Media (AOM)

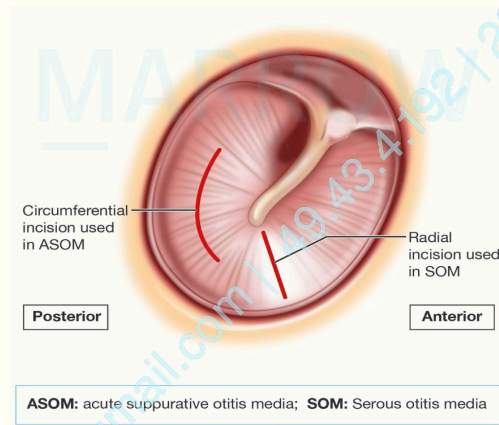
00:49:00

- C/o acute onset ear pain + discharge + h/o URTI.
- O/E : Tm congested (cart wheel appearance).
- MC route : Eustachian tube.
- MC organism : Pneumococcus.
- Light house sign / Pulsatile otorrhoea : Rupture of Tm.
- mx : Antibiotics.

If Tm bulging with severe pain/facial palsy :  
myringotomy (Curvilinear incision at postero-inferior quadrant).



Cartwheel Tm

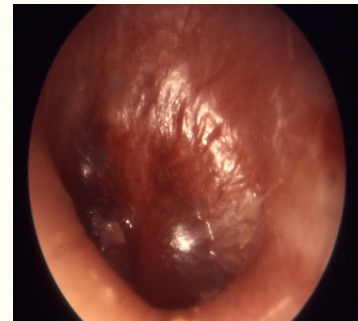

myringotomy in middle ear

## Bullous myringitis :

00:52:26

- AKA myringitis bullosa/Otitis externa hemorrhagica.
- m/c organism : Pneumococcus.
- Other organisms : Influenza virus, mycoplasma pneumoniae.
- Symptoms same as AOM.
- O/E : Tm red congested with bullae, can rupture causing serosanguinous/hemorrhagic discharge.
- mx : Same as AOM.

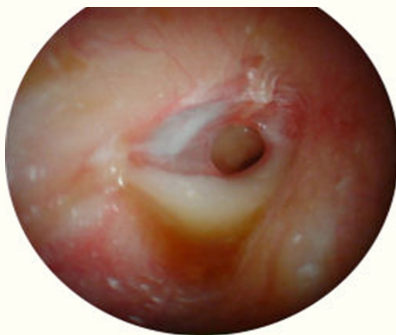

Bullous myringitis

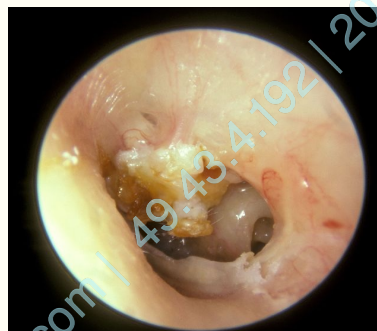
# Chronic Otitis Media (AOM)

00:53:58

mucosal/tubotympanic (safe)	Squamosal/atticoantral/unsafe
<ul style="list-style-type: none"> <li>• H/o profuse painless mucoid/mucopurulent discharge + hearing loss &gt; 12 weeks. (Active)</li> <li>• Inactive disease : Only hearing loss.</li> <li>• O/E : Permanent (&gt; 3 months) central perforation, pale granulation.</li> </ul>	<ul style="list-style-type: none"> <li>• H/o scant, purulent, foul smelling, painless discharge maybe blood tinged.</li> <li>• O/e : Attic/Posterosuperior retraction pocket, marginal perforation with cholesteatoma, fleshy red granulation.</li> </ul>



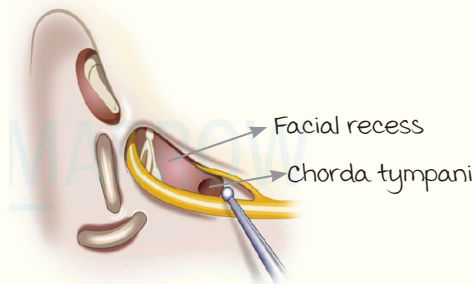
mucosal COM



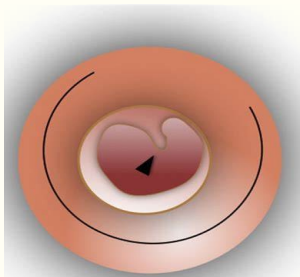
Squamosal COM

- mx : medical mx : To make ear dry → Give local/systemic antibiotics. PTA/patch test to assess ossicular status. When inactive (>6 weeks) : myringoplasty/Tympanoplasty.

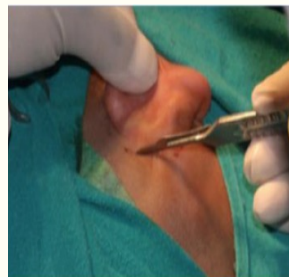
- Boundaries of facial recess :  
 medially : Descending part of facial nerve.  
 Laterally : Chorda tympani nerve.  
 Superiorly : Incus buttress (Near the short process of incus).



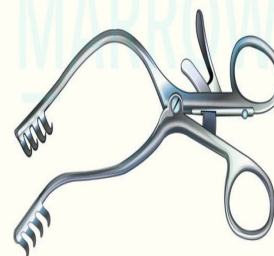
- Incision used in tympanoplasty :



Rosens transcanal incision



Wildes postaural incision

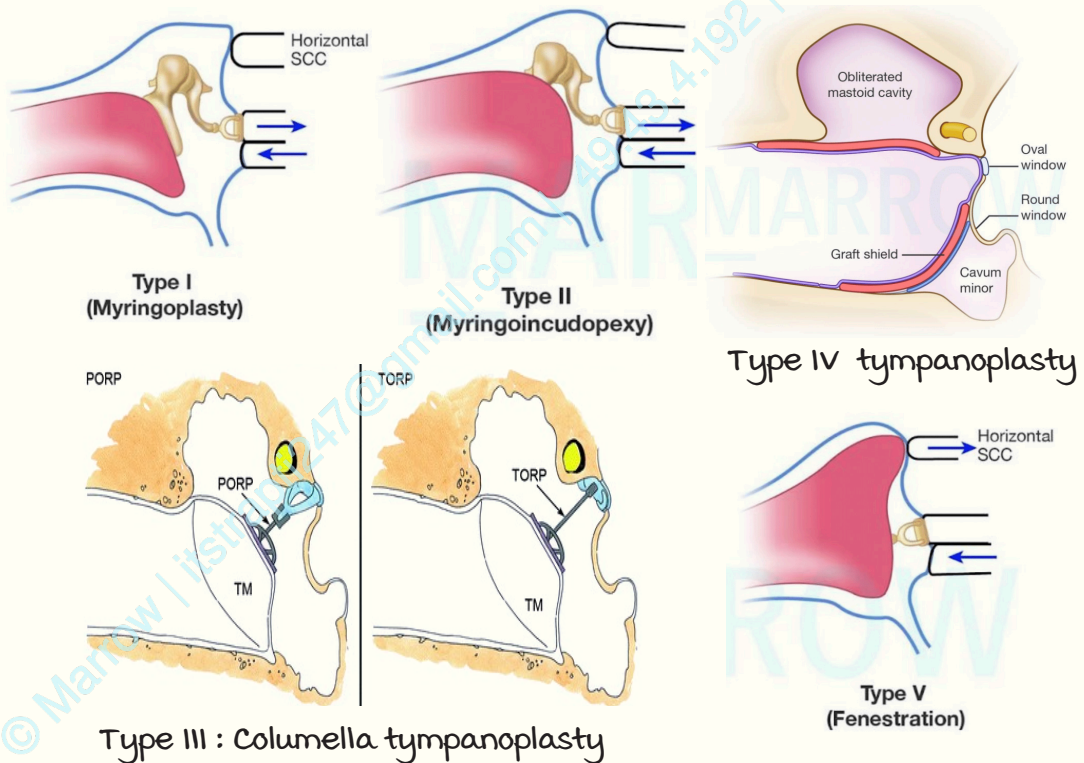


Self retaining hemostatic mastoid retractor

----- Active space -----

- mc graft used : **Temporalis fascia graft.**
- Placement of graft :

Wullstein classification of tympanoplasty	
Type 1/ myringoplasty	Tm placed over malleus.
Type 2	Tm grafted over incus.
Type 3/Columella tympanoplasty/ myringostapediopexy	Tm grafted over stapes.
Type 4/Round window shielding/ cavum minor	Oval window exposed to external environment (To maintain phase difference).
Type 5/ fenestration	Opening made in lateral SCC. Fistula test + (Obsolete now).



myringoplasty :

Overlay : Graft **over (lateral)** to fibrous layer and annulus.

Underlay : Graft **under (medial)** to fibrous layer and annulus.

In both : Graft is under malleus.

Austin's classification of ossicular chain abnormality :

Based on presence of malleus handle (m) & Stapes suprastructure (S).

----- Active space -----

Type A	m +, S+
Type B	m+, S-
Type C	m-, S+
Type D	m-, S-

- Kartush modification :

O-intact ossicular chain

E-Ossicular head fixation

F-stapes fixation

© Marrow | itstrapi247@gmail.com | 49.43.4.192 | 2023-08-30

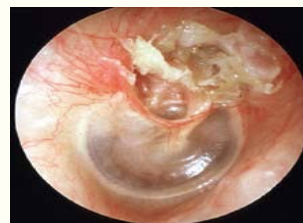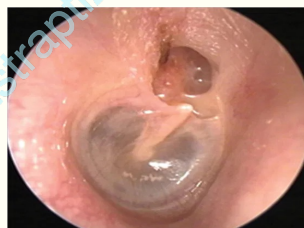----- Active space -----

## ENT REVISION 2

### Cholesteatoma

00:02:37

Cholesteatoma	Theory/criteria	Develops from	mc site
Congenital	Levensons criteria	Congenital cell rests	Antero-superior quadrant of middle ear
Primary acquired	1. Wittmaacks theory (mc route)	1. Invagination of epithelium through retraction pocket	Pars flaccida/ attic/prussaks space f/b posterosuperior part of pars tensa
	2. Sade's	2. Squamous metaplasia	
	3. Ruedi's	3. Basal cell hyperplasia	
Secondary acquired	Habermanns theory (mc) Sade's	migration through marginal perforation	Posterosuperior marginal perforation of pars tensa



Cholesteatoma

TOS classification for Pars flaccida retraction :

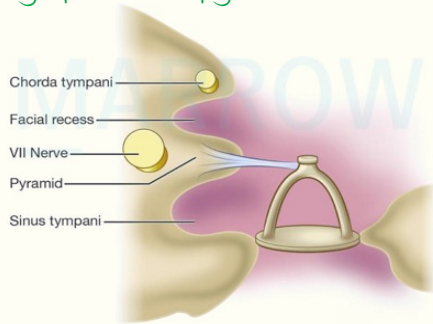
stage 1	Pars flaccida is retracted (dimpled) not adherent to malleus.
stage 2	Retraction pocket adherent to neck of malleus.
stage 3	Part of the retraction pocket may be hidden ,may be associated with erosion of the outer attic wall (scutum).
stage 4	erosion of scutum +, full extent of retraction pocket not seen.

management of squamous otitis media

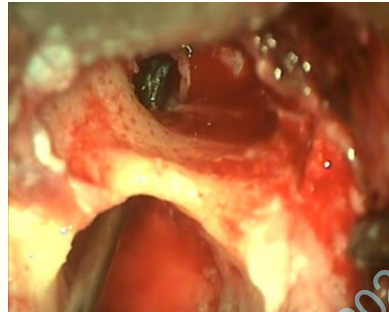
00:07:08

- Aim : Safe, dry, hearing ear.

Sinus tympani/infrapyramidal recess : mc site for residual disease



Facial recess and sinus tympani



mastoidectomy

Surgery → Features :	Intact canal wall	Canal wall down
Visualization	Limited	Good
Chorda tympani	Preserved	Sacrificed
Healing	Fast	Slow
Tolerance to water	better	Avoid water entry
Cavity problems	Absent	Requires periodic cleaning
Hearing aids	well tolerated	Problematic
Residual disease	more	Less

Canal wall down surgeries	Radical mastoidectomy	modified radical mastoidectomy
Posterior bony EAC wall	Removed	Removed
extent of removal of middle ear structures	Only stapes footplate preserved	Healthy mucosa, Tympanic membrane and ossicles preserved
Eustachian tube closed	Closed	Not closed
Reconstruction (tympanoplasty)	No	Yes

Facial recess/suprapyramidal recess :

Significance : Posterior tympanotomy.

----- Active space -----

Complications of otitis media :

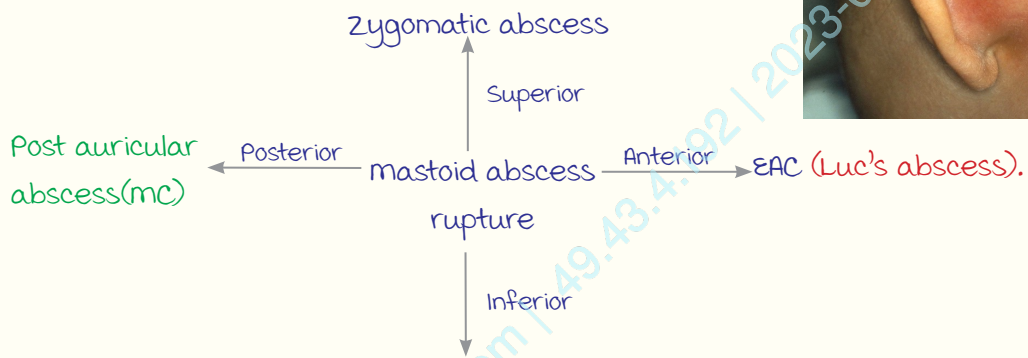
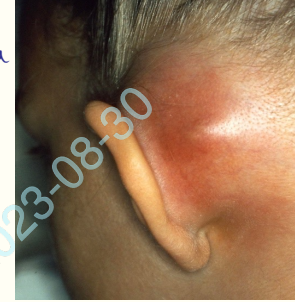- Intratemporal : mastoiditis, labyrinthitis, petrositis, Facial nerve palsy
- Intracranial : Extradural abscess, subdural abscess, meningitis (mc intracranial complication), temporal/cerebellar abscess, Sigmoid sinus/ lateral sinus thrombosis.

**Acute mastoiditis :**

c/f : Child with fever, ear discharge, post auricular oedema

O/E :

EAC : Reservoir sign, Sagging of postero-superior meatal.



- In relation to SCM (Bezold abscess).
- Posterior belly of digastric (Citelli abscess).

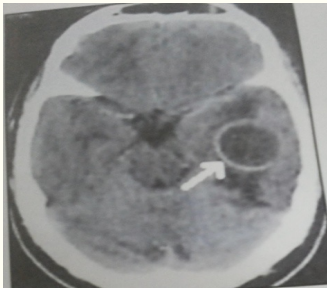management : Simple mastoidectomy/cortical mastoidectomy/Schwartz operation.

IV antibiotics

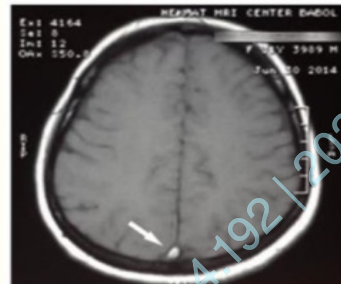
Complication	Presentation & management
Petrositis	Ear discharge + retro orbital pain (5 <sup>th</sup> nerve) + Diplopia (6 <sup>th</sup> nerve) - Gradenigo triad
Labyrinthitis	Features of Om + mixed HL, vertigo. mx : Labyrinthine sedatives IV antibiotics f/b COM-mRM
Facial palsy	Features of Om + facial deviation to normal side. mx : mRM with facial decompression
Temporal lobe abscess	Features of Om + headache/nominal aphasia/homonymous supra quadrantanopia/seizures/contralateral hemiparesis. CT showing ring enhancing lesion in temporal lobe. mx : Drain + IV antibiotics+ mRM when patient is stable

----- Active space -----

Lateral sinus thrombophlebitis	<ul style="list-style-type: none"> <li>• Hectic/picket fence fever.</li> <li>• Griesingers sign : Tenderness and edema over mastoid.</li> <li>• mastoid emissary vein thrombosis.</li> <li>• Tenderness on neck over the IJV.</li> <li>• Tobey ayer test/Queckenstedts test : +ve.</li> <li>• Crow beck sign : +ve.</li> <li>• CT/MRI : Delta/empty triangle sign.</li> </ul>
--------------------------------	---

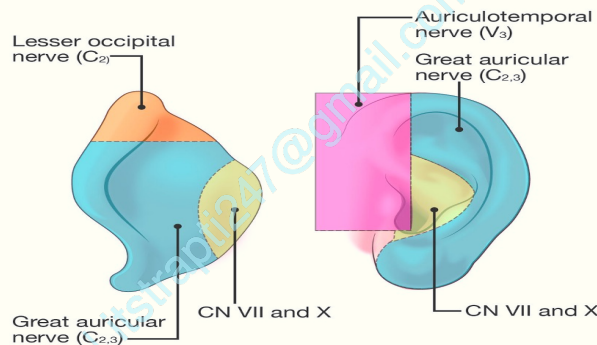


Temporal lobe abscess



Lateral sinus thrombophlebitis

**Nerve supply of pinna (GOAA-F):**



**Nerve supply of middle ear and EAC :**

- Sensory supply to middle ear : Jacobson's nerve (Branch of cranial nerve IX).
- Posterior & inferior part of EAC : Arnold's nerve (Auricular branch of vagus nerve).
- Anterior & superior part of EAC : Auriculotemporal nerve.

Pain referred to the ear from :	Nerve responsible :
Tm joint & dental, parotid conditions, anterior 2/3rd of tongue	Auriculotemporal (v3)
Base of tongue or tonsils (Oropharynx)	Glossopharyngeal (IX) (Jacobson's)

----- Active space -----

Carcinomas of the larynx (Cough while cleaning ear) and hypopharynx, thyroid.	vagus (X) (Arnolds/Alderman's)
Cervical spine degenerative conditions, parotid fascia.	Greater auricular (C2, 3) (numbness following parotidectomy) Lesser occipital nerve

Note :

**Hitselberger sign** (Acoustic neuroma) :

Anesthesia on posterosuperior part of external auditory meatus.

Supplied by : Facial nerve (nervus intermedius of Wrisberg).

Syringing :

Temp : 37 degree C.

Direction of water : Postero superior.

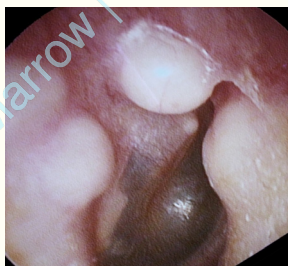Direction of ear pull : Postero superior.

Contraindication : 1) Tm perforation.

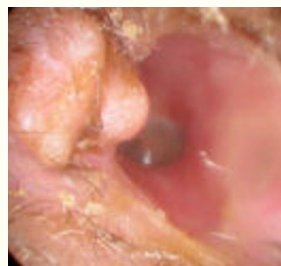2) Foreign body (Batteries).

**Conditions causing HL without pain and discharge :**

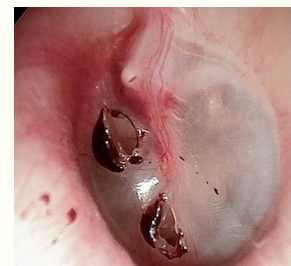1. Surfers ear/exostosis : MC benign tumor of EAC.  
O/E : multiple bony outgrowths seen in EAC.
2. Osteoma: Single bony outgrowth in lateral part of EAC.
3. Ruptured Tm following trauma : Conservative mx done—heals in two layers (By 3 months).



Surfers ear/exostosis



Osteoma



Ruptured Tm

**Tuning fork tests/subjective tests :**

- Speech frequencies: 500, 1000, 2000.
- Tuning fork can test: 256 Hz, 512 Hz (m/c used), 1024 Hz.

00:46:13

Rinne's test :

----- Active space -----

Test	Type of hearing loss	Conditions
Rinne's +ve	AC > BC	Normal SNHL
Rinne's -ve	BC > AC	CHL
False -ve	W/L	Severe SNHL (> 70 dB WHL).

- Rinne at different frequencies gives an approximate idea of hearing loss in the patient :

unable to hear (Hz)	Hearing loss (dB)
256	15
512	30
1024	45

Weber's test : BC is tested.

(mnemonic: **SoCs**)

SNHL : Lateralised to opposite ear (better ear).


CHL Lateralised to same side (worst ear).

If webers to right : Right CHL or Left SNHL.


- Weber lateralises if difference between both ears is minimum-5db.

Other tests :

Absolute Bone Conduction (ABC) : Only sensory neural pathway



Schwabach test : Tragus not covered.



Gelles test : Change in hearing with change in EAC pressure.

Normal/SNHL : +ve.

Ossicular fixity (Otosclerosis) : -ve.

Bing test : Change in hearing on pressing and releasing tragus.

Normal/SNHL : +ve.

CHL : -ve.

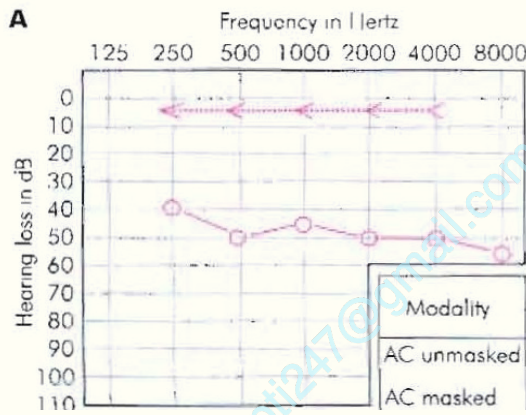
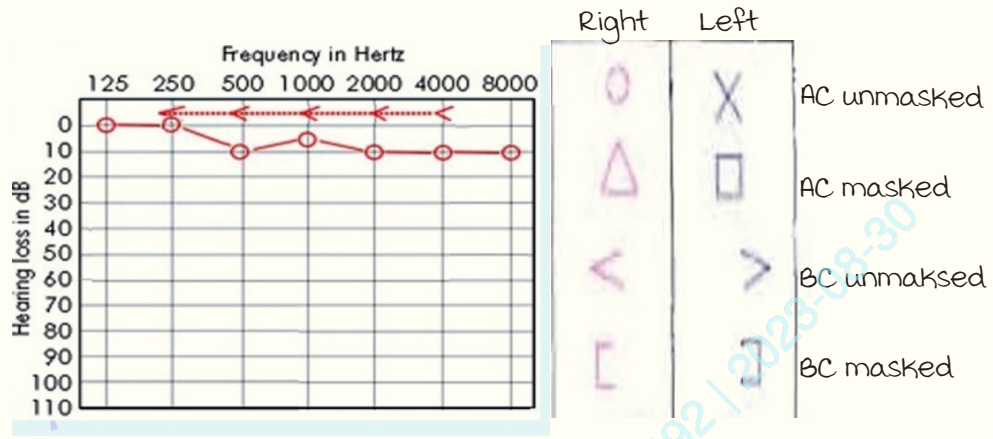
----- Active space -----

**Pure tone audiometry :**

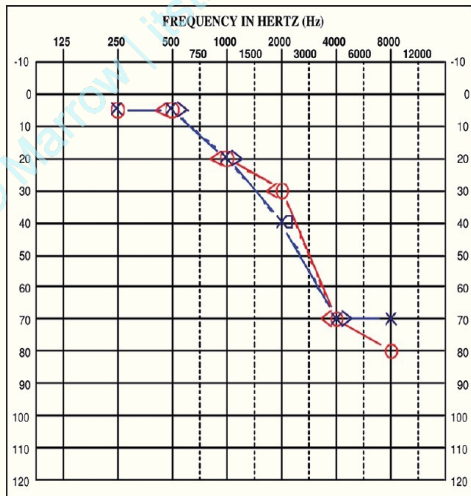
Subjective test of hearing.

usually : Right ear : Red, Left ear : Blue.

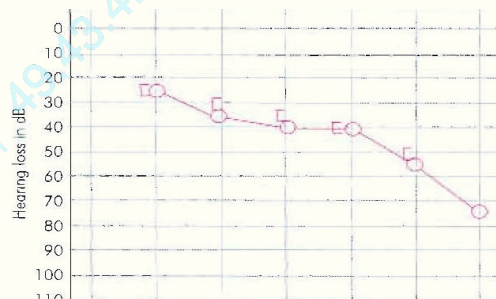
upto 25 dB : Normal hearing.



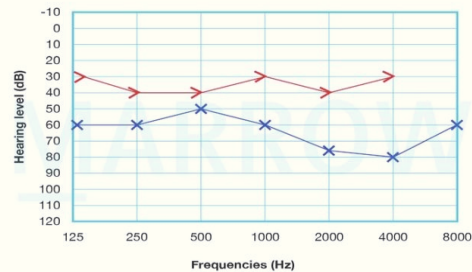
Rt CHL : AB gap with normal BC.



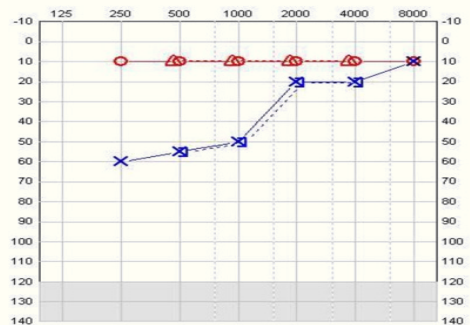
B/L SNHL (Downsloping curve - presbycusis, ototoxicity, late noise induced hearing loss)



Rt SNHL

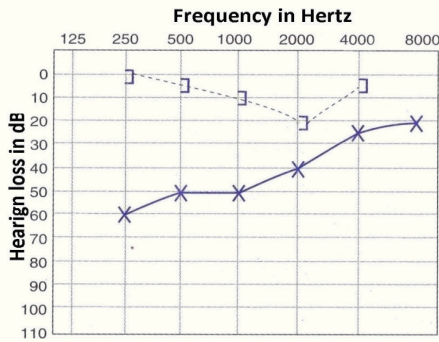


Lt mixed hearing loss : Defective BC + AB gap.

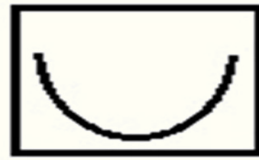

Early menieres disease

----- Active space -----



Carhart's notch  
(Otosclerosis)



**U-SHAPED  
COOKIEBITE**

Cookie cutter audiogram  
(congenital SNHL)

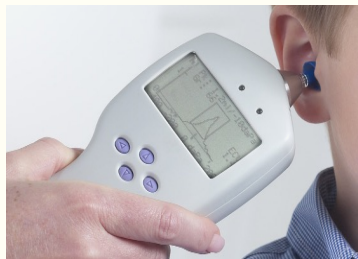ASHA classification of hearing loss :

Grade	Hearing loss
0 : None	25 dB or better.
1 : Slight	26-40 dB
2 : moderate	41-60 dB
3 : Severe	61-80 dB
4 : Profound, including deafness	81 dB or greater

WHO classification of hearing loss :

Category	Hearing loss
mild	26-40 dB
moderate	41-55 dB
moderately severe	56-70 dB
Severe	71-90 dB
Profound	> 91 dB

Impedence audiometry : Tympanometry + stapedial reflex.



Objective test of hearing

----- Active space -----

Curve	Condition
A	Normal
As	Otosclerosis/tympanosclerosis
Ad	Ossicular discontinuity
B	SOM
C	Early ET obstruction
Flat	Perforation, fluid in middle ear.

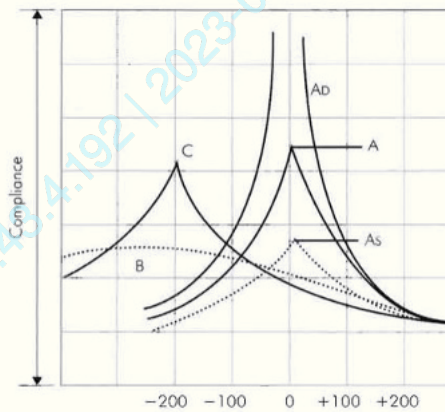
Note : Best investigation to find out ET function : Tympanometry

### Stapedial reflex :

- Protective mechanism of inner ear against noise trauma.
- Afferent : 8th nerve (I/L).
- Centre : Superior olivary complex.
- Efferent : 7th nerve (B/L).
- B/L reflex.

### Significance :

- Absent in CHL.
- Threshold of reflex decreased in cochlear hearing loss.
- Decay of reflex in retrocochlear hearing loss.
- malingering can be tested.
- Best test for malingering : **BERA**.



## ENT REVISION 3

----- Active space -----

### Otitis media with effusion (Serous otitis media)

00:01:04

	Children	Adults
m/c cause	Adenoid hypertrophy.	Nasopharyngeal Ca.
Clinical features	B/I fluctuating painless Hearing loss (HL), speech delay, snoring.	u/I progressive HL.

O/E : Dull, bluish, retracted tympanic membrane (Tm) with fluid levels & air bubbles.

Ix :

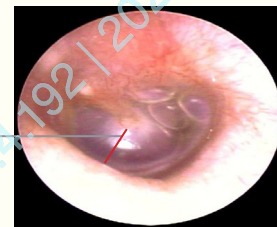
Tuning fork tests → Conductive Hearing Loss (CHL).

Pure Tone Audiometry (PTA) → CHL.

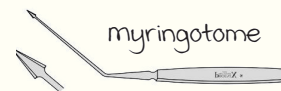Best : Tympanometry → B type curve.

mx :

- 1<sup>st</sup> line → medical (3 months).
- Sx : Adenoidectomy + myringotomy (Radial incision in anteroinferior quadrant) + grommet insertion.



Tm in OME



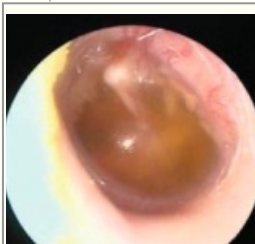Sequelae : Retraction pockets → Primary cholesteatoma.

Retracted Tm

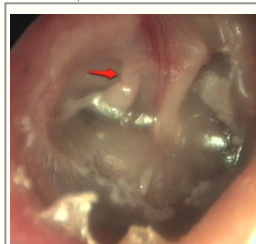
Pars tensa : Sade's classification

Pars flaccida : Tos classification

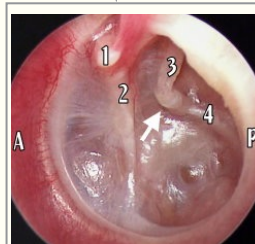
(Leads to 1° cholesteatoma)



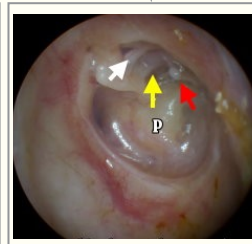
Stage 1 : Retracted Tm, not touching incus



Stage 2 : Touches Incudostapedial joint.



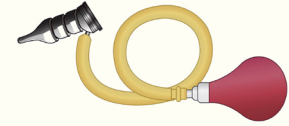
Stage 3 : Atelectasis (Touches promontory)



Stage 4 : Adhesive otitis media

----- Active space -----

Note : Stage 3 & 4 can be differentiated by pneumatic otoscopy/siegelisation.



Siegel's speculum

## Otosclerosis

00:11:30

Origin : Fissula ante fenestram (Otic capsule).

Aggravating factors : Females, post pregnancy.

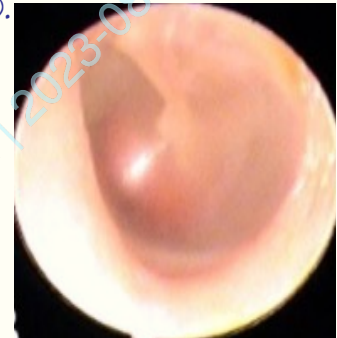
History of similar illness in mother (Autosomal dominant).

C/F :

B/L progressive HL.

O/E :

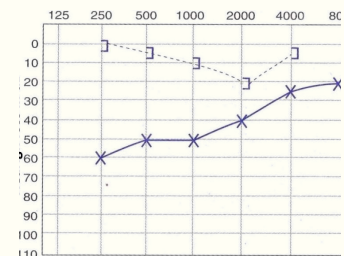
- Tm normal/Schwartz sign (10%).
- Tuning fork tests : CHL.
- Gelle's test : -ve.



Flamingo pink app.  
Schwartz sign

Ix :


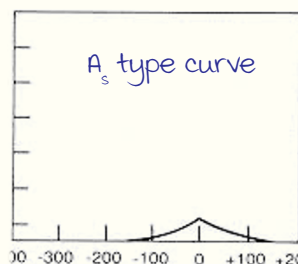
- PTA : CHL (Bone conduction curve : Carhartz notch).
- Rarely : mixed/SNHL (Cochlear otosclerosis).
- Tympanometry (Best) :  $A_s$  type curve.
- Stapedial reflex (-).



Carhartz notch @ 2000Hz

mx :

- Active (Schwartz sign +) : NaF.
- mature : Stapedotomy + teflon piston (Worse ear treated first).
- C/I for surgery : Only one hearing ear → mx with hearing aid/cochlear implant.



Teflon piston

**Glomus tumor**

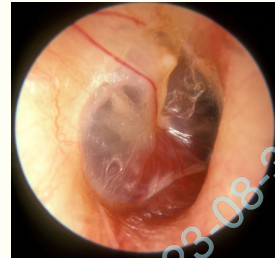
00:17:42

----- Active space -----

Origin : Paraganglioma (Usually non chromaffin) ————  
 { Jugular bulb (CN 9, 10, 11) : Glomus jugulare  
 { Tympanic plexus : Glomus tympanicum (m/c)

c/f :

- Pulsatile tinnitus + CHL.
- Aquino sign (Glomus jugulare) : Tinnitus disappear on carotid compression.
- Brown's sign/pulsation sign : On siegalisation.



Rising sun/red reflex

Ix :

- cECT (Best) → Phelp's sign : erosion of crest of bone b/w ICA & jugular bulb.
- Preop Ix : urinary VMA ↑ as 10% tumors are multicentric.

mx :

- Slow growing tumors → Observation.
- Small tumors → Stereotactic radiosurgery.
- Surgical excision.

Note : Classification of jugulotympanic paragangliomas : Fisch classification.

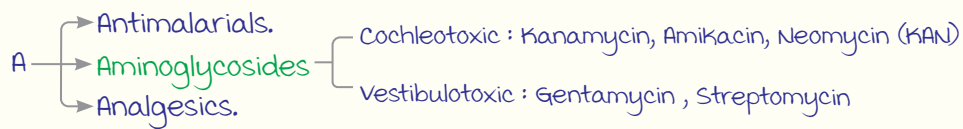
**Conditions presenting as SNHL**

00:22:35

Condition	Presentation	PTA	mx
Noise trauma B/L	H/o noise exposure. Safe : 85 dB, 8 hr/d 5 d/wk.	<ul style="list-style-type: none"> <li>• Early : Acoustic dip @ 4000Hz.</li> <li>• Late : Down sloping curve.</li> </ul>	<ul style="list-style-type: none"> <li>• Prevention of NIHL &amp; ototoxicity by early diagnosis : Distortion product otoacoustic emission (DPOAE).</li> </ul>
Ototoxicity	H/o ototoxic drug intake.	Down sloping curve (High frequency HL).	<ul style="list-style-type: none"> <li>• Rehabilitation : Hearing aid, cochlear implant.</li> </ul>
Presbycusis	Elderly, slowly progressive HL.		
Sudden severe SNHL (Otologic emergency) u/L	Sudden HL. No significant history. Tuning fork tests : • Rinne : -ve. • Weber : Lateralises to opposite ear.	>30 dB SNHL in 3 continuous frequencies, over 3 days.	<ul style="list-style-type: none"> <li>• Steroids.</li> <li>• Carbogen, hyperbaric O<sub>2</sub>.</li> <li>• Rehabilitation : Bone Anchored Hearing Aid (BAHA).</li> </ul>

----- Active space -----

Note : Ototoxic drugs (AVCD).



V : Vancomycin.

C : Cytotoxic drugs.

D : Diuretics.

Neomycin : most cochleotoxic.

Aminoglycosides & cytotoxic drugs → Irreversible HL.

## Acoustic neuroma

00:27:45

m/c benign tumor of cerebellopontine (CP) angle.

Origin : Internal acoustic meatus (Schwannoma of vestibular nerve).

Very slow growing tumor.

C/F :

u/L SNHL (Slow progression) + tinnitus in elderly (b/L & young in NF2).

Nerve involvement :

1. CN 8 followed by CN 5 (Earliest sign : Loss of corneal reflex).
2. Hitzelberger sign (CN 7) : Anaesthesia of posterosuperior part of external auditory canal.
3. CN 5, 6 : At upper pole of CP angle.
4. CN 9, 10, 11 : At lower pole of CP angle.

Ix :

PTA : u/L or asymmetrical SNHL.

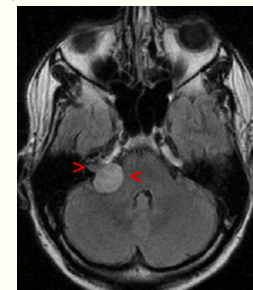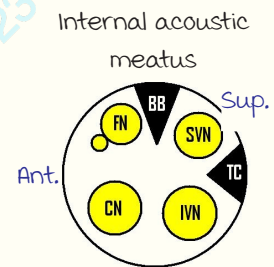
BERA (Best audiometric test).

1. Interaural latency of wave V > 0.2 ms.
2. ↑ Latency b/w waves I-V.

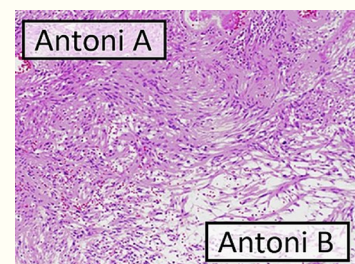
MRI : Best investigation (Ice cream cone appearance).

mx :

- Slow growing → Observation.
- Cystic tumors (Antoni B on histology) → Sx.
- Postop rehabilitation → Auditory Brainstem Implant (ABI) placed in lateral recess of 4th ventricle.



MRI showing icecream cone appearance



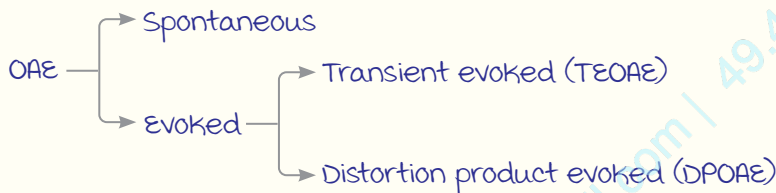
HPE of acoustic neuroma

## Neonatal hearing screening

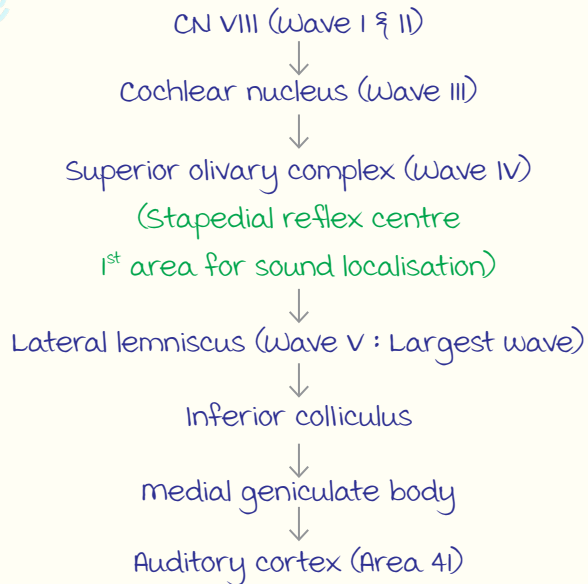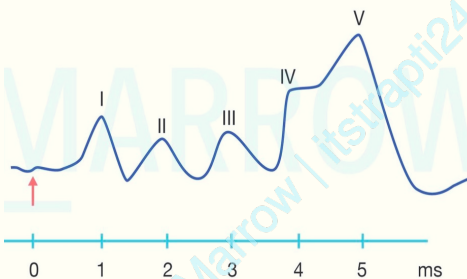
00:39:10

----- Active space -----

Otoacoustic emission (OAE)	BERA
Objective test.	Objective test.
Formed by <b>outer hair cells</b> . Tests middle and inner ear.	Tests auditory pathway.
Best screening test for neonates.	Best <b>screening test for neonates in ICU</b> .
Other uses : 1. Distortion Product OAE (DPOAE) : <b>Ototoxicity</b> . 2. To differentiate b/w cochlear and retrocochlear HL.	Best audiometric test to : 1. Confirm HL in neonates. 2. Find hearing threshold. 3. Differentiate b/w cochlear & retrocochlear HL. 4. For malingering (Non organic HL). 5. For acoustic neuroma.



Auditory pathway & BERA waves :



----- Active space -----

Testing protocol for HL in children :

Age group	Initial test
5-24 months	Behavioral observation audiometry : Free field/visual reinforcement audiometry.
2-5 years	Behavioural observation audiometry : Play audiometry.
> 5 years	PTA.

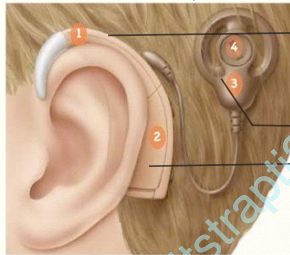
If abnormal → OAE → BERA.

Cochlear implant :

00:58:34

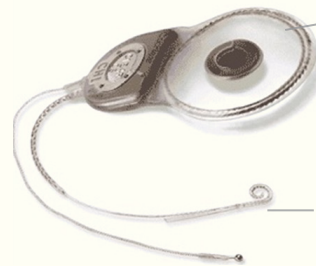- Replaces organ of Corti : Stimulates auditory nerve.
- Indication : B/L severe to profound HL (No benefit by hearing aid trial).
- Insertion : mastoid → Facial recess → middle ear → Round window → Scala tympani (Inner ear).
- C/I : michel aplasia, central auditory lesions.
- Should be implanted as early as 1 year of age.

External component



Speech Processor  
Transmitter coil  
Microphone

Internal component



Receiver  
Transmitter  
Electrodes

# ENT REVISION 4

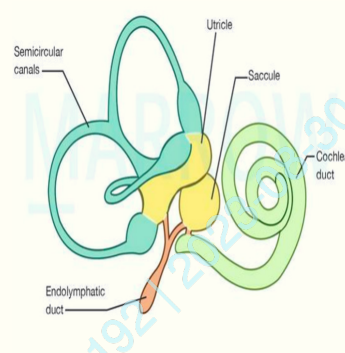
----- Active space -----

## Inner ear anatomy

00:00:19

### membranous labyrinth :

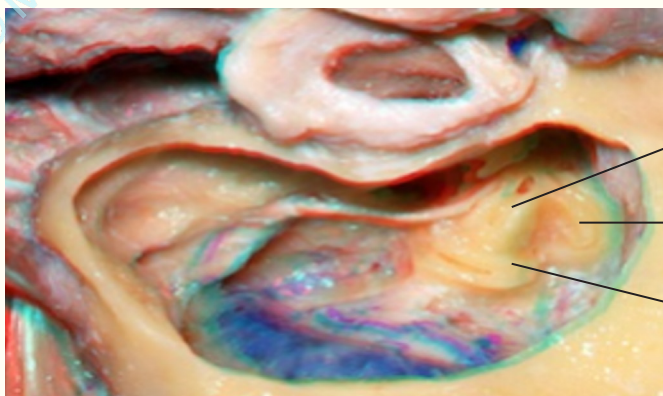
- 3 Semicircular canals : Contain cristae → detects rotational acceleration.
- Utricle and saccule : Contain maculae → detects linear acceleration, gravitational and head tilt movements.
- Utriculo-saccular duct : Helps in absorption of endolymph by forming the endolymphatic duct which ends into endolymphatic sac.
- Scala media/cochlear duct : Coiled tube → takes a  $\frac{1}{a}$  to a  $\frac{3}{4}$  turns around the modiolus.
  - a. Contains Organ of Corti.
  - b. Basal turn : High frequency sounds.
  - c. Apical turn : Low frequency sounds.



membranous labyrinth

### Bony labyrinth :

- Vestibule : Present around utricle and saccule.
- Apex : Helicotrema → Scala vestibuli and Scala tympani communicate with each other.
- Cochlear aqueduct : Connects inner ear to CSF (CSF forms perilymph in inner ear).



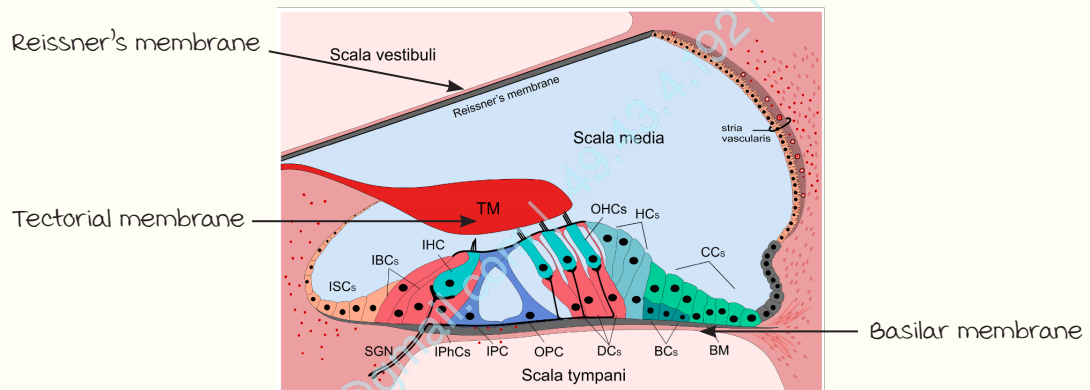
View of SCC from mastoid.

----- Active space -----

Organ of corti :

- **Outer hair cells (OHC)** : more prone to damage by noise and ototoxic drugs.
- **Inner hair cells** : Single row, less prone to damage, release **glutamate** (excitatory neurotransmitter).
- Endolymph vs perilymph.

Features	Endolymph	Perilymph
Present in	Scala media	Scala vestibuli, scala tympani.
Electrolyte concentration	High $K^+$ (similar to ICF) Note : Endolymphatic potential : +80 - 85 mV	High $Na^+$ (similar to ECF)
Secretion	Stria vascularis	From CSF



## Vestibular function test

00:10:13

### I. Nystagmus :

Direction → determined by the fast component.

Peripheral nystagmus :

Characteristic	Findings
Latency	Present
Duration	1.5 to 2 min
Fatiguability	Present
Optic fixation	Nystagmus disappears
Vertical canal nystagmus (posterior/superior SCC)	Vertical nystagmus with torsion
Horizontal canal nystagmus (lateral SCC)	Horizontal nystagmus with torsion

Nystagmus in hyperactive and hypoactive lesions :

----- Active space -----

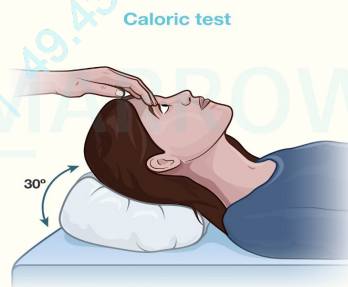Lesion	Conditions	Nystagmus
Hyperactive (involve only 1 SCC at a time)	BPPV	<ul style="list-style-type: none"> <li>Horizontal/Vertical nystagmus</li> <li>Towards same side of lesion.</li> </ul>
Hypoactive (can involve all 3 SCC at a time)	<ul style="list-style-type: none"> <li>Vestibular neuritis</li> <li>Labyrinthitis</li> <li>meniere's disease (late stages)</li> </ul>	<ul style="list-style-type: none"> <li>Horizontal nystagmus</li> <li>Towards opposite side of lesion.</li> </ul>

2. Head impulse test :

- To differentiate between hyperactive and hypoactive lesions.
- Tests vestibulo ocular reflex (VOR).
- Abnormality of labyrinth : **Saccades (+)** in hypoactive lesions.

3. Bithermal caloric test :

- a.k.a Fitzgerald Hallpike maneuver.
- Lateral SCC stimulated → Horizontal nystagmus.
- Cold air caloric testing : Dundas grant tube (done in patient with perforated tympanic membrane).



Results : **COWS**

Temperature	Labyrinth	Direction of nystagmus
Cold : 30°C	Hypoactive	Opposite
Warm : 44°C	Hyperactive	Same

4. Fistula test :

- By tragal pressure or seigelisation.

Result	Interpretation
Positive	Fistula on medial wall
False positive/Hennebert sign (Due to close proximity of utricle and saccule with oval window).	<ul style="list-style-type: none"> <li>meniere's disease</li> <li>Hypermobile footplate (congenital syphilis)</li> <li>Superior SCC dehiscence</li> </ul>
False negative	Dead labyrinth

Note : **Tullios phenomenon** : Vertigo in response to loud sound.

----- Active space -----

### 5. Vestibular evoked myogenic potential (VEMP) :

Normal reflex pathway : Loud sound → Saccule → IVN → vestibular nuclei → SCM relaxes.

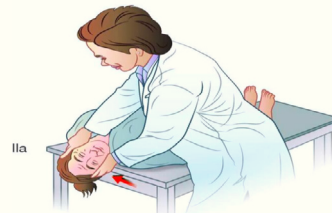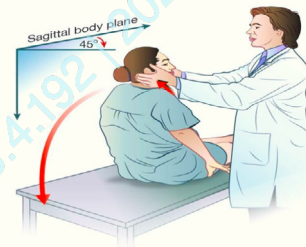
Result	Intepretation
Hyperactive	Fistula, Superior SCC dehiscence, meniere's, hypermobile footplate.
Hypoactive	Vestibular neuritis, acoustic neuroma

## Vertigo with no hearing loss

00:29:35

### I. BPPV :

- Episodic vertigo lasting for seconds in certain head position.
- m/c canal involved :  
Posterior SCC (vertical nystagmus to the same side).
- 2<sup>nd</sup> m/c involved : Horizontal SCC (horizontal nystagmus to the same side).



Semicircular canal	Diagnosis	Treatment
Posterior SCC	Dix Hallpike test	Epleys (best)
Horizontal SCC	Supine roll test	Gufoni and barbecue roll

### a. Vestibular neuritis :

Sudden onset vertigo.

Hearing : normal.

Horizontal nystagmus → towards normal side.

Head thrust test : Saccades present.

cvEMP or ovEMP : Reduced or absent.

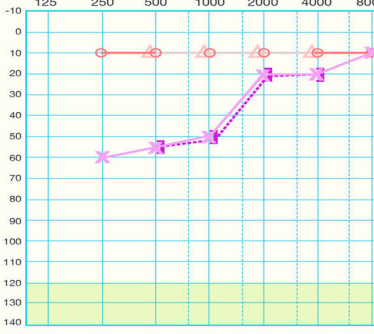
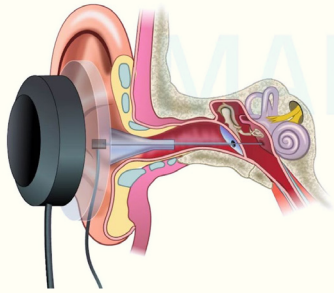
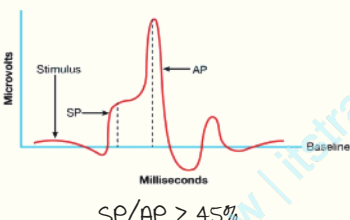
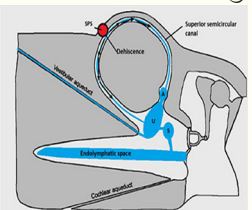
management :

- Labyrinthine sedatives.
- Vestibular rehabilitation excercises.

# Vertigo with hearing loss

00:34:30

----- Active space -----

Condition	Features
<b>A. Vertigo with sensorineural hearing loss.</b>	
<p><b>1. Meniere's Disease</b> (Endolymphatic hydrops)</p>  <p>Upsloping audiogram</p>  <p>ECOG</p>  <p>SP/AP &gt; 45%</p>	<p>Clinical features :</p> <ul style="list-style-type: none"> <li>• Episodic vertigo (20min -24 hrs).</li> <li>• Fluctuating hearing loss, Tinnitus.</li> <li>• Fullness in the ears, Diplacusis.</li> <li>• Recruitment.</li> <li>• Tullios phenomenon &amp; Hennebert sign : Present.</li> <li>• Tumarkin crisis (drop attacks).</li> </ul> <p>Investigations :</p> <ul style="list-style-type: none"> <li>• TFT : SNHL</li> <li>• PTA : SNHL, low frequency first, <b>upsloping audiogram</b></li> <li>• Short increment sensitivity index (SISI) &gt;70%</li> <li>• Stapedial reflex threshold is decreased.</li> <li>• <b>Electrocochleography (ECOG)</b> : best investigation.</li> <li>• <b>Summating potential (SP)/Action potential (AP) &gt;45%</b> : Diagnostic</li> </ul> <p>Medical management :</p> <ul style="list-style-type: none"> <li>• Low salt diet, caffeine restriction.</li> <li>• Labyrinthine sedatives.</li> <li>• Diuretics.</li> <li>• vasodilators like <b>betahistine</b>.</li> </ul> <p>Invasive treatments :</p> <ul style="list-style-type: none"> <li>• Transtympanic steroids through round window.</li> <li>• Chemical labyrinthectomy with vestibulotoxic drugs (<b>Gentamicin</b>).</li> <li>• vestibular neurectomy : Preserves hearing</li> <li>• Endolymphatic sac decompression (below Donaldsons line)</li> <li>• <b>Labyrinthectomy</b> (when no good hearing left).</li> </ul>
<p><b>2. Labyrinthitis</b></p>	<ul style="list-style-type: none"> <li>• Continuous vertigo with hearing loss.</li> <li>• History of <b>otitis media</b> (acute/chronic) or <b>meningitis</b>.</li> <li>• TFT : SNHL/mixed hearing loss.</li> </ul>
<p><b>3. Perilymphatic fistula</b></p>	<ul style="list-style-type: none"> <li>• Follows <b>trauma</b>, surgical or baro/acoustic trauma or erosion by cholesteatoma.</li> <li>• Tullio's phenomenon &amp; Hennebert's sign : Present.</li> <li>• TFT : SNHL/mixed hearing loss.</li> </ul>
<b>B. Vertigo with conductive hearing loss.</b>	
<p><b>Superior SCC dehiscence syndrome</b></p> 	<ul style="list-style-type: none"> <li>• A.k.a third window trauma.</li> <li>• Congenital.</li> <li>• Hennebert's sign and Tullio phenomenon : +ve.</li> <li>• ↑ bone conduction : Able to hear own eye movements, footsteps heard louder, autophony.</li> <li>• TFT : Conductive hearing loss.</li> <li>• Diagnosis : HRCT.</li> </ul>

## Facial nerve

00:50:16

### Segments :

1. meatal segment.
2. Labyrinthine segment : **Narrowest part** of facial nerve.
3. Tympanic/horizontal segment : m/c dehiscent part of facial nerve.
4. Vertical/mastoid segment : m/c injured in mastoid surgery.

### Branches :

Branch	Supply	Effect of transection	Topodiagnostic test
1. Greater superficial petrosal nerve (1 <sup>st</sup> branch at geniculate ganglion)	Lacrimal gland	<ul style="list-style-type: none"> <li>• Dry eye</li> <li>• Hyperacusis</li> <li>• Loss of taste</li> <li>• LMN facial palsy</li> </ul>	Schimers test
2. Nerve to stapedius	Stapedius muscle	<ul style="list-style-type: none"> <li>• Hyperacusis</li> <li>• Loss of taste</li> <li>• LMN facial palsy</li> </ul>	Stapedial reflex
3. Chorda tympani	Taste sensation to anterior 2/3rd of tongue. Gives parasympathetic secretory fibres to sublingual & submandibular salivary gland.	<ul style="list-style-type: none"> <li>• Loss of taste</li> <li>• LMN facial palsy</li> </ul>	Taste test
4. Sensory auricular branch	Sensation to posterosuperior part of external acoustic meatus.	<b>Hitzelberger sign</b> (hypoesthesia in acoustic neuroma)	
5. motor branches at stylomastoid foramen		motor activity of facial muscles lost.	

### Investigations :

- Electrophysiological test : Look for prognosis.
  - a. **Electroneuronography** : Not done before 3 days (Wallerian degeneration).
  - b. **Electromyography** > 3 weeks of facial nerve injury.

### Causes of facial palsy :

- m/c cause of facial palsy : Bell's palsy.
- m/c iatrogenic cause : **Parotid surgery** > mastoid surgery.
- m/c site injured in mastoid Sx : vertical segment.

Bell's palsy :

- A/c onset LMN palsy.
- Idiopathic, viral (60% → HSV-1)
- ↑ susceptibility in diabetes, pregnancy, AIDS.
- m/c site of involvement : Labyrinthine segment.
- Can recur.



----- Active space -----

Treatment :

- High dose steroid : Started immediately.
- Antiviral (Acyclovir/ Valacyclovir) : If patient presented within 3 days.
- Supportive treatment : Physiotherapy, nerve stimulation, eye care, Vitamin B12 nerve nourishers.

management of all types of facial palsy :

- Sudden onset palsy following surgery : Re-exploration and repair.
- Late onset palsy : Steroids.

Note :

- Aberrant regeneration of facial nerve : Crocodile tears/synkinesis.
- Frey's syndrome/ Gustatory sweating : Auriculotemporal nerve damaged.

## Temporal bone fractures

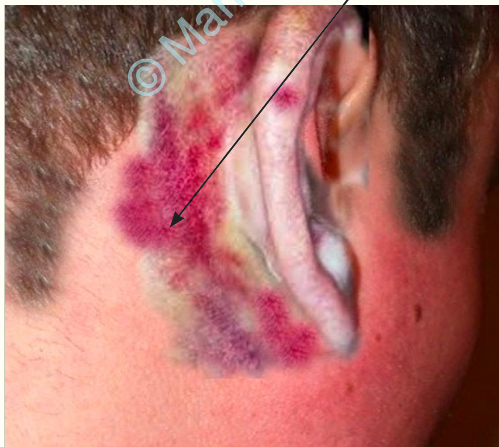00:56:32

Can be parallel (longitudinal) or perpendicular (transverse).

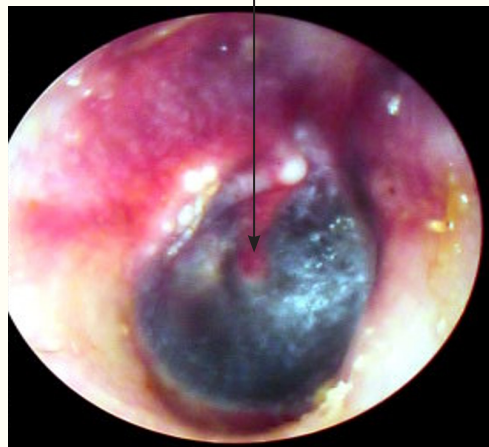
m/c type associated with facial nerve palsy : Transverse > Longitudinal.

Overall m/c type : Longitudinal.

Ecchymosis behind ear : Battle's sign.



Hemotympanum.



IOC : HRCT.

----- Active space -----

## ENT REVISION 5 (NOSE)

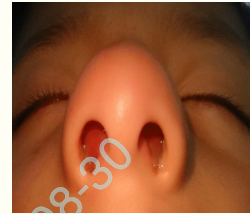### Septal Hematoma

00:02:47

C/F : Nasal obstruction + h/o trauma.

O/E : Smooth rounded swelling on both sides of septum.

management : Emergency → Drainage of hematoma within 72 hours to avoid necrosis/saddling/septal perforation/septal abscess.



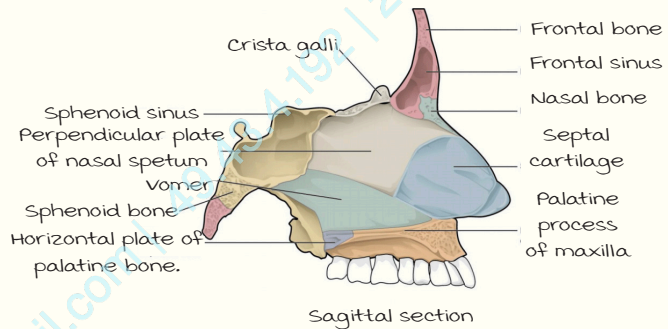
3 parts :

- Columellar.
- Bony (Septum proper).
- Membranous.

Septal cartilage :

- aka Quadrangular/Quadrangle cartilage.
- Supports lower 2/3<sup>rd</sup> part of nose.

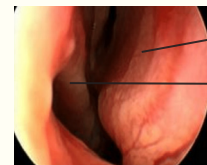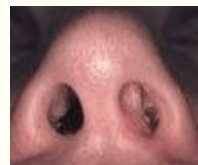#### Anatomy of septum



### Deviated Nasal Septum

00:05:00

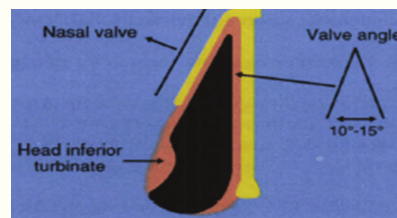
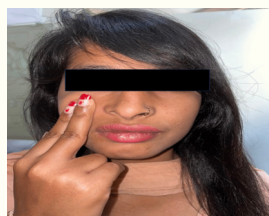C/F : Nasal obstruction ± h/o trauma, recurrent sinusitis, otitis media, epistaxis, hyposmia.



Endoscopic appearance

O/E : Deviation of septum, inferior turbinate hypertrophy (mulberry appearance) on opposite side → leading to paradoxical nasal obstruction.

**Cottle's test** : Test for nasal valve patency. Relief on pulling the cheek laterally confirms nasal obstruction/deviation of septum in nasal valve area.



Nasal valve (narrowest part)

**management :**

Conservative (< 17 yrs) unless very severe obstruction.

Surgery of choice (>17 yrs) : **Septoplasty.**

- **Hemitransfixion/Freer's** incision : At lower border of quadrangular cartilage.
- mucoperichondrial flap is raised completely **only on one side** of the septum.

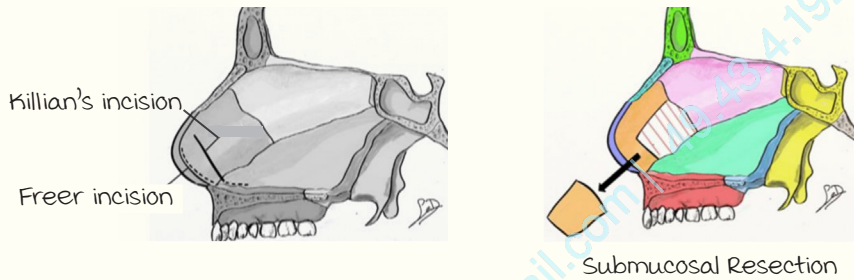
Submucosal Resection (SMR) :

**Killians** incision is made : 1 cm above the lower border of septal cartilage.

mucoperichondrial flaps are raised on **both the sides** to remove most part of septum leaving behind :

- 1 cm strip on upper part of dorsum of the external nose.
- A thin caudal strip (L shaped cartilage).

Complication : Saddle nose.



**Nasal fracture**

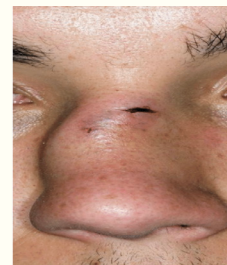00:12:00

m/c fracture of the face.

C/F : Nasal obstruction + Oedema over external nose following trauma.

O/E : Crepitus present, abnormal mobility.

X-ray : Done only in medicolegal cases, d/t high false +ves.

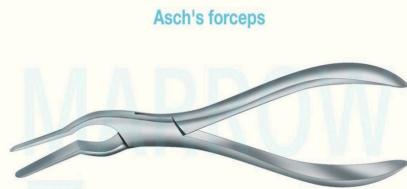
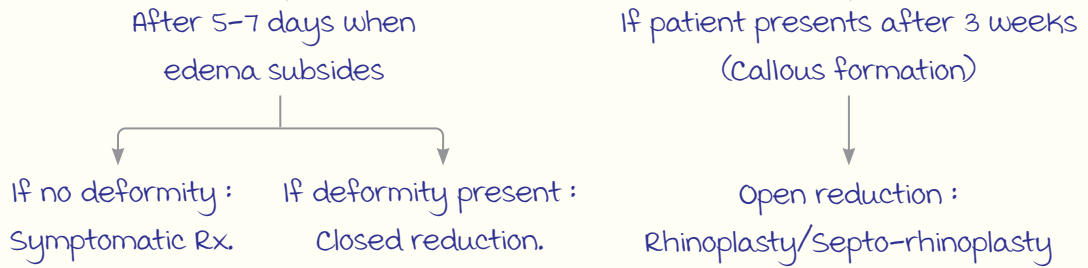


3 types of nasal # :

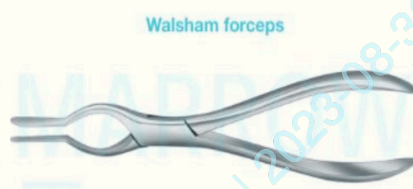Class 1	Class 2	Class 3
<ul style="list-style-type: none"> <li>• aka Chevallet #</li> <li>• Nasal bone # + vertical # of septum.</li> <li>• No deformity.</li> </ul>	<ul style="list-style-type: none"> <li>• aka Jarjaway #</li> <li>• Nasal bone # + Horizontal or C shaped # of septum.</li> <li>• Gross deviation</li> </ul>	<ul style="list-style-type: none"> <li>• Naso-orbitoethmoid #</li> <li>• # of nasal dorsum, perpendicular plate of ethmoid, cribriform plate &amp; lamina papyracea</li> <li>• <b>Pig nose deformity</b></li> <li>• CSF leak.</li> <li>• Immediate open reduction &amp; internal fixation.</li> </ul>

----- Active space -----

management of Class I & 2 fractures

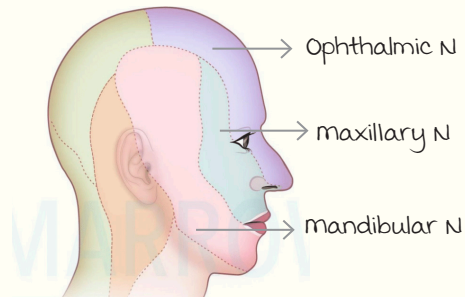
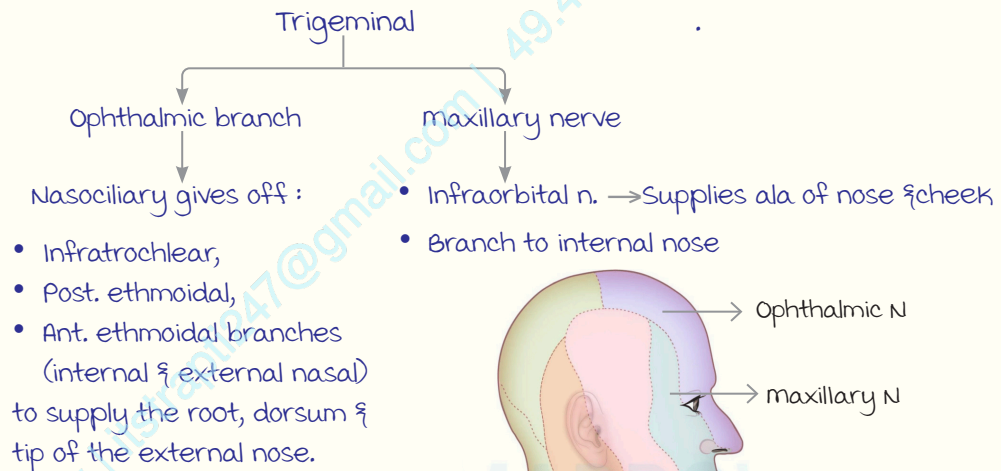


used for Septal reduction

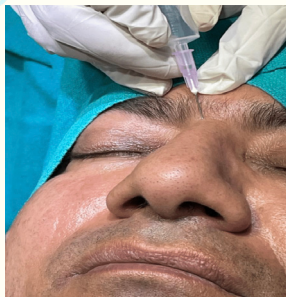

used for bony reduction

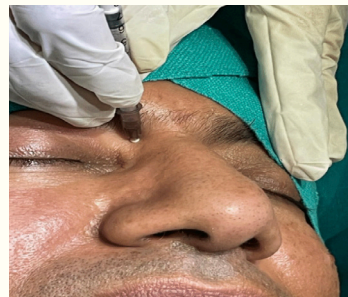Nerve supply of nose :



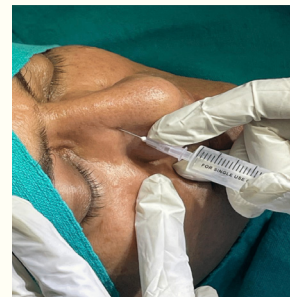Anaesthesia of external nose :



Infratrochlear nerve block at medial end of eyebrow.

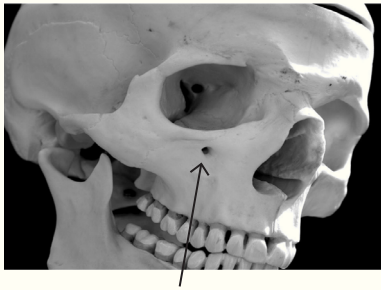


Nasociliary block at 1cm above medial canthus & depth :  
 • 1.5 cm -> Anterior ethmoidal  
 • 2.5 cm -> Posterior ethmoidal

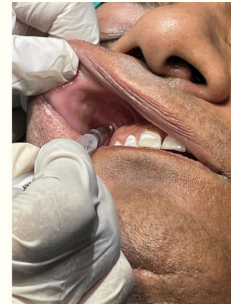
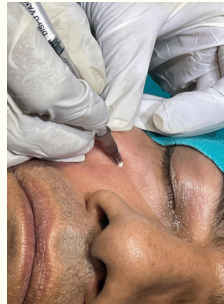
External nasal block

----- Active space -----



Infraorbital foramen through which infra-orbital nerve exits.



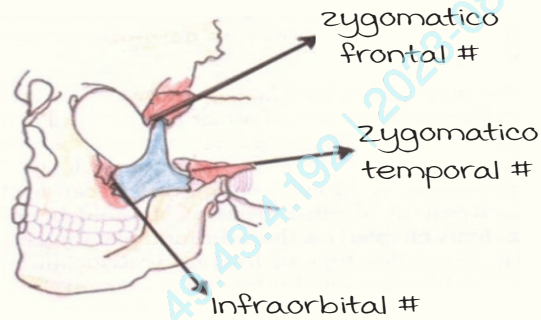
Block at infraorbital foramen

**Infraorbital nerve injury :**

c/c : Anaesthesia of cheek following trauma.

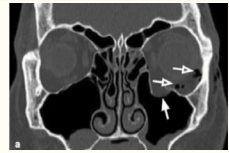
Causes : # of infraorbital foramen.

- Blow out # (# of floor of orbit).
- Tripod # (Zygomatic bone #).
- Le Fort II # : maxillary #.

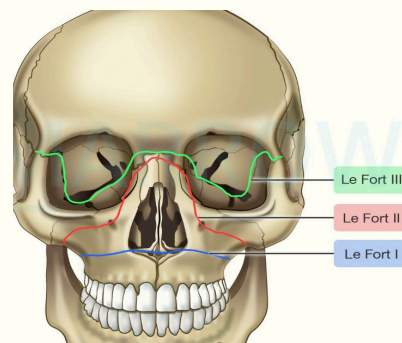


**Facial fracture**

00:26:00

Named #	History & examination
Blow out # / Floor of orbit #	Following injury, patient presents with double vision & anaesthesia of cheek. On CT : <b>Tear drop sign</b> : Orbital fat protruding in maxillary sinus. 
Tripod # / # of Zygomatic bone	Following injury, presents with : <ul style="list-style-type: none"> <li>• <b>Flattening of malar eminence.</b></li> <li>• Anaesthesia of cheek.</li> <li>• Periorbital emphysema.</li> <li>• Step deformity of infraorbital margins.</li> <li>• Restricted ocular movements.</li> </ul> <ul style="list-style-type: none"> <li>• <b>Trismus.</b></li> <li>• <b>Diplopia</b></li> <li>• <b>Enophthalmos</b></li> </ul>

Le Fort I #	aka Guerin's #. # is parallel to the plate. On imaging appears like floating plate/teeth.
Le Fort II #	Pramidal #. Reaching root of nose. On CT : Hanging maxilla. Involves infraorbital nerve.
Le Fort III #	Cranio facial dysjunction.

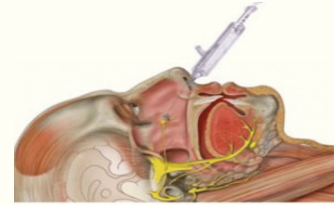


Note : CSF rhinorrhea is seen in Le fort 2, 3 & class 3 nasal #

----- Active space -----

**Anaesthesia of internal nose :**

Internal nose is supplied by branch of maxillary nerve that enters 1 cm behind the middle turbinate (MT) through sphenopalatine foramen. → anaesthetic block is given here..

**Atrophic rhinitis/ Ozaena**

00:34:12

Primary cause : Klebsiella ozaena.

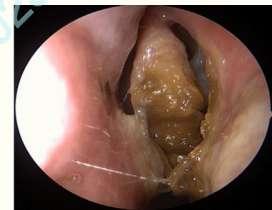
Secondary cause : Granulomatous conditions; Irradiation; Destructive Sx leading to empty nose syndrome.

C/F : B/L nasal obstruction with excessive nasal crusting, bleeding, very foulsmelling discharge (unaware : merciful anosmia), more common in females.

O/E : B/L roomy nasal cavities.

management :

- To remove crusting : Alkaline nasal douching (using NaCl, NaHCO<sub>3</sub>, Na baborate in distill water in ratio 2 : 1 : 1).
- For infection : 25% glucose in glycerine spray ± Antibiotic spray COPD (Chloramphenicol, oestradiol, propylene glycol, vitamin D).
- Surgery to close nasal cavity : Young's/ modified Young's.
- main epithelial lining of nose : Respiratory epithelium/ Ciliated columnar pseudostratified epithelium.
- vestibule of nose lined by : Stratified squamous keratinised epithelium.
- Olfactory mucosa : Present in upper 1/3<sup>rd</sup> of nose; aka dangerous area of nose; Only 10-15% air reaches here during inspiration.



Note :

Terms	Definition
Hyposmia	Reduced smell d/t conduction block
Anosmia	Loss of smell d/t damage to olfactory mucosa/ nerves/ tracts
Parosmia	Perversion of smell (good smell appears bad)
Phantosmia	Perceiving smell in absence of smell
Presbyosmia	Age related loss of smell
Kallmann syndrome	Cong. anosmia with Hypogonadotropic hypogonadism
Alzheimer's, Parkinson's, multiple Sclerosis.	Neurodegenerative diseases

Olfactory Tests :

- UPSIT : university of Pennsylvania smell identification test
- Cross Cultural SIT/ Brief SIT.
- Smell Diskettes.
- Sniffin sticks.

----- Active space -----

**Granulomatous conditions of nose**

00:43:25

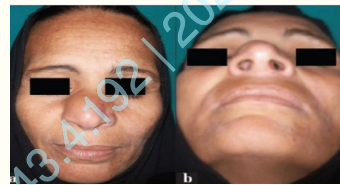**Rhinoscleroma :**

Etiology : Klebsiella rhinoscleromatis/ Frisch bacillus.

C/F : B/L nasal obstruction, excessive nasal crusting, woody/ hard nose.

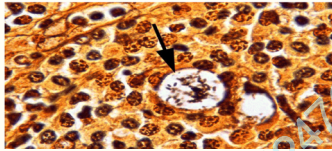
3 stages :

- Atrophic (similar to atrophic rhinitis).
- Granulomatous (hard woody nose).
- Cicatritial stage (Hebra/Tapir nose).

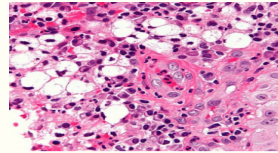


Management :

- Confirmation done on biopsy.
- Ciprofloxacin (DOC), Streptomycin, Tetracycline, Rifampicin.
- Steroids (to reduce fibrosis).



miculicz cells : Foamy macrophages with intracytoplasmic bacilli

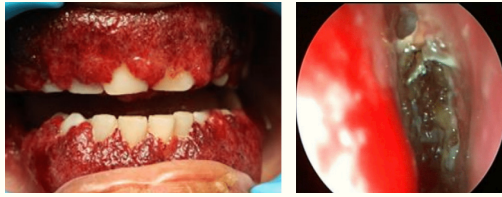


Russell bodies : Plasma cells with eosinophilic inclusion bodies

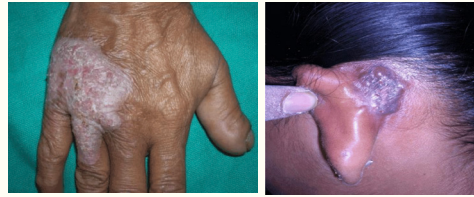**Other granulomatous conditions :**

Diagnosis	Similar C/f	Differentiating features
Granulomatosis with Polyangiitis /Wegner's	B/L nasal obstruction, excessive nasal crusting, blood tinged nasal discharge, saddling. Perforation in cartilaginous septum.	Perforation in bony septum as well. CHL - SOM, strawberry gingiva, cough, hemoptysis & dyspnea, glomerulonephritis, haematuria
Sarcoidosis		Violaceous affection of nose : Lupus pernio. Strawberry nasal mucosa.
Syphilis		Perforation in bony septum as well. Painless indurated ulcer (chancre), Snail track ulcers. Gummas (MC stage where nasal symptoms occur).
TB		Cough, hemoptysis, night sweats, fever. Caseating granulomas with acid fast bacilli.
Leprosy		Skin patches, sensory loss, paresthesia/ numbness in extremities.
Lupus vulgaris (TB skin)		Brownish nodules not blanching on pressure on nose & various body parts (Apple jelly nodules).

----- Active space -----

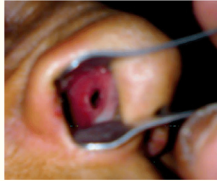
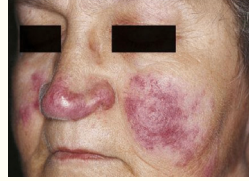
Wegner's Granulomatosis

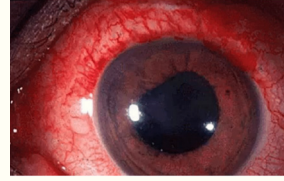


Lupus vulgaris

Sarcoidosis :

Strawberry  
nasal mucosa

Lupus pernio

Heerfordt syndrome :  
B/L enlarged parotid/ salivary glands,  
facial nerve paralysis & anterior uveitis.

## T cell Lymphoma

00:52:00

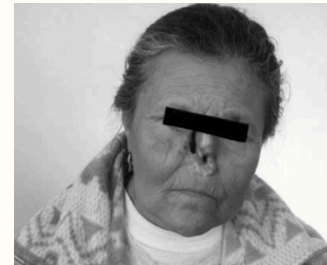aka midline lethal granuloma /NK lymphoma /Stewart's lymphoma.

virus associated : EBV.

m > F; 40-70 yrs.

C/F : B/I Nasal obstruction, blood tinged nasal discharge, and ulceration, necrosis & perforation of septum & midfacial structures.

management : Radiotherapy ± chemotherapy for lymphoma followed by surgical reconstruction of defect.



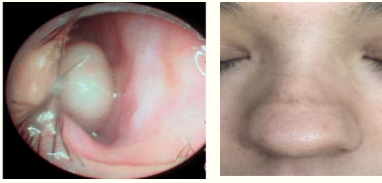

## Rhinitis

00:54:00

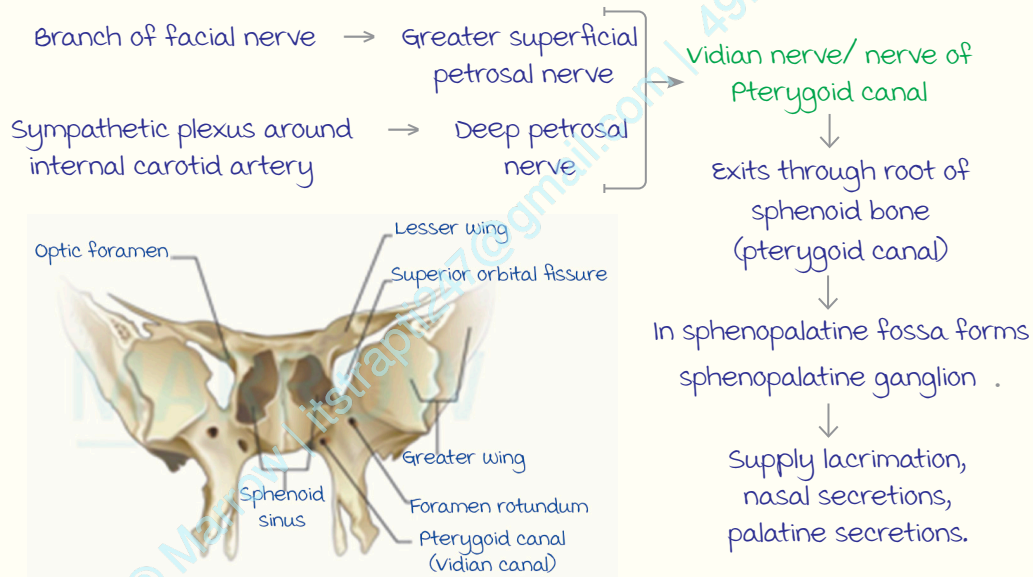
Allergic rhinitis v/s vasomotor rhinitis :

Features	Allergic rhinitis	vasomotor rhinitis
Etiology	Type I HS reaction (IgE mediated)	Parasympathetic overactivity.
C/F	<ul style="list-style-type: none"> <li>Nasal obstruction + nasal discharge (watery)</li> <li>Sneezing/ itching</li> <li>Family history of allergy (+)</li> <li>Allergic salute (+)</li> <li>Dennie morgan lines</li> </ul>	<ul style="list-style-type: none"> <li>aka idiopathic rhinitis.</li> <li>Nasal obstruction + nasal discharge (watery)</li> <li>Sneezing/itching</li> <li>Family history of allergy (-)</li> </ul>
Dx	<p>Anterior Rhinoscopy :</p> <ul style="list-style-type: none"> <li>Pale boggy (swollen) sometimes bluish mucosa</li> <li>Inferior turbinate hypertrophy</li> </ul> <p>RAST or skin prick test.</p>	<p>Anterior Rhinoscopy :</p> <ul style="list-style-type: none"> <li>Congested nasal mucosa</li> <li>Inferior turbinate hypertrophy</li> </ul>

----- Active space -----

Features	Allergic rhinitis	Vasomotor rhinitis
mx	<ul style="list-style-type: none"> <li>• Avoidance</li> <li>• Intranasal steroids</li> <li>• Antihistamines + LT inhibitors</li> <li>• Oral &amp; local nasal decongestants</li> <li>• Saline sprays</li> <li>• Immunotherapy</li> </ul>	<p>medical :</p> <ul style="list-style-type: none"> <li>• Intranasal steroids</li> <li>• Oral or local nasal decongestants</li> </ul> <p>Surgical :</p> <ul style="list-style-type: none"> <li>• Vidian neurectomy</li> <li>• IT reduction</li> </ul>
	 <p>Pale mucosa    Allergic salute</p>	 <p>Inferior turbinate hypertrophy</p>

Vidian's nerve :



Rhinitis medicamentosa :

H/o prolonged use of nasal decongestants resulting in rebound nasal obstruction.

management :

- withdraw nasal decongestant + short course of local or systemic nasal steroid (max 7 days).

## CSF rhinorrhea

01:01:12

C/F:

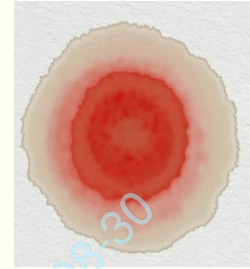
- w/L watery rhinorrhea which increases on leaning forward & patient **unable to sniff it back** ± h/o trauma.
- m/c site : **Lateral lamina of cribriform plate.**
- Handkerchief test : No stiffening.
- Reservoir sign : +ve.
- **Halo sign/target/double ring sign.**

Investigations :

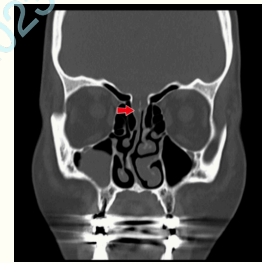
- Best biochemical investigation :  **$\beta 2$  transferrin.**
- Best investigation : **HRCT.**
- Intrathecal fluorescein can also be used.
- For active leak : MRI/CT cisternography.

management :

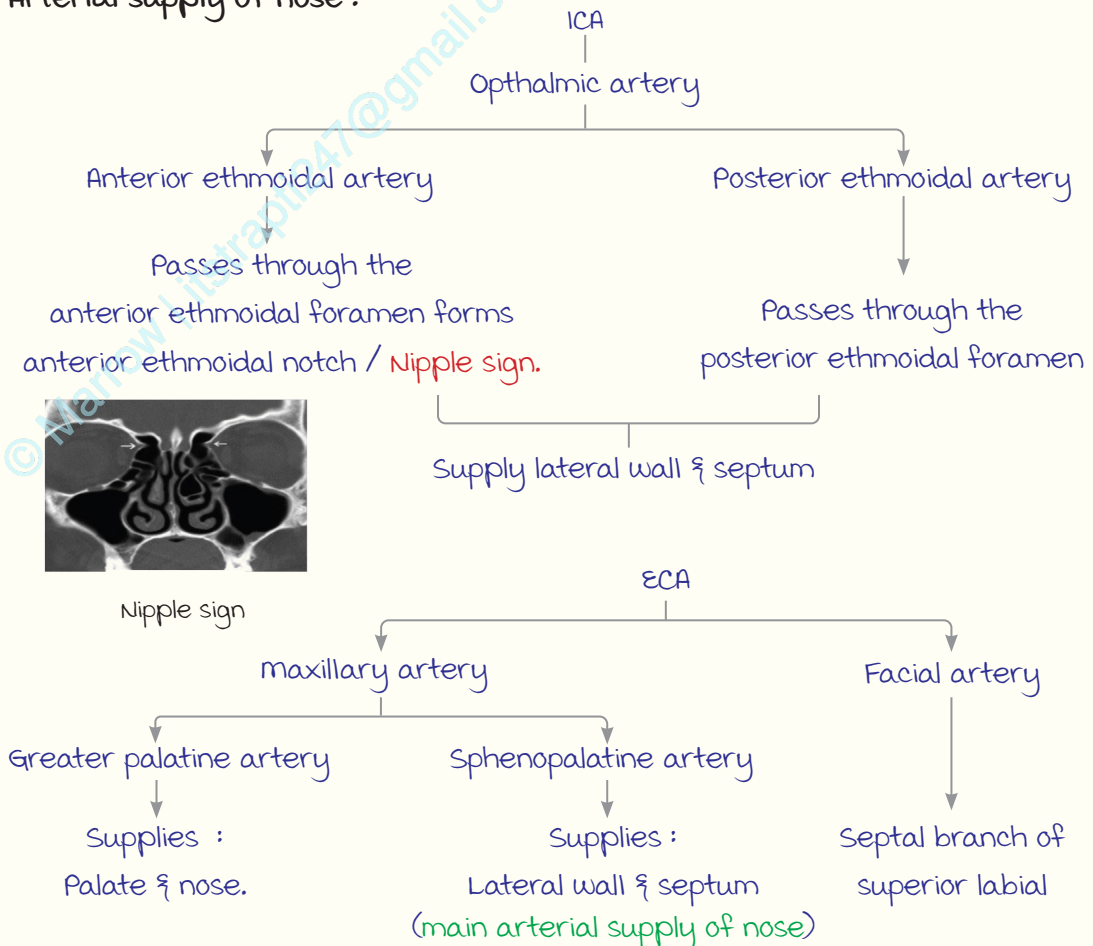
- **Conservative for 10-14 days.**
- If no improvement : Endoscopic/surgical repair.



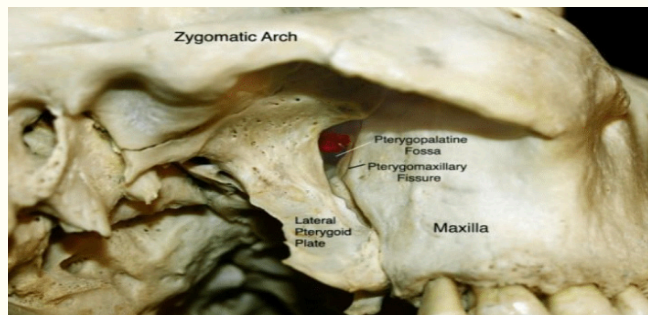
Halo sign



Arterial supply of nose :



----- Active space -----



Orbital Hematoma :

During FESS, injury to anterior ethmoidal artery results → Orbital hematoma. (Emergency condition). managed by immediate ligation of the artery either endoscopically or by external incision (Lynch Howarth incision).

## Epistaxis

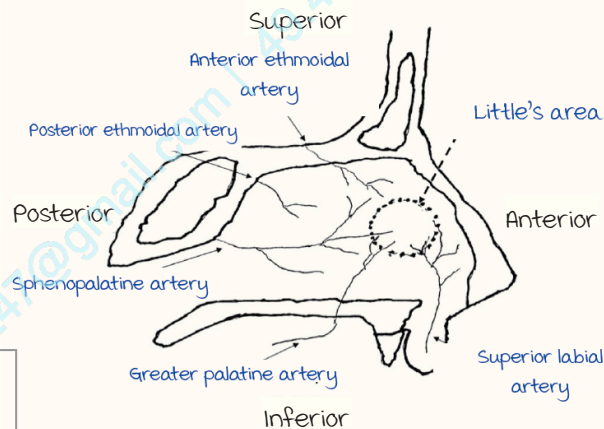
01:06:12

Anastomoses in the **Little's area** at antero inferior part of septum :

Keisselbach's plexus formative arteries :

1. Anterior ethmoidal.
2. Superior labial.
3. Sphenopalatine.
4. Greater palatine.

Posterior ethmoidal artery is not a part of Keisselbach's plexus.



One liners :

- m/c site of epistaxis in children & young : Little's area.
- m/c cause of anterior & posterior epistaxis → **Sphenopalatine artery** (main artery of epistaxis). Ligated at **sphenopalatine foramen** (1 cm behind the posterior end of middle turbinate).
- Woodruff's plexus : Present at the posterior end of inferior turbinate.
- m/c cause of epistaxis in children : Trauma.
- m/c presentation of foreign body in children : w/L foul smelling nasal discharge.
- m/c cause of epistaxis in adults /elderly : Idiopathic
- Recurrent epistaxis in young male : Rule out Angiofibroma.

## management of epistaxis :

For large volume bleeds :

- IV access, blood sample for Hct & blood grouping.
- Fluid resuscitation.
- History of drug usage & underlying conditions.

Hippocratic/Trotter's method



Control bleed.



Examine for site of bleed.



Cauterize

(Using local silver nitrate or bipolar cautery)

↓ If bleed continues

Packing (with sponge/gauge)

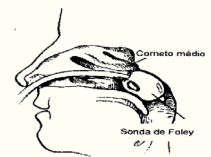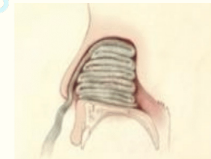Anterior nasal packing is done first.

If bleed continues → Posterior + Anterior nasal packing.

(Posterior nasal packing done f/b Anterior; Posterior done using Foley's).

↓ Still fails

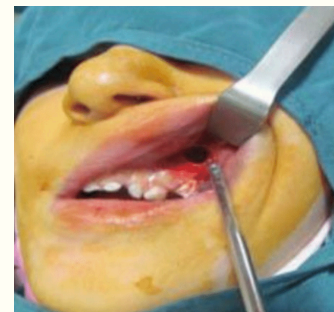
Ligate.



Note : All nasal packing done under antibiotic coverage after admission.

Order of ligation :

1. Sphenopalatine artery (TESPAL).
2. Maxillary artery.
  - Caldwell-Luc's approach (in sphenopalatine fossa).
  - Transantral endoscopically.
3. External carotid artery.
4. Anterior ethmoidal artery (in case of bleeding following Sx) or done adjuvant to others.



Caldwell-Luc's approach

## ENT REVISION 6

### Sinuses

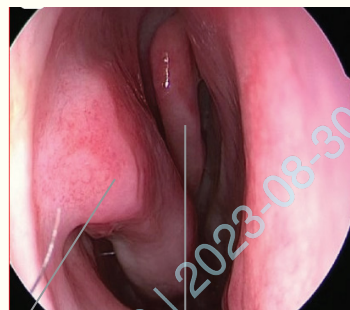00:01:37

Sinuses open into lateral wall of nose at the meatuses (Lateral to turbinates).

Inferior turbinate : Independent bone.

m/c sinusitis in children : Ethmoid sinusitis.  
m/c sinusitis in adults : maxillary sinusitis.

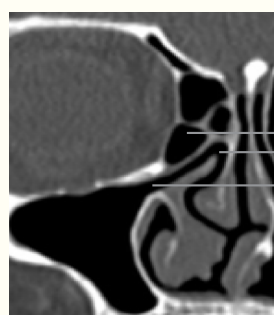All sinuses are lined by pseudostratified ciliated columnar epithelium.



Inferior turbinate      middle turbinate

Inferior meatus (Largest)	middle meatus	Superior meatus	Sphenoethmoidal recess
<ul style="list-style-type: none"> <li>Naso-lacrimal duct (Downwards, backwards &amp; laterally) opens here</li> <li>Valve of Hasner</li> </ul>	<ul style="list-style-type: none"> <li>most congested</li> <li>Osteomeatal complex (Anterior ethmoid, frontal &amp; maxillary sinuses) opens here</li> </ul>	<ul style="list-style-type: none"> <li>Smallest</li> <li>Posterior ethmoid sinus opens here</li> </ul>	<ul style="list-style-type: none"> <li>Sphenoid sinus opens here</li> </ul>

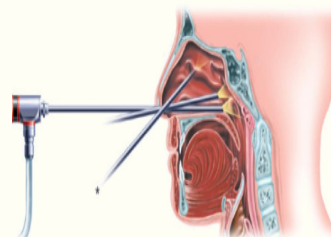
- Largest paranasal sinus : maxillary sinus/Antrum of Highmore.
- most pneumatized at birth : Ethmoid sinus > maxillary sinus.
- Least common sinusitis : Sphenoid.
- Frontal sinus :
  - Absent at birth.
  - Last to completely develop.
  - Last to be seen in X-ray.
  - Superior most.



Bulla ethmoidalis  
Hiatus semilunaris  
Infundibulum

3 pass endoscopy :

- First pass : Floor of nostrils, through inferior meatus into nasopharynx.
- Second pass : Superior turbinate + meatus & spheno-ethmoidal recess.
- Third pass : middle meatus.



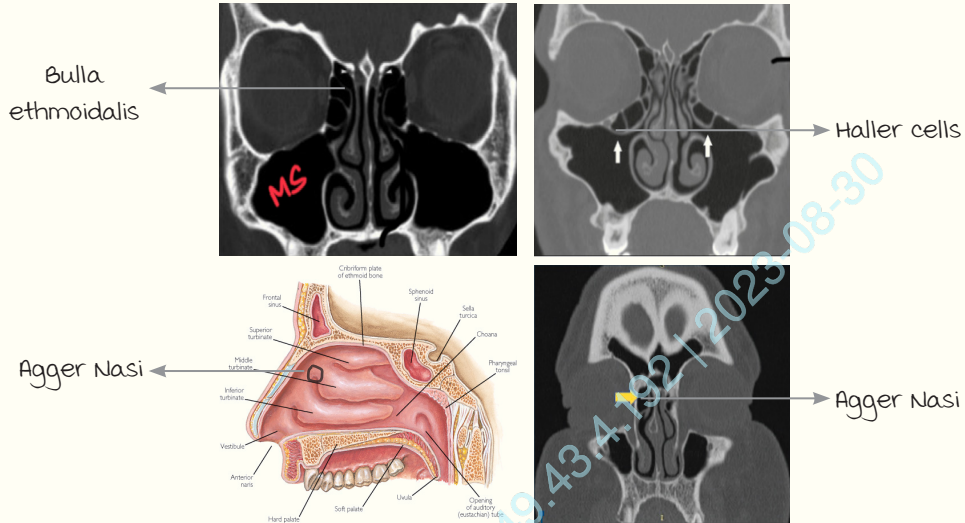
----- Active space -----

Anterior ethmoidal air cells :

**Bulla ethmoidalis** : Largest, most prominent air cell.

**Haller cells** : Present in the floor of orbit (infraorbital)/roof of maxillary sinus (On extensive pneumatization).

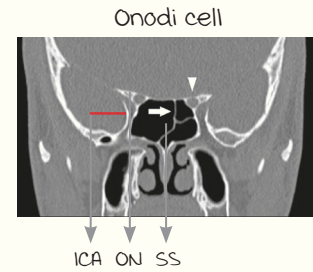
**Agger nasi** : Anterior most air cell.



Posterior ethmoidal air cells :



**Onodi cells** : Present around sphenoid sinus (SS) on extensive pneumatization.

Close associations : **Optic nerve (ON)** superiorly  
**Internal carotid artery (ICA)** laterally.



View	X-ray image
Water's view/occipitomental/ Nose-chin position (Best seen : maxillary)	
Pierr view/Waters view with open mouth (Best seen : sphenoid)	

----- Active space -----

View	X-ray image
Lateral view (All sinuses seen, highest : Frontal)	 <p>Pituitary fossa</p>
Caldwell's view/occipitofrontal/ nose forehead position (Best seen : Frontal)	 <p>Frontal sinus</p>

## Acute Rhinosinusitis

00:15:50

C/F : Nasal obstruction + nasal discharge + facial pain + hyposmia (< 12 weeks).

O/E : endoscopy → Pus/edema in middle meatus.

Facial pain characteristics	Seen in
Pain/tenderness over root of nose, medial and deep to eye	Ethmoid sinusitis
Pain increases with eye movements	
Pain/tenderness over frontal area	Frontal sinusitis
Early morning pain/periodic/office headache	
Pain/tenderness over cheek and upper jaw	Maxillary sinusitis
Occipital headache	Sphenoid sinusitis

m/c cause of acute rhinosinusitis : viral (Symptomatic Rx).

### Bacterial sinusitis :

Suspected if any 3/5 positive :

1. Discolored discharge (U/L)
2. Severe local pain (U/L)
3. Fever
4. High ESR/CRP
5. Double sickening

Etiology : *S. pneumonia*, *H. influenza*, *M. Catarrhalis*.

Rx : Antibiotics.

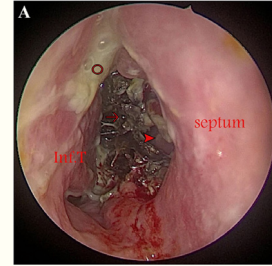
**Acute invasive fungal sinusitis :**

R/F : All immunocompromised patients (DM pts on steroids).

C/F : Nasal obstruction + nasal discharge + facial pain + hyposmia + anaesthesia for < 12 weeks.

On endoscopy : Black necrotic areas in middle meatus or turbinates.

D/x and management :



Black necrotic areas

	Mucormycosis	Aspergillosis
Biopsy + microscopy	Aseptate hyphae, right angle branching	Septate hyphae, acute angle branching
Rx	IV Liposomal amphotericin B + Local debridement + manage immunosuppression	Voriconazole + Local debridement + manage immunosuppression

m/c type of invasive fungal sinusitis : Rhino-ocular/rhino-oculo-cerebral.

Cutaneous invasive fungal sinusitis occurs in immunocompetent host, h/o injury with vegetative matter.

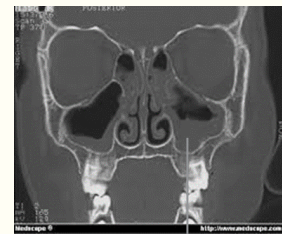
**Chronic Rhinosinusitis**

00:25:10

Symptoms extending for > 12 weeks.

**Chronic bacterial rhinosinusitis :**

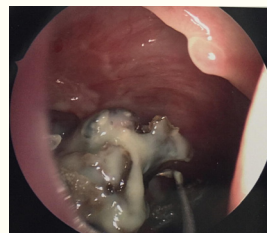
- most common.
- m/c organisms : mixed aerobic and anaerobic → most commonly *Staphylococcus*.
- Endoscopy : Pus/edema/polyp in middle meatus.
- Best investigation : NCCT.
- Rx : medical rx for one month → Surgical (FESS).



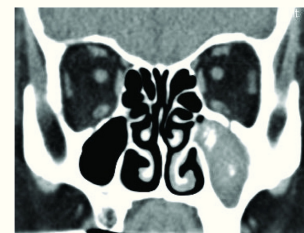
Bacterial rhinosinusitis : Pus in middle meatus

**Chronic fungal rhinosinusitis :**

- In immunocompetent people.
- Endoscopy : Cheesy/clay-like debris (Fungal ball) in middle meatus (m/c : *Aspergillus*).
- Best investigation : NCCT (Double density sign).
- Rx : FESS.



Cheesy debris



Double density sign

Functional (To restore normal function) Endoscopic Sinus Surgery (FESS) :

Do mandatory CT before FESS to visualize **CLOSE** structures :

- **C**ribiform plate (Very low lying : Keros type 3)
- **L**amina papyracea
- Rule out **O**ncodi cell (Injury to optic nerve, ICA)
- **S**phenoid sinus (Dehiscence of carotid canal)
- Ant. **E**thmoidal notch (Nipple sign on CT)

First step for FESS : **uncinectomy**.

Drug to reduce synechiae : **mitomycin C**.



most dreaded complication of FESS : Injury to **ICA**.

**Complications of sinusitis :**

m/c complication : Orbital involvement.

m/c follows : Ethmoid sinusitis.

m/c seen in children & young age.

1. Orbital cellulitis	2. Cavernous sinus thrombosis
Nasal obstruction + Nasal discharge + Hyposmia + Facial pain	
Lid edema, chemosis, proptosis, restricted ocular movements, ophthalmoplegia	
<b>Gradual onset</b>	<b>Abrupt onset</b>
Always u/L	u/L → Progress to B/L (Diplopia, other symptoms)
Concurrent involvement of 3 <sup>rd</sup> , 4 <sup>th</sup> and 6 <sup>th</sup> nerves	Sequential involvement of 6 <sup>th</sup> , 3 <sup>rd</sup> and 4 <sup>th</sup> nerves
Trigeminal parasthesia not seen	Trigeminal paresthesia can be seen
	
Orbital cellulitis	Cavernous sinus thrombosis

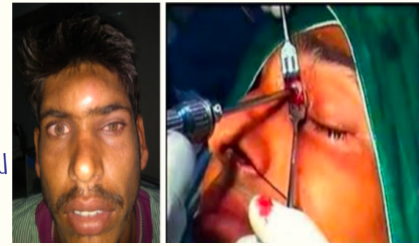Pre septal cellulitis → Orbital cellulitis → Subperiosteal abscess → Orbital abscess → Cavernous sinus thrombosis.

	3. Superior orbital fissure syndrome	4. Orbital apex syndrome
Cranial nerves involved	<ul style="list-style-type: none"> <li>• 3<sup>rd</sup>, 4<sup>th</sup>, 6<sup>th</sup></li> <li>• Ophthalmic branch of 5<sup>th</sup> nerve</li> </ul>	<ul style="list-style-type: none"> <li>• 3<sup>rd</sup>, 4<sup>th</sup>, 6<sup>th</sup></li> <li>• 2<sup>nd</sup>, 5<sup>th</sup></li> </ul>

----- Active space -----

## 5. Pott's puffy tumour :

- Young adults with sinusitis symptoms + **Soft doughy swelling on the forehead.**
- Osteomyelitis of frontal sinus → Subperiosteal abscess.
- Rx : Frontal sinus **trephination (Lynch Howarth incision).**



Pott's tumor

Lynch Howarth incision

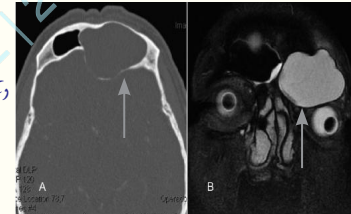
## 6. Frontal lobe abscess :

- Sinusitis symptoms + headache + fever + drowsiness + seizure + personality changes.
- **2<sup>nd</sup> m/c intracranial complication.**

7. Subdural empyema : **m/c intracranial complication.**

## 8. mucocele &amp; Pyocele (Chronic complications) :

Cystic swelling in the superomedial quadrant of orbit, pushing it down and forward (**Non-axial proptosis**).  
m/c seen with **frontal sinus > ethmoid sinus.**



mucocele

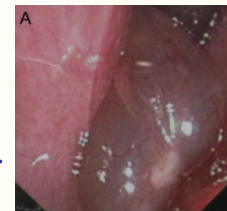
**Nasal polyps**

00:42:47

Bernoulli's principle :

Responsible for formation of polyps.

Samter's triad : Aspirin sensitivity, intrinsic asthma, nasal polyps.



Nasal polyp

B/L polyps in adults		
Similar C/F	Differentiating C/F	Disease
Nasal obstruction + Nasal discharge + Hyposmia	H/o bouts of sneezing + running nose x 10 yrs O/E : multiple polyps in both nostrils	Allergy
	H/o asthma, exacerbates on intake of painkillers (Aspirin) O/E : multiple polyps in both nostrils	Aspirin exacerbated respiratory disease (Samter's triad)
	Adult onset asthma + Eosinophilia > 10%	Eosinophilic granulomatosis with polyangiitis EGPA (Churg Strauss syndrome)
	Bronchiectasis + Infertility	Young's syndrome

## u/L polyps in adults

- Chronic bacterial sinusitis
- Allergic fungal sinusitis

## u/L polyps in children

Antrochoanal polyp

----- Active space -----

B/L polyps in children		
Similar C/F	Differentiating C/F	Disease
Nasal obstruction + Nasal discharge + Hyposmia O/E : multiple polyps in both nostrils	Recurrent pulmonary infections + bronchiectasis + intestinal obstruction + pancreatic insufficiency + malabsorption	Cystic fibrosis/ mucoviscidosis
	Chronic sinusitis + Bronchiectasis + Situs inversus	Primary ciliary dyskinesia (PCD)/ Kartagener's syndrome

**Antrochoanal polyp :**

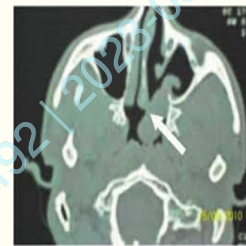
C/F : Sinusitis symptoms.

Endoscopy :

Grape like mass from the middle meatus into the choana.

Rx : FESS.

00:54:10



AC polyp

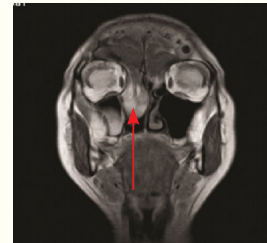
**meningoencephalocele :**

Polypoidal mass in the nose of an infant.

Size increases on crying : Fustenberg test.

Note :

Polypoid mass in the nose of an adult → Always r/o carcinoma.

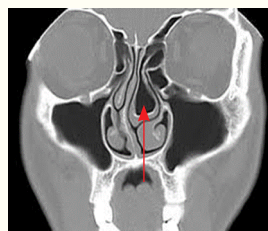


meningoencephalocele

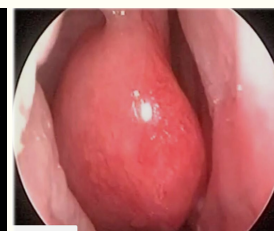**Concha bullosa :**

Differentiated from polyp by :

- Probe test
- Bleeds on probing
- Pain on probing



CT : Concha bullosa



Concha bullosa

**Allergic Fungal Sinusitis**

00:49:15

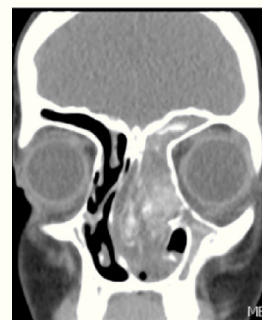
Non-invasive.

Immunocompetent, atopic patient.

m/c sinus involved : Ethmoid.

C/F : Sinusitis symptoms + H/O allergy.

Endoscopy : w/L nasal polyps & mucinous discharge.



Double density sign

Bent and Kunn diagnostic criteria of allergic fungal sinusitis :

major criteria :

- Nasal polyps
- Type I hypersensitivity (Raised IgE levels)
- Eosinophilic mucin
- CT showing hazy sinuses with heterogeneous opacities
- Positive fungal smear

Note : Positive fungal culture is a **minor criteria**.

Rx :

- 1<sup>st</sup> line : FESS, post-op steroids.

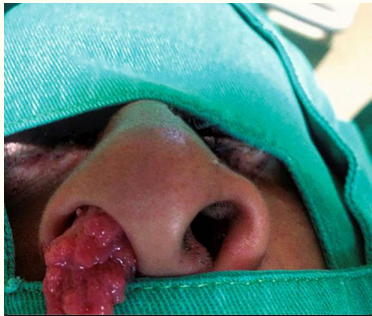## Benign and Malignant Conditions of the Nose

00:49:15

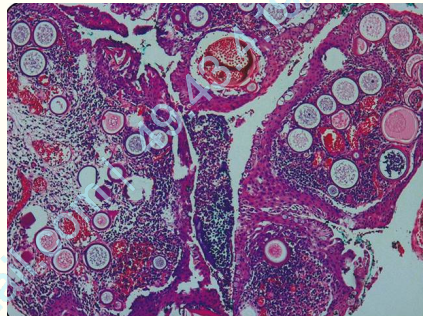
Causes of blood tinged nasal discharge		
Similar C/F	Differentiating C/F	Disease
u/L nasal obstruction with blood tinged nasal discharge ± epistaxis.  No h/o trauma	<ul style="list-style-type: none"> <li>• H/o : Bathing in ponds frequented by animals.</li> <li>• O/E : <b>mulberry</b> or <b>strawberry mass</b> with white dots, subcutaneous nodules on skin.</li> <li>• Endemic in South India (Cattle breeders, farmers).</li> <li>• Etiology : <b>R. seeberi</b> (Aquatic sporozoa)</li> <li>• Biopsy : <b>Sporangium</b> with <b>sporangiospores</b>.</li> <li>• Rx : Wide excision + cautery + post-op dapsone.</li> </ul>	Rhinosporidiosis
	<ul style="list-style-type: none"> <li>• Elderly patient (m &gt; F)</li> <li>• u/L <b>polypoidal mass</b> with <b>papillary</b> appearance in the <b>lateral wall</b> of nose.</li> <li>• Biopsy : <b>Epithelium grows into underlying stroma</b>.</li> <li>• <b>Benign, locally invasive (Highly recurrent, premalignant)</b>.</li> <li>• Rx : Lateral rhinotomy + medial maxillectomy (<b>moore's incision</b>).</li> <li>• <b>Radiotherapy</b> : Contraindicated.</li> </ul>	Inverted papilloma/ Ringertz tumor/ Schneiderian papilloma
	<ul style="list-style-type: none"> <li>• Highly vascular tumor.</li> <li>• O/E : <b>Cherry red polypoidal mass</b> in olfactory mucosa.</li> <li>• Rare lymph node metastasis.</li> </ul>	Esthesioneuroblastoma/ Olfactory neuroblastoma

----- Active space -----

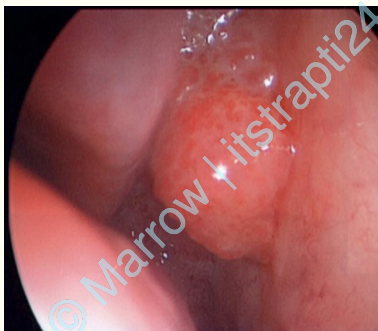Causes of blood tinged nasal discharge		
Similar C/F	Differentiating C/F	Disease
u/L nasal obstruction with blood tinged nasal discharge ± epistaxis.  No h/o trauma	<ul style="list-style-type: none"> <li>Elderly patient (m &gt; F)</li> <li>u/L ulceroproliferative mass in the nasal cavity (From middle meatus).</li> <li>Seen more in <b>carpenters</b> :                             <ul style="list-style-type: none"> <li>a. <b>Hard wood exposure</b> : Adenocarcinoma (Ethmoid).</li> <li>b. <b>Soft wood exposure</b> : SCC (maxillary).</li> </ul> </li> <li>m/c carcinoma of external nose : BCC (Rodent ulcer).</li> <li>m/c CA of PNS and nasal cavity : SCC (Nose picker's carcinoma).</li> </ul>	Carcinoma (Adenocarcinoma > SCC)



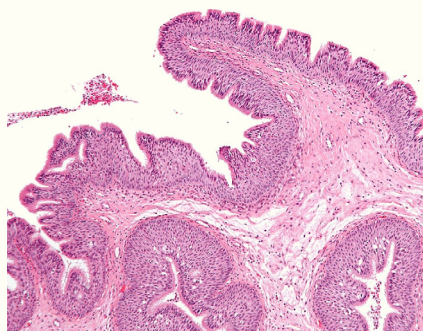
Rhinosporidiosis



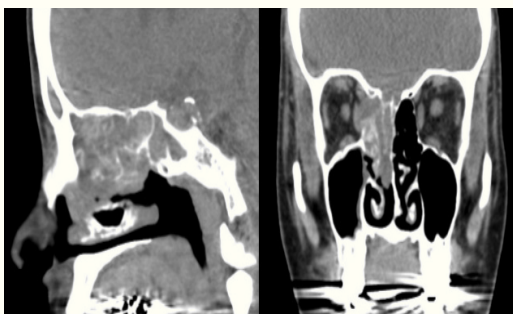
Rhinosporidiosis : HPE



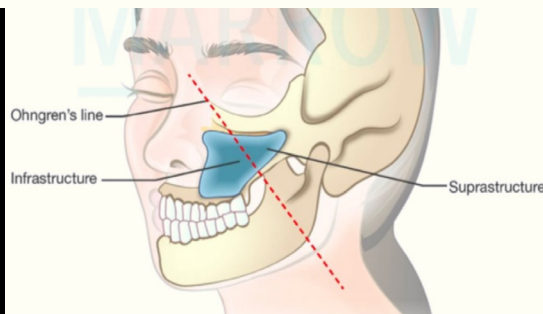
Inverted papilloma



Inverted papilloma : HPE



Esthesioneuroblastoma



Ohngren's classification

----- Active space -----

Ohngren's classification :

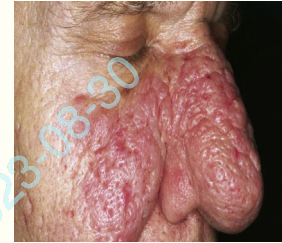used for maxillary sinus carcinoma.

- Infrastructure : **Better prognosis.**
- Suprastructure : Poor prognosis.

Stage	Rx
Stages 1, 2	Surgery
Stages 3, 4	Surgery + Radiotherapy
Incisions used : Weber Fergusson incision (or) moure's incision.	

Rhinophyma/potato nose/nasal elephantiasis :

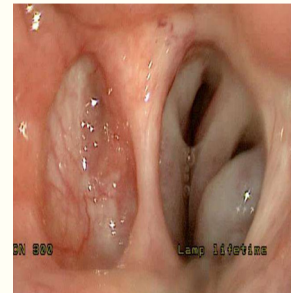
- Hypertrophy of sebaceous gland at the tip of nose.
- Long standing h/o acne rosacea.
- Seen in middle aged & older men.



Rhinophyma

Choanal atresia :

- Persistence of **bucconasal membrane** (U/L).
- C/F : **Cyclical cyanosis** (Relieves on crying) + Respiratory distress.
- unable to pass NG tube from nose to nasopharynx.
- m/c variant : mixed.
- A/w **CHARGE syndrome** (Coloboma, Heart abnormalities, Choanal atresia, Retarded growth & development, Genital &/or urological abnormalities, Ear malformations, hearing loss).
- Investigation : CT.
- Immediate mx : **mcGovern's technique.**
- Other Rx : Endoscopic excision, **mitomycin C.**



Choanal atresia

## Tests for Mucociliary Clearance

01:11:26

used for primary ciliary dyskinesia & cystic fibrosis.

1. In vivo testing (Saccharine test or nuclear testing/scintigraphy).
2. In vitro testing (Phase contrast microscopy and microscope photometry or electron microscopy).
3. Nasal nitric oxide.
4. Genetic analysis.

Note : In electron microscopy, functional abnormalities of cilia are not seen.

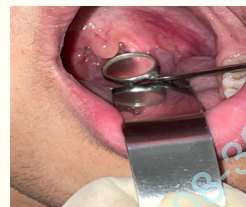# ENT REVISION 7

----- Active space -----

## Nasopharynx

00:00:37

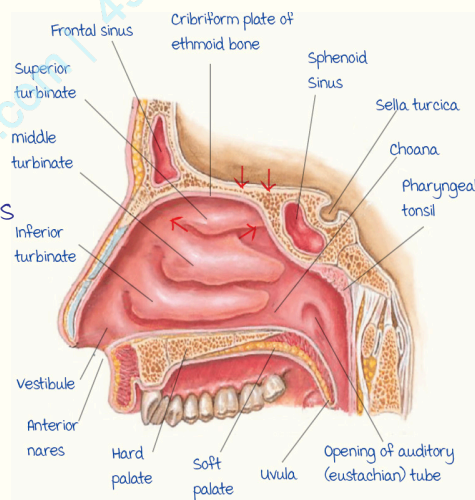
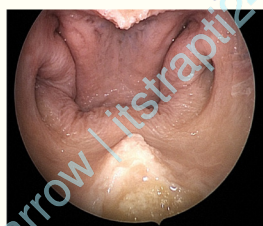
Nasopharynx obstruction → Eustachian tube obstruction +  
Nasal obstruction → Decreased hearing + Rhinolalia clausa.



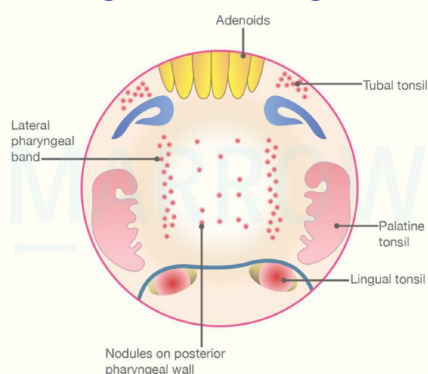
Posterior rhinoscopy  
(Nasal endoscopy preferred now)

Eustachian tube :

- Opening : **Torus tubaris** (In the lateral wall of nasopharynx).
- Length : Adults (36 mm), children (shorter & wider).
- Lateral 1/3<sup>rd</sup> (13 mm) : Bony, medial 2/3<sup>rd</sup> (24 mm) : Cartilaginous.
- Isthmus : Narrowest part.
- mass or infection in Eustachian tube → Acute or serous otitis media (SOM) (children > adults).
- main nerve supply : **maxillary nerve**.
- Epithelium : Ciliated columnar pseudo-stratified keratinized.
- Drains into retropharyngeal lymph nodes → upper deep cervical lymph nodes.




Waldeyer's ring : Collection of mucosa associated lymphoid tissue (MALT) in the oropharynx & nasopharynx .



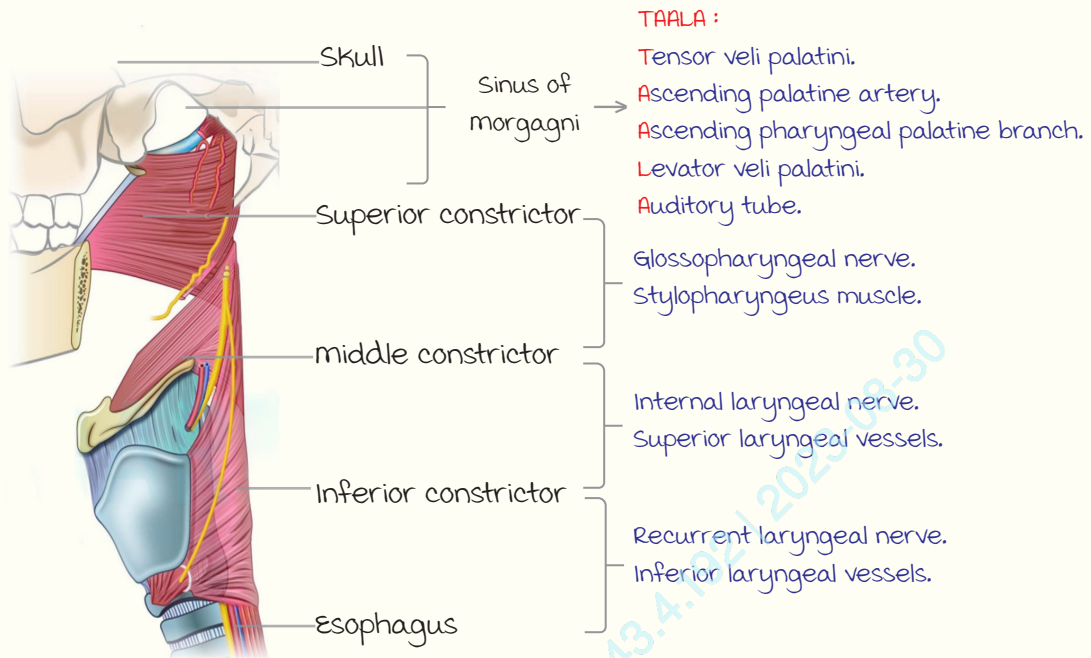
Passavant's ridge :

- Formed by superior constrictor & palatopharyngeus muscles.
- Incomplete closure : **Rhinolalia aperta** or hypernasal voice.
- Obstruction : **Rhinolalia clausa** or hyponasal voice.



----- Active space -----

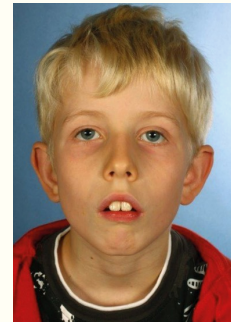
Pharyngeal tube : Superior, middle and inferior constrictors.

**Adenoid hypertrophy :**

00:17:40

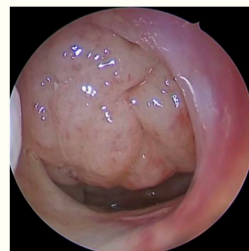Clinical features :

- a. Child with nasal obstruction.
- b. Adenoid facies :
  1. Pinched nose.
  2. Absent nasolabial crease.
  3. Open mouth.
  4. Crowding of anterior upper teeth.
  5. High arched palate.
  6. Sleep apnoea.
  7. Recurrent infections (sinusitis, acute otitis media).
  8. Bilateral decreased hearing.
  9. Rhinolalia clausa.

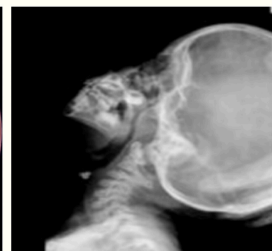


Investigations :

- Endoscopy.
- xray showing Dodd sign or crescent sign negative.
- Tympanometry : Flat curve (B-type).



Endoscopy



Dodd sign

Treatment : medical (fails) → Surgical (Adenoidectomy + myringotomy with grommet insertion).

Contraindications for surgery :

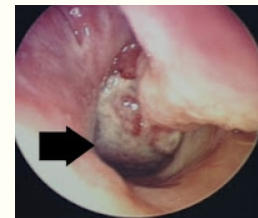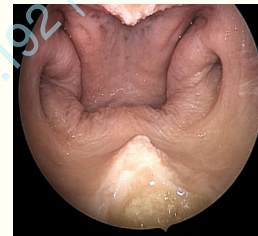
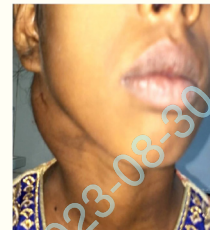- velopharyngeal insufficiency (cleft palate).
- Acute infections.
- Bleeding diathesis.

----- Active space -----

Nasopharyngeal carcinoma :

00:23:28

- m/c carcinoma of nasopharynx : **SCC**.
- Arises from fossa of Rosenmuller → Can lead to sinus of morgagni syndrome.
- C/f : Elderly patient with painless cervical lymphadenopathy (earliest symptom) + nasal obstruction + blood tinged nasal discharge + hyponasal voice + u/L CHL.
- most commonly seen in South Asians (Southern China, mongolia, Guangdong).
- Etiology : EBV.
- Risk factors : Salted fish, nitrosamines.
- Tympanometry : **B type**.
- Trotter's triad.
- Ix : Biopsy.
- Rx : Radiotherapy + chemotherapy (in late stages).



Trotter's triad :

- mandibular neuralgia.
- Palatal palsy.
- Conductive hearing loss.

Angiofibroma :

00:30:20

Originates from **sphenopalatine foramen**.

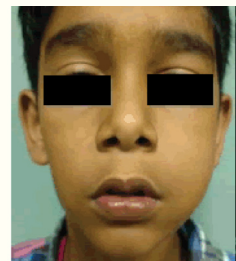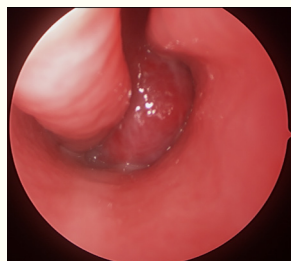
m/c benign, but locally invasive tumor of nasopharynx.

m/c presentation : Young pubertal male with recurrent epistaxis ± frog facies.

**Biopsy contraindicated.**

Endoscopy : Red, flesh mass.

Ix : CECT (Best) → **Hollmann miller sign**  
or Antral sign.



Staging : Radkowski staging.

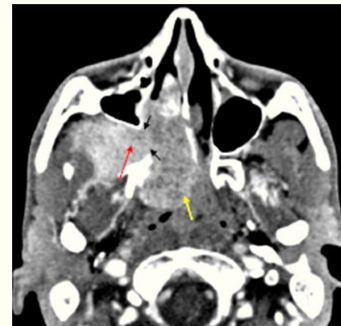
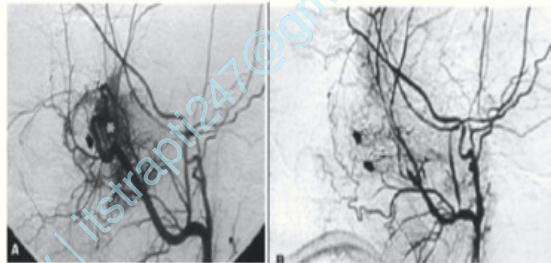----- Active space -----

Stage	Spread
1 : medial spread	
1a	Nose/ nasopharynx
1b	Sinuses
2 : Lateral spread	
2a	minimal spread in sphenopalatine fossa
2b	Completely filling and orbit
2c	Infratemporal fossa
3 : Intracranial extension	
3a	minimal intracranial extension
3b	Extensive, unresectable

Rx :

- Primary Rx : Surgical excision + pre-op embolisation of maxillary artery.
- Unresectable : Radiotherapy.

Recurrence : High rates.

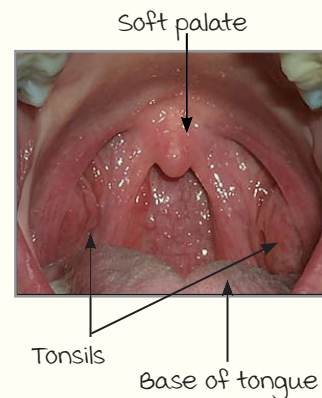


## Oropharynx

00:35:55

Anatomy of oropharynx :

- Hard palate to hyoid
- Stratified squamous non-keratinised epithelium.
- Structures : Tonsils, soft palate, base of tongue, vallecula
- main nerve supply : Glossopharyngeal nerve (pain referred to ear).
- Drainage : 2 (tonsillar nodes/ upper deep cervical nodes), 3 and 4.

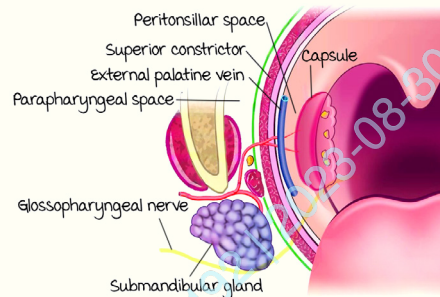


### Anatomy of tonsils :

- Component of Waldeyer's ring.
- Develops from 2<sup>nd</sup> pharyngeal pouch (remnant : Crypta magna - largest crypt of tonsil).
- Stratified squamous non-keratinised epithelium.
- Capsule of tonsils formed by pharyngobasilar fascia.

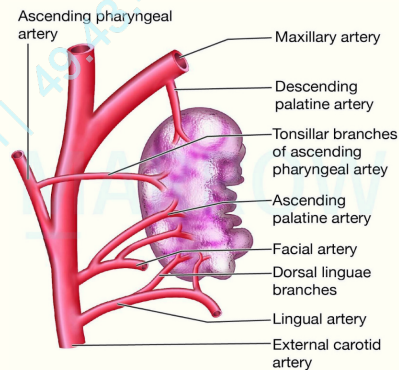
#### • Bed of tonsil :

1. Peritonsillar space (external palatine or paratonsillar vein).
2. Superior constrictor muscle.
3. Parapharyngeal space (styloid process and muscles attached to it).
4. Submandibular gland.
5. Glossopharyngeal nerve.



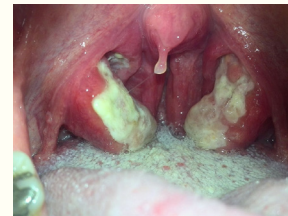#### • Arterial supply :

- Tonsillar artery (facial artery).
- Ascending palatine artery (facial artery).
- Lingual artery.
- Descending palatine branch of maxillary



### Acute tonsillitis :

- m/c cause of acute tonsillitis : Group A Streptococcus (Rx : amoxi-clav).
- c/f : Child with severe sore throat + fever + odynophagia + otalgia.
- o/e : Enlarged tonsils, congested, purulent exudates, pseudomembrane over tonsils, tender lymph nodes.

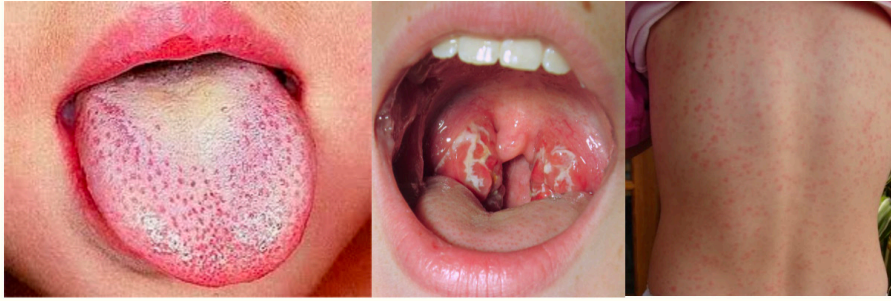


### Other causes of membrane (pseudomembrane) over tonsils :

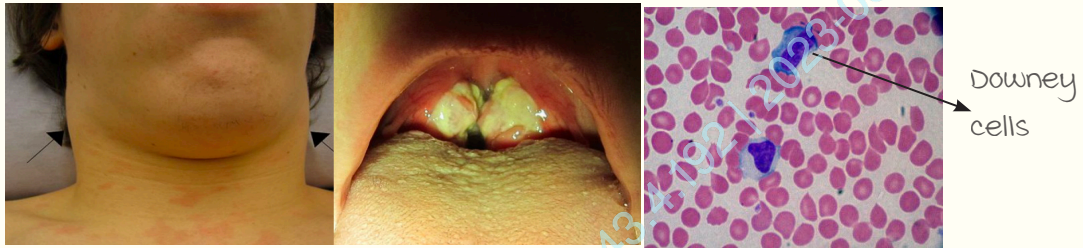
- Vincent's angina
- Infectious mononucleosis.
- Candidiasis (moniliasis).
- Infections of throat (GAS : Group A hemolytic Streptococcus).
- Diphtheria.

----- Active space -----

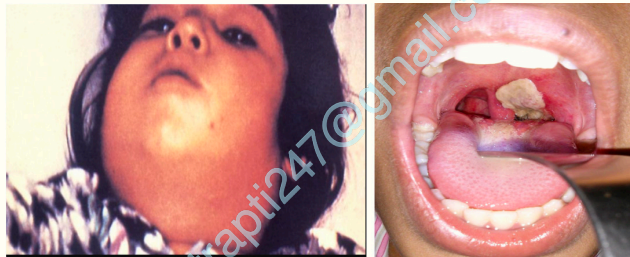Causes of enlarged tonsils :



Scarlet fever (erythrogenic toxin) :  
 Strawberry tongue + Sandpaper rash + tonsils enlarged + pastia lines.

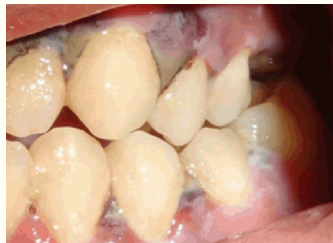

Infectious mononucleosis : Adolescent + petechia on soft palate + Hoagland sign +  
 hepatosplenomegaly + enlarged tonsils.  
 Ix : Atypical lymphocytosis, Paul Bunnell/monospot test. Ampicillin to be avoided.

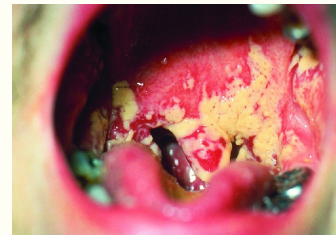


Diphtheria :  
 Dirty grey membrane  
 extending beyond the tonsils,  
 no h/o immunization, bleeding  
 on removal.  
 Rx : Diphtheria antitoxin  
 (exotoxin), antibiotics.

myocarditis and palatal palsy are complications.



Vincent's angina/ acute necrotising ulcerative  
 gingivitis/ Trench mouth :  
 Gingivitis (poor oral hygiene).  
 Caused by *Borrelia vincetti*, *F.fusiformis*



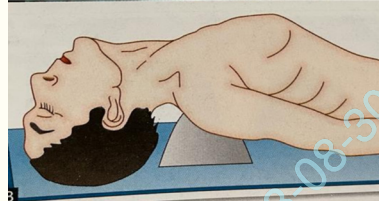
Oral thrush/ muniliasis /  
 Oral candidiasis :  
 Immunocompromised/  
 patient on steroid inhaler

### Tonsillectomy :

Indications for tonsillectomy :

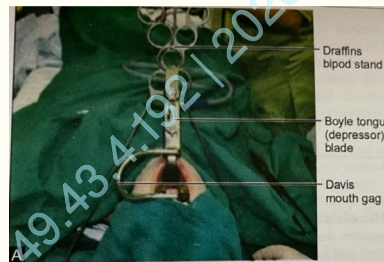
- Recurrent tonsillitis (3 per year for 3 years or 5 per year for 2 years or 7 per year in 1 year).
- Peritonsillar abscess (1 in a child or 2 in adults).
- Chronic tonsillitis/ Diphtherial or Streptococcal carriers.
- Obstructive sleep apnea.

Position : Rose position.



Instruments :

- Cold : Dissection and snare, microdebrider harmonic scalpel.
- Hot : Cautery, coblation.



Procedure :

- Extracapsular (infective indications).
- Intracapsular (sleep apnea).

m/c complication : Hemorrhage (Rx : Remove clot (Clip) → Pressure with vasoconstrictor (with gauze piece) → Cautery → Ligate).

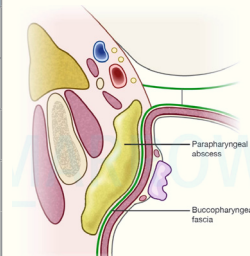
- Primary : During surgery.
- Reactionary : Post-op - 24 hours.
- Secondary : 24 hours - 10 days (m/c : 5-6 days)

Rare complication : Grisel syndrome.




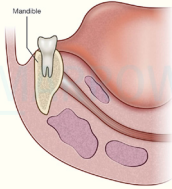

Compartments :

Styloid divides the lateral space (parapharyngeal space) into anterior and posterior compartments.

Symptom	Location of abscess
Trismus	Only anterior compartment
Parotid bulge	Anterior or posterior
Tonsil moved medially	Anterior
Neurogenic tumors	Posterior
Horner's syndrome (ICA, IJV, 9, 10, 11, 12 cranial nerves).	

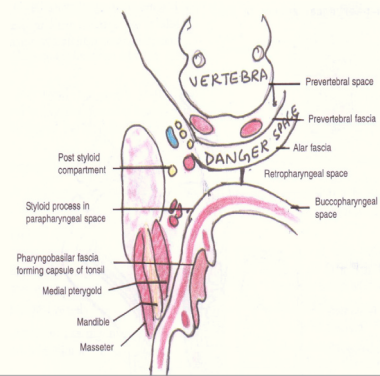


## Differential diagnosis of acute tonsillitis :

Peritonsillar abscess/ quinsy	Parapharyngeal abscess	Ludwig's angina (cellulitis of submandibular space)	Retropharyngeal abscess
c/f : Fever + sore throat + odynophagia + pain in ear			
<ul style="list-style-type: none"> <li>Tonsil pushed medially, drooling, muffled (hot potato) voice, trismus.</li> <li>Rx : IV antibiotics, aspiration → I + D. Interval tonsillectomy.</li> </ul> 	<ul style="list-style-type: none"> <li>Bulge in angle of jaw, tonsil pushed medially, trismus.</li> <li>Rx : IV antibiotics, I + D by horizontal incision 2-3 cm below mandible (to prevent marginal mandibular nerve injury).</li> </ul> 	<ul style="list-style-type: none"> <li>H/o dental caries, B/I swelling, brawny edema with woody feel below mandible, floor of mouth raised, trismus.</li> <li>Rx : IV antibiotics, I + D.</li> </ul>  	<ul style="list-style-type: none"> <li>Torticollis, stridor, u/L paramedian bulge of posterior pharyngeal wall, bulge of prevertebral space.</li> <li>Rx : Airway management, IV antibiotics, I + D.</li> </ul> 

## Fascia behind posterior pharyngeal wall :

- Buccopharyngeal fascia.
    - Retropharyngeal space
  - Alar fascia.
    - Danger space
  - Pre-vertebral fascia.
    - Pre-vertebral space
- vertebra



## Abscess in retropharyngeal space :

- Divided into two parts called space of Gillette.
- Inflammation of nodes of Rouvier → O/E : u/l bulge of posterior pharyngeal wall.

## Abscess in prevertebral space :

- midline diffuse bulge of posterior pharyngeal wall.

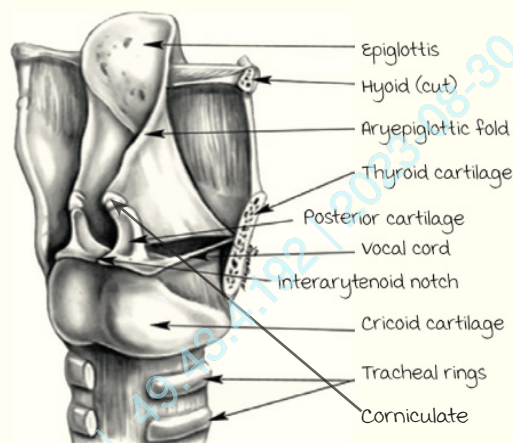
# ENT REVISION 8

----- Active space -----

## Anatomy of Larynx

00:00:54

- Function : mainly Protection of lower airway
- Development :
  - Thyroid : 4th arch
  - Cricoid : 6th arch
  - Epiglottis : 4th arch (Hypobranchial eminence)
- Nerve supply :
  - upper half → SLN.
  - Lower half → RLN.



### Cartilages of Larynx :

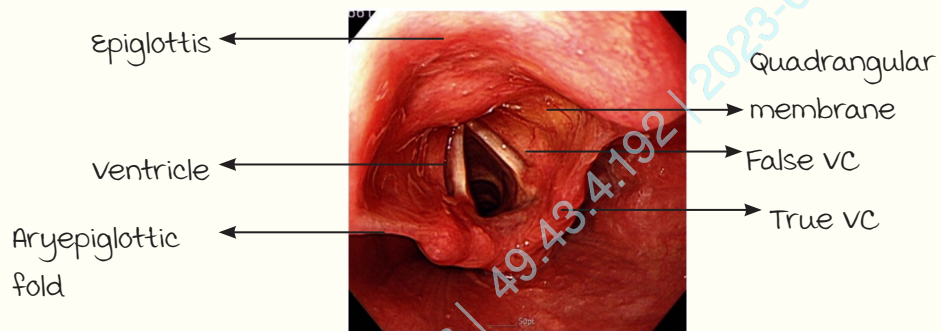
Unpaired	Paired
<ul style="list-style-type: none"> <li>• Epiglottis- Elastic cartilage, leaf shaped (Doesn't calcify).</li> <li>• Cricoid- Signet ring, m/c site for laryngeal stenosis, hyaline (Calcifies).</li> <li>• Thyroid - Hyaline (Largest, Calcifies).</li> </ul>	<ul style="list-style-type: none"> <li>• Arytenoid</li> <li>• Corniculate (Santorini)</li> <li>• Cuneiform (Wrisberg)</li> </ul>

Extrinsic membranes (B/w laryngeal cartilage & hyoid & trachea)	Intrinsic membranes (In B/w Laryngeal cartilages)
<ol style="list-style-type: none"> <li>1. Thyrohyoid membrane - pierced by ILN, (site for anesthesia of ILN - below hyoid greater cornu)</li> <li>2. Hyoepiglottic</li> <li>3. Cricotracheal</li> </ol>	<ol style="list-style-type: none"> <li>1. Quadrangular           <ul style="list-style-type: none"> <li>Upper part : Aryepiglottic fold,</li> <li>Lower part : False vocal cord.</li> </ul> </li> <li>2. Conus elasticus / cricovocal (site of coniotomy/cricothyrotomy)</li> </ol>

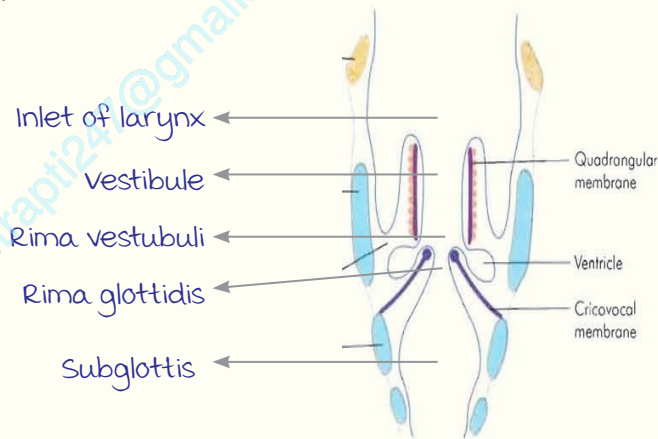
----- Active space -----

## Sites of Larynx :

	Supraglottis	Glottis	Subglottis
Contents	Epiglottis, Arytenoids, Aryepiglottic folds, False vocal cords, Ventricle	True Vocal cords (TVC), Anterior and Posterior Commissure	Below TVC
Lymphatics	Upper and middle deep cervical	No lymphatics (watershed area)	Lower deep cervical
Lining Epithelium	Ciliated columnar pseudo stratified	TVC - Stratified squamous non keratinised Rest - Ciliated columnar pseudo stratified	Ciliated columnar pseudo stratified



## Cavity of larynx :





## Spaces of Larynx :

Pre-epiglottic space/ Space of Boyer	Para-epiglottic space/ Space of Tucker	Reinke's space
In front of epiglottis	Lateral to larynx	In b/w vocal cord epithelium & vocal ligament.
Boundaries : Superiorly : Hyoepiglottic lig. Anteriorly : Thyroid & thyrohyoid m. Posteriorly : Epiglottis	Boundaries : Laterally : Thyroid ala medially : Ventricle & quadrangular m., Conus elasticus. Posteriorly : Pyramiform fossa.	Applied aspect : Edema of the space → Vocal cord edema → Rinke's edema.

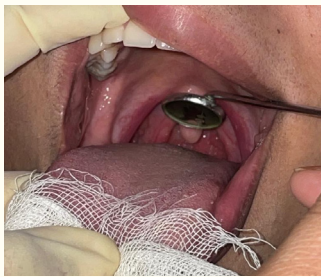Differences in larynx with age :

----- Active space -----

	Infant	Adult
Epiglottis shape	omega	leaf
Shape of larynx	funnel	cylindrical
Narrowest part	subglottis	glottis
Location	C2-C3(allows to breathe & suckle at the same time)	C3,C4,C5,C6
		

Instruments used in the examination of larynx

00:00:54



Indirect laryngoscopy



Flexible endoscopy



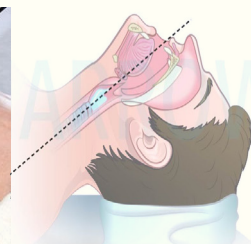
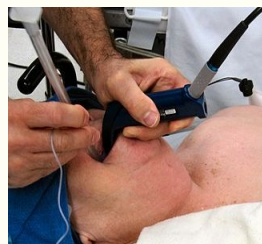Rigid endoscopy

Stroboscopy :

- Visualizing the mucosal waves during speech.
- Detect small lesions of the vocal cords.



Direct laryngoscopy :

- Patient is kept in Boyce /Chevalier Jackson/Barking dog/sniffing morning air position. (Flexion at cervical spine and extension at atlanto-occipital joint).
- This position brings the larynx in line with the oral cavity.



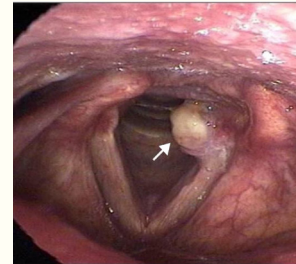
## Structural and functional disorder of Larynx

00:13:00

	vocal nodule	vocal polyp
c/o	Hoarseness, h/o repeated voice abuse.	Hoarseness, h/o voice abuse
o/e	Feature : Bilaterally symmetrical, <3mm $\xi$ sessile. Site : At the junction of anterior 1/3rd $\xi$ posterior 2/3rd.	Feature : Solitary pedunculated swelling Site : At the junction of anterior 1/3rd $\xi$ posterior 2/3rd.
mx	voice rest $\xi$ Speech therapy.	Excision by microlaryngeal surgery (MLS).
		

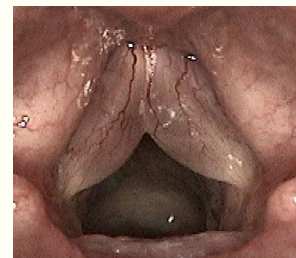
### Arytenoid granuloma :

- c/o :  
voice abuse : Contact ulcer /contact pachydermia.  
Laryngopharyngeal reflux - Peptic granuloma.  
Trauma by Intubation - Intubation granuloma.
- o/e : u/L or B/L nodular masses, at vocal process of arytenoids.
- mx : Speech therapy, Reflux management, excision  $\xi$  Botulinum toxin injection in the thyroarytenoid muscle



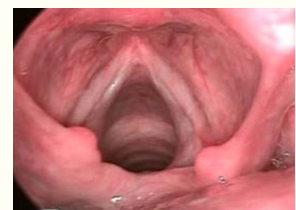### Rienke's Oedema (Smoker's larynx) :

- c/o : Hoarseness, voice abuse.
- o/e : B/L symmetrical oedema involving the entire length of vocal cord.
- mx : Cessation of smoking, voice therapy, Reduction glottoplasty.



### Pseudo Sulcus :

- c/o : Hoarseness  $\xi$  H/o laryngopharyngeal reflux.
- o/e : Infraglottic edema .
- mx : Reflux treatment.

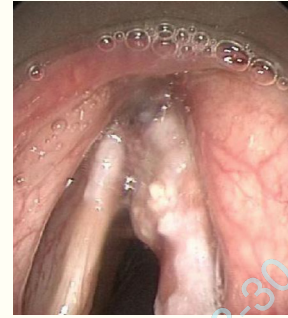


**Carcinoma of Larynx :**

00:19:50

----- Active space -----

- m/c in males & smokers.
- m/c Squamous cell carcinoma.
- Glottis
  - a. m/c site.
  - b. Least lymphatic metastasis.
  - c. Best prognosis.
  - d. Earliest presentation.
- Supraglottis.
  - a. Max. LN metastasis.
  - b. B/L LN metastasis (Epiglottis also).
  - c. Presents with dysphagia.
- Pain in ear is d/t vagus nerve involvement.



**Tumor Staging :**

	Extent	management
T1	Limited to 1 site of Glottis/subglottis or 1 subsite of supraglottis with normal VC mobility	T1a glottis : TLM ( midcord lesions) T1b glottis/ T1 supraglottis : TLM/RT
	T1a : limited to one VC	
	T1b : involving both VC	
T2	Extension to adjacent sites/subsites ± Impaired VC mobility	TLM/ RT
T3	Spread to preepiglottic/paraglottic space or postericoid area with thyroid cartilage erosion, OR VC Fixation.	Concurrent chemo RT
T4a	Invades through Thyroid cartilage or Trachea, Strap muscles, Tongue muscles, Thyroid & oesophagus.	TL+ Adjuvant RT
T4b	Invades to distant places like prevertebral space, mediastinum, carotid.	Palliative

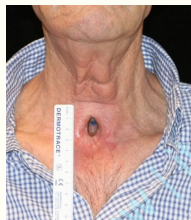- IOC for cartilage involvement : MRI.
- management of Recurrence following RT :
  - a. T1, T2 : Conservative surgery/ Open partial laryngectomy.
  - b. T3, T4 : Total Laryngectomy (TL)

## management of LN : Neck Dissection (ND)

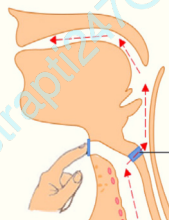
Radical ND	modified RND	Selective ND
Structures removed : <ul style="list-style-type: none"> <li>• Level I to V LN.</li> <li>• Non Lymphatic structures               <ol style="list-style-type: none"> <li>1. Nerve : Spinal accessory</li> <li>2. vein : IJV</li> <li>3. muscle : SCM</li> <li>4. Parotid, submandibular gland, omohyoid.</li> </ol> </li> </ul>	Structures removed : <ul style="list-style-type: none"> <li>• Level I to V LN.</li> </ul> Structures preserved : <ol style="list-style-type: none"> <li>1. MRND I : Spinal acc N.</li> <li>2. MRND II : Spinal acc N. + IJV.</li> <li>3. MRND III : Spinal acc N. + IJV + SCM.</li> </ol> MRND III aka functional/comprehensive ND.	Done only for N <sub>0</sub> Supraglottic tumor with high risk of LN mets. Involves <ul style="list-style-type: none"> <li>• Lateral ND : II, III, IV removed</li> <li>• Anterior ND : VI (Delphian LN removed).</li> </ul>

## Rehabilitation following laryngectomy :

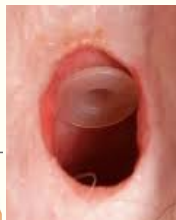1. Permanent tracheostome.
2. Speech.
  - a. Esophageal speech
  - b. Tracheo-oesophageal speech (Blom Singer & Panje valve) : Best.
  - c. Electrolarynx : monotonous robotic voice
3. Heat and moisture exchanger (HME) : Humidification & filtering air with hands free speaking valve.
4. Olfactory rehabilitation : Polite yawning causes nasal airflow.



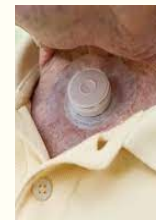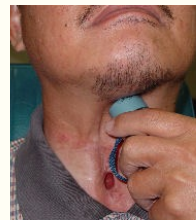1.



a.b



a.c

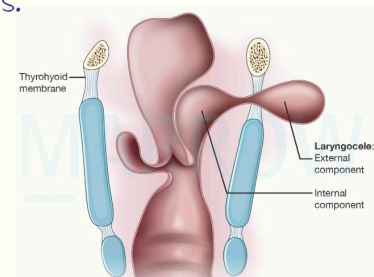


3.



## Laryngocoele : (Enlargement of sacule)

- c/o : Hoarseness, usually seen in trumpet blower.
- o/e : Bulge in supraglottis obscuring TVC.
  - external neck swelling ↑ in size on valsalva.
  - Pierces thyrohyoid membrane → Extrinsic.
  - Bryce sign : Hissing sound on compression
- mx : excision (open/endoscopic method).



00:43:23

----- Active space -----

**Functional Aphonia/Hysterical Aphonia:**

- C/o : Female pt. talking only by whisper.
- O/E : No VC adduction on speech & VC movement on cough.
- mx : Psychotherapy and reassurance.

**Puberphonia or mutational Falsetto :**


- C/o : Adult male patient having high pitched voice.
- O/E : Gutzmann's pressure's test → Larynx pushed posteriorly & downwards → Low pitched voice.
- mx : Type III thyroplasty

**Dysphonia plica ventricularis :**

- Etiology : voice produced by ventricular folds (FVC).
- C/o : Low pitch, rough voice.

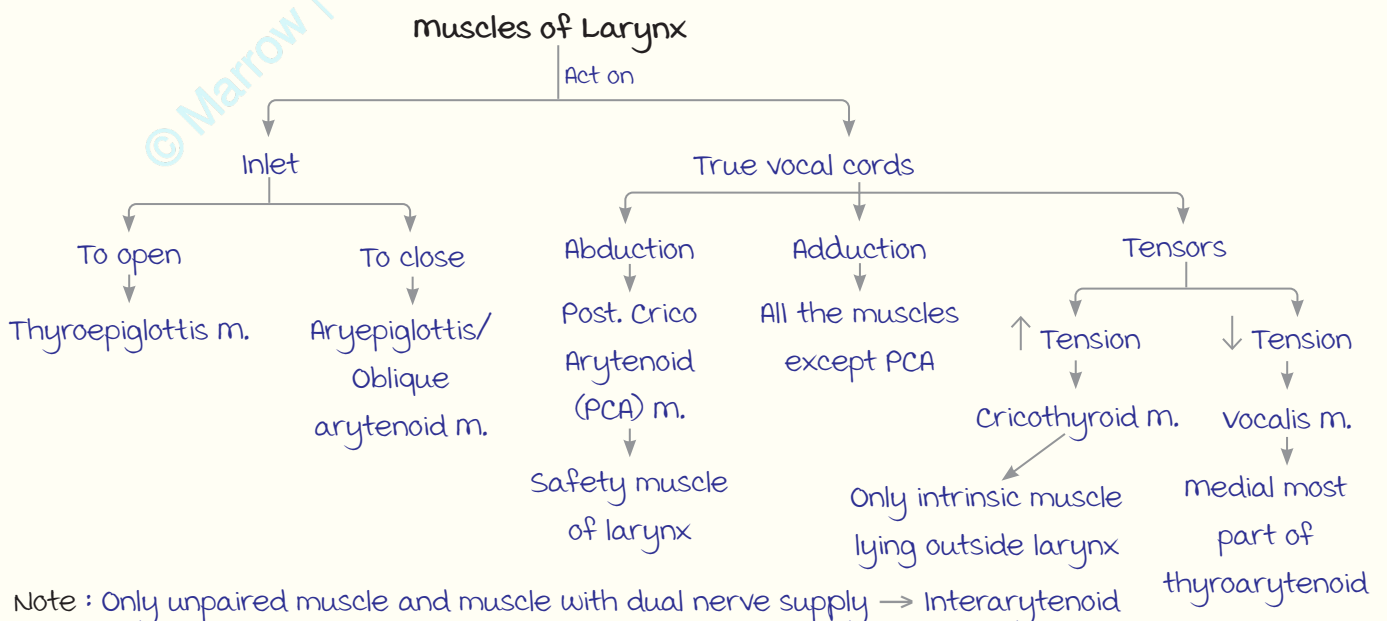
**Neuromuscular disorder(NMD) :**

Spasmodic dysphonia : Spasms of vocal muscles only during speech (phonation) with focal dystonia.

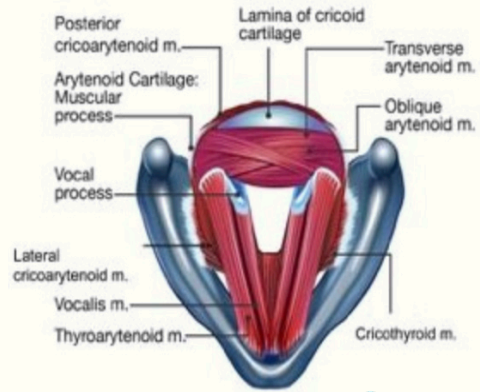
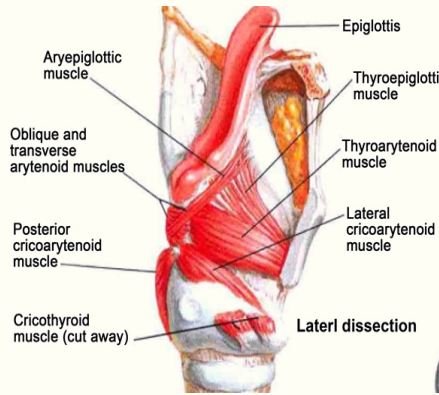


**Muscles and Nerve supply of Larynx**

00:00:54

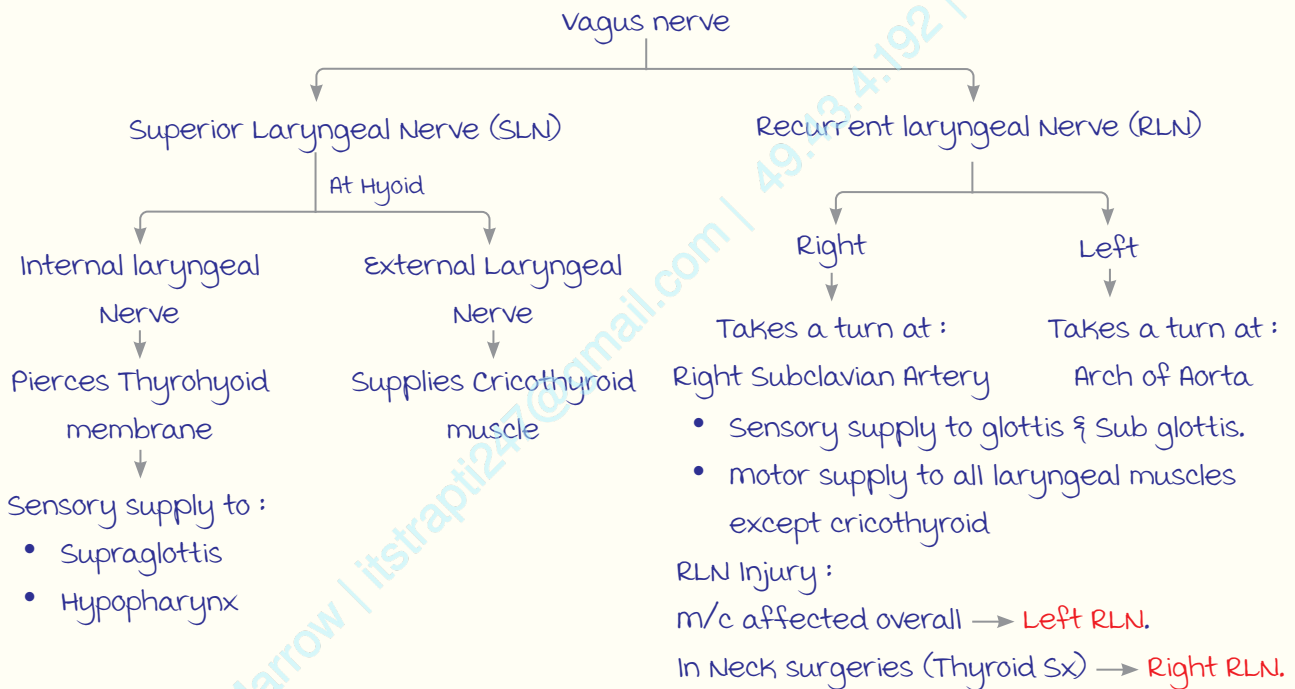


----- Active space -----



Intrinsic muscles of larynx

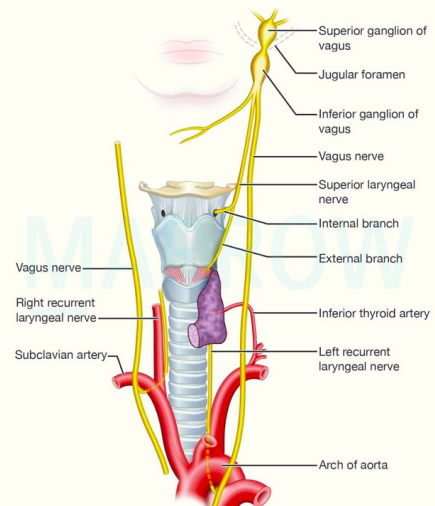
Nerve supply of vagus :



Applied aspect :

- ILN injury → Aspiration.
- ELN injury → Inability to raise pitch
- SLN → Aspiration + inability to raise pitch.

Site of lesion	Nerve injured
Base of skull	Complete palsy, SLN
Neck (Carotid triangle)	SLN/ILN/ELN
Thyroid surgery	ELN > RLN
mediastinal surgery	Left RLN



----- Active space -----

Function of Larynx	unilateral RLN palsy	Bilateral RLN Palsy	u/L complete palsy	B/L complete palsy
1. speech	Normal/ mild Hoarseness	Normal	Aphonia Dysphonia	Aphonia
2. Respiration	Normal	Stridor	Normal	Normal
3. Aspiration	-	-	+(occasional)	Chronic
4. mx.	Conservative	Tracheostomy f/b vocal cord lateralisation	medialisation of vocal cord	Tracheostomy + Epiglottoplexy/ vocal cord plication

Thyroplasty (medialisation/Lateralisation Sx) : mnemonic → **PLaSTy**

- I → **P**roximalisation/medialisation.
- II → **L**ateralisation.
- III → **S**hortening (relaxing) → Puberphonia.
- IV → **T**ightening (tensing) → Androphonia.

## Other disorders of Larynx

00:00:54

Disorders causing stridor :

- Infective → Epiglottitis, Croup.
- Non Infective →
  - Congenital conditions : Laryngomalacia, Subglottic stenosis.
  - vocal cord palsy.
  - Tumors : Juvenile laryngeal papilloma, Carcinoma larynx.
  - Foreign body in air passages.

Disorder's that don't cause stridor : TB larynx.

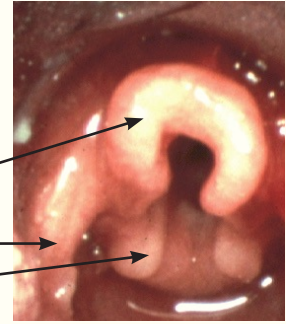
Stridor type according to site involved :

1. Supraglottis : Inspiratory
2. Glottis : Inspiratory/biphasic
3. Subglottis to cervical trachea : Biphasic
4. Intrathoracic trachea to secondary bronchi : Expiratory  
Beyond secondary bronchi, it is called as Stertor.

### Congenital conditions of Larynx :

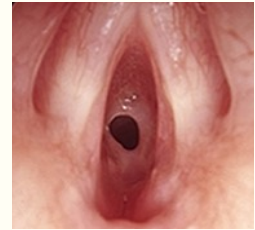Laryngomalacia : (m/c congenital anomaly of larynx)

- C/o Inspiratory stridor at or shortly after birth, No signs of distress or cyanosis.  
Stridor disappears in prone position, cry is normal.
- O/E : Elongated & large omega shaped epiglottis.  
Short and floppy aryepiglottic folds.  
Excessive redundant tissue in supra glottis
- management :
  - a. Reassurance (disappears by 2 years).
  - b. If feeding difficulty/ failure to thrive : Supraglottoplasty.



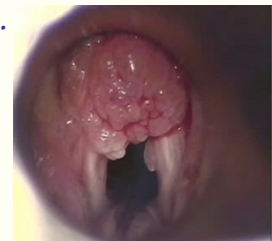Sub Glottic Stenosis :

- < 4 mm in full term, < 3 mm in preterm.
- m/c cause of acquired Subglottic stenosis → Prolonged intubation.  
To prevent it → Tracheostomy after 2-3 weeks of intubation.
- C/o biphasic stridor.
- Examination : meyer-cotton grading system .
- mx : Balloon dilation, Costal cartilage graft, Cricotracheal resection (type 4) with montgomery T tube.  
Drug used to prevent Re-stenosis : mitomycin C.



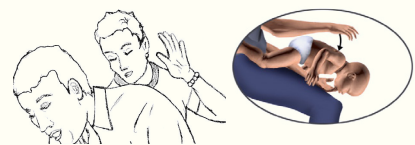Juvenile Laryngeal Papillomatosis/ Recurrent Respiratory Papillomatosis :

- Etiology : HPV subtypes 6 and 11 (Low malignant potential).  
(HPV 11 : more virulent).
- C/o : Hoarseness followed by stridor after few days,  
H/O vaginal delivery.
- O/E : multiple Papillomas at TVC & Supraglottis.
- mx : microlaryngoscopic excision microdebrider > Co<sub>2</sub> laser.  
Tracheostomy and Irradiation (↑ malignant transformation) avoided.  
To decrease recurrence in postop : A : α- interferon, B : Bevacizumab,  
C : Cedofovir (Intralesional).



Foreign body (FB) :

- m/c age : 1-4 yrs
- m/c FB : Nuts & peanuts.
- Symptoms :  
Early : Sudden onset paroxysmal coughing, Hoarseness, Choking & gagging.  
Late : Hemoptysis, Stridor.



Back blows

----- Active space -----

• management :

First aid → Back blows & encourage coughing.

If FB visible : finger sweep maneuver (In children).

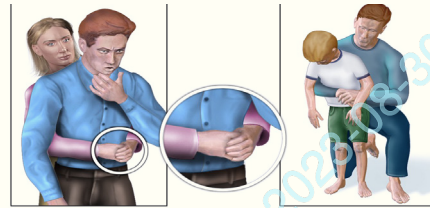Conscious with universal choking sign → Heimlich manoeuvre.

If first aid fails → Cricothyrotomy/minitracheostomy/Coniotomy/Inferior laryngotomy.

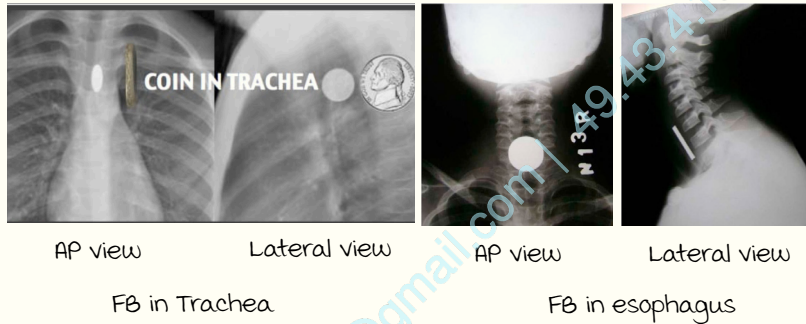
Removal by rigid Laryngotracheo- bronchoscopy.

Heimlich manoeuvre contraindications :

- Age <1yr.
- Unconscious.
- Pregnancy and obese.



Heimlich Manoeuvre



AP view

Lateral view

FB in Trachea

AP view

Lateral view

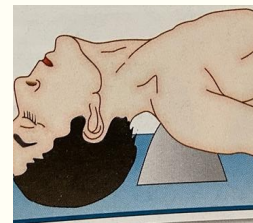
FB in esophagus

Tracheostomy :

Position : Rose's position (Extension at cervical & atlanto occipital joint).

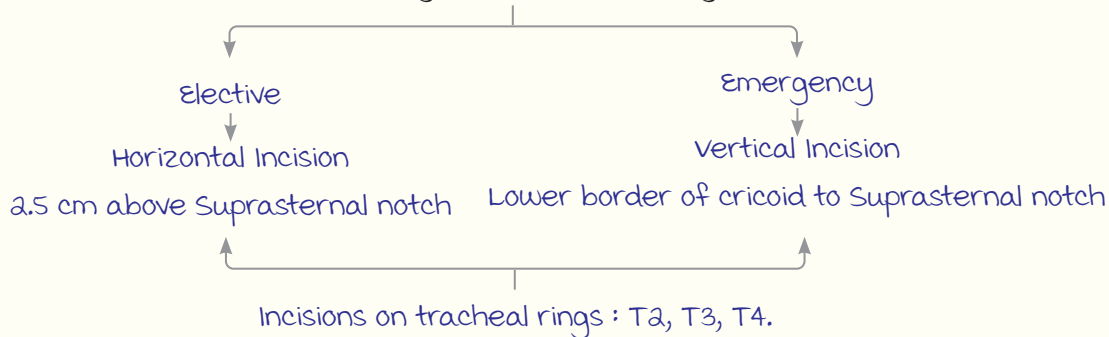
Indications :

- **Occupy** : Obstruction above tracheal rings 2, 3, 4.
- **most** : mechanical ventilation (m/c indication).
- **Seats** : Secretion removal/pulmonary toilet.
- **medical** : maxillofacial and head and neck Sx.
- **Association** : Prevent Aspiration in B/L complete VC palsy.



Rose's position

Types of Tracheostomy



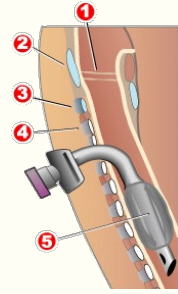
----- Active space -----

High tracheostomy : (Incision at TI ring)

- Indication : Only for Carcinoma Larynx.
- Complication : Laryngeal stenosis.

Change of ET tube :

- First change : Children-7th day, Adults-3rd day.
- Prevention of obstruction : Saline/ $\text{NaHCO}_3^-$  suction irrigation.
- mx of Completely blocked tube : Remove the tube.

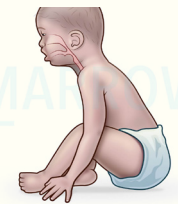

- 1 : vocal folds.  
2 : Thyroid cartilage.  
3 : Cricoid cartilage.  
4 : Tracheal rings.  
5 : Balloon cuff.

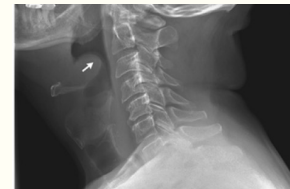Infections of Larynx :

Epiglottitis :

- Etiology : Streptococcus (m/c).
- C/f : Acute onset fever, Inspiratory stridor, Odynophagia  
Drooling of saliva, Normal cry, Prefers leaning forwards/ **tripod position**.
- O/E : X-ray Neck lateral view → **Thumb sign**.  
Pharyngeal examination, C/I in children (d/t laryngospasm).
- management :
  - a. Secure airway by Intubation.
  - b. IV antibiotics.
  - c. IV fluids.
  - d. Steroids
  - e. Adrenaline Nebulisation.



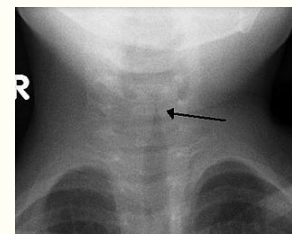
Tripod position



Thumb sign

Croup/ Laryngo-Tracheo-bronchitis :

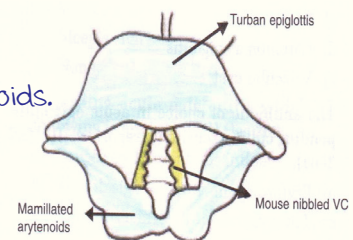
- Etiology : Parainfluenza virus.
- C/F : Gradual onset, Prodromal symptoms, Hoarseness,  
Barking cough, Inspiratory/Biphasic stridor.
- X-ray AP view : **steeple sign**.
- management : Fluids, Steroids, Adrenaline nebulisation.



Steeple sign

TB Larynx :

- C/o Low grade fever, Cough, weight loss, Extremely painful swallowing (odynophagia).
- O/E :
  - a. Earliest : Hyperaemia & edema of  
Posterior commissure → mammillated arytenoids.
  - b. Later : TVC → mouse nibbled appearance.
  - c. Last : Epiglottis → Turban epiglottis.
- mx : ATT.



Note : CA Larynx also presents with odynophagia.